


INTRODUCTION TO ECG INTERPRETATION V10.0 (2017-2018)

Frank G. Yanowitz, MD
Professor of Medicine
University of Utah School of Medicine
Medical Director, Intermountain Healthcare ECG Services
LDS Hospital & Intermountain Medical Center
Salt Lake City, Utah
frank.yanowitz@imail.org

Dedicated To:



INTRODUCTION

*This document is dedicated to the memory of **Alan E. Lindsay, MD (1923-1987)** master teacher of electrocardiography, friend, mentor, and colleague. Many of the excellent ECG tracings illustrated in this learning program are from Dr. Lindsay's personal collection of ECG treasures. For many years these ECG's have been used in the training of medical students, nurses, house staff physicians, cardiology fellows, and practicing physicians in Salt Lake City, Utah as well as at many regional and national medical meetings.*

© 2018 Intermountain Healthcare. All rights reserved.

The materials presented in the "Introduction to ECG Interpretation" Booklet are for your information only. All of the materials are provided "AS IS" and without any warranty, express, implied or otherwise, regarding the materials' accuracy or performance. You accept all risk of use of, and reliance on, the materials contained in the Booklet.

It is an honor to be able to provide this 'Outline' as well as an interactive ECG website on the Internet in recognition of Dr. Lindsay's great love for teaching and for electrocardiography: <http://ecg.utah.edu>. This document and the ECG website offer an introduction to clinical electrocardiography.

ECG terminology and diagnostic criteria often vary from book to book and from one teacher to another. In this document an attempt has been made to conform to standardized terminology and criteria, although new diagnostic concepts derived from the recent ECG literature have been included in some of the sections. Finally, it is important to recognize that ***the mastery of ECG interpretation, one of the most useful clinical tools in medicine, can only occur if one acquires considerable experience in reading ECG's and correlating the specific ECG findings with the pathophysiology and clinical status of the patient.***

The sections in this booklet are organized in the same order as the recommended step-wise approach to ECG interpretation outlined in **Section 2** (p7). Beginning students should first go through the sections in the order in which they are presented. Others may choose to explore topics of interest in any order they wish. It is hoped that all students will be left with some of the love of electrocardiography shared by Dr. Lindsay.

TABLE OF CONTENTS

1. The Standard 12 Lead ECG (p. 4)	7. Atrial Morphologies (p. 59)
2. A "Method" of ECG Interpretation (p. 7)	8. Ventricular Hypertrophy (p. 61)
3. Characteristics of the Normal ECG (p. 11)	9. Myocardial Infarction (p. 66)
4. ECG Measurement Abnormalities (p. 14)	10. ST Segment Abnormalities (p. 79)
5. ECG Rhythm Abnormalities (p. 17)	11. T Wave Abnormalities (p. 83)
6. ECG Conduction Abnormalities (p. 46)	12. U Wave Abnormalities (p. 89)

Electrocardiography Core Competencies

(Modified from: 2016 ACC Lifelong Learning Competencies for General Cardiologists, JACC 2016; 67:2656-95)

In 2001 a joint committee of the American College of Cardiology and the American Heart Association published a list of ECG diagnoses considered to be important for developing basic competency in ECG interpretation. This list (updated in **2016**) is provided on the following page and is also found on <http://ecg.utah.edu> with links to examples or illustrations of the specific ECG diagnosis. Students of electrocardiography are encouraged to study this list and become familiar with the ECG recognition of these diagnoses. Most of the diagnoses are illustrated in this document.

Core Competencies in Electrocardiography

NORMAL TRACING

- Normal ECG & normal variants

TECHNICAL PROBLEM

- Lead placement errors
- Artifact

SINUS RHYTHMS/ARRHYTHMIAS

- Sinus rhythm
- Sinus tachycardia
- Sinus bradycardia
- Sinus arrhythmia
- Sinus arrest or pause
- 2nd Degree Sinoatrial exit block

OTHER SV ARRHYTHMIAS

- PAC's (nonconducted)
- PAC's (conducted normally)
- PAC's (conducted with aberration)
- Ectopic atrial rhythm or tachycardia (unifocal)
- Multifocal atrial rhythm or tachycardia
- Atrial fibrillation
- Atrial flutter
- Junctional premature beats
- Junctional escapes or rhythms
- Accelerated Junctional rhythms
- Junctional tachycardia
- PSVT's: AVNRT and AVRT

VENTRICULAR ARRHYTHMIAS

- PVC's
- Ventricular escapes or rhythm
- Accelerated ventricular rhythm
- Ventricular tachycardia (uniform)
- Ventricular tachycardia (polymorphic or torsade)
- Ventricular fibrillation

AV CONDUCTION

- 1st degree AV block
- Type I 2nd degree AV block (Wenckebach)
- Type II 2nd degree AV block (Mobitz)
- AV block, advanced (high grade)
- 3rd degree AV block (junctional escape rhythm)
- 3rd degree AV block (ventricular escape rhythm)
- AV dissociation (default)
- AV dissociation (usurpation)
- AV dissociation (AV block)

INTRAVENTRICULAR CONDUCTION

- Complete LBBB, fixed or intermittent
- Incomplete LBBB
- Complete RBBB, fixed or intermittent
- Incomplete RBBB
- Left anterior fascicular block (LAFB)
- Left posterior fascicular block (LPFB)
- Nonspecific IV conduction delay (IVCD)
- WPW preexcitation patterns

QRS AXIS AND VOLTAGE

- Right axis deviation (+90 to +180)
- Left axis deviation (-30 to -90)
- Bizarre NW Quadrant axis (-90 to -180)
- Indeterminate axis (all small, isoelectric QRS)
- Low QRS voltage frontal plane (all QRS <0.5 mV)
- Low QRS voltage precordial (all QRS <1.0 mV)

HYPERTROPHY/ENLARGEMENTS

- Left, Right, and biatrial enlargement
- Left ventricular hypertrophy
- Right ventricular hypertrophy
- Biventricular hypertrophy

ST-T, AND U ABNORMALITIES

- Early repolarization (normal variant)
- Nonspecific ST-T abnormalities
- ST changes secondary to hypertrophy
- ST elevation (pericarditis pattern)
- Symmetrical T wave inversion
- Hyperacute T waves
- Prominent upright U waves
- U wave inversion
- Prolonged QT interval
- Brugada patterns

MI PATTERNS (acute, recent, old)

- ST-T changes due to ischemia
- Acute current of injury
- ST elevation MI
- Non-ST elevation MI
- Q-wave myocardial infarction
- Abnormal Q waves not due to MI
- Time course of ECG in MI
- ECG localization of MI

CLINICAL DISORDERS

- Chronic pulmonary disease pattern
- Hypokalemia
- Hyperkalemia
- Hypocalcemia
- Hypercalcemia
- ASD (primum and secundum)
- Dextrocardia
- Mitral stenosis
- Suggests CNS disease
- Hypothermia
- Drug effects (digoxin, tricyclics, etc.)

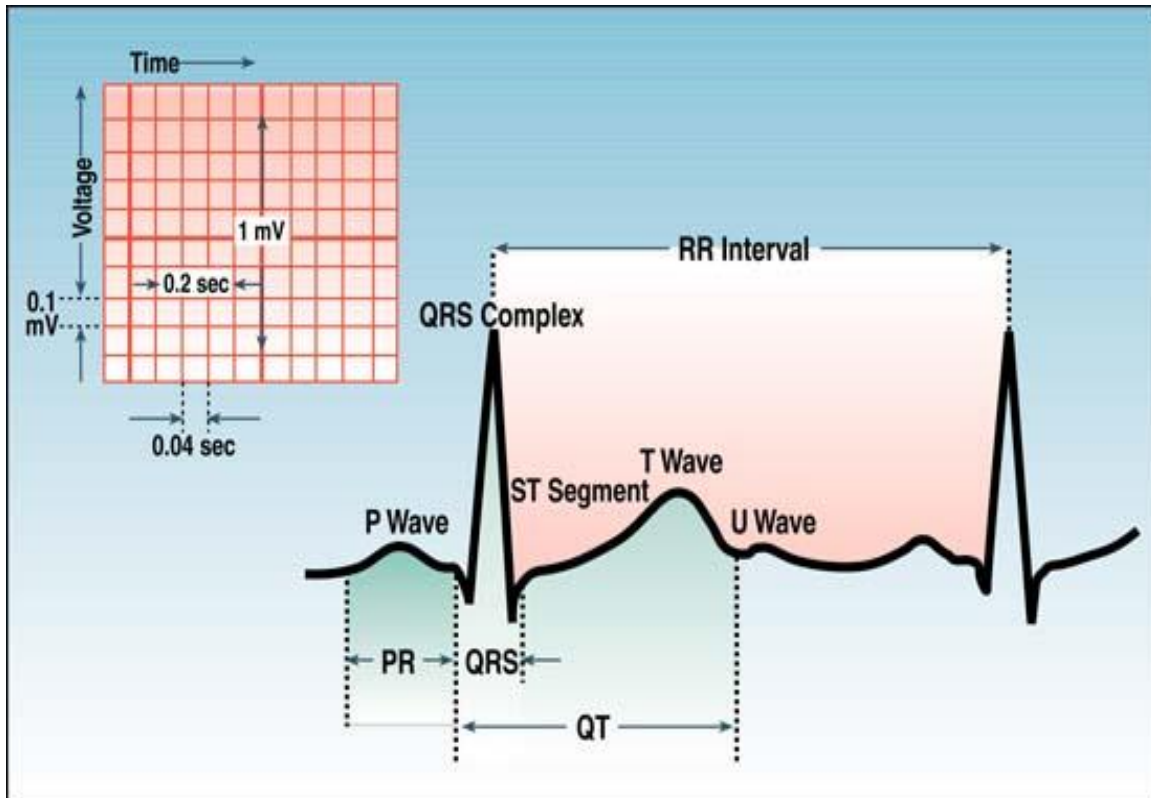
PACEMAKER ECG

- Atrial-paced rhythm
- Ventricular paced rhythm
- Atrial-triggered ventricular pacing
- AV sequential paced rhythm
- Biventricular pacing
- Failure to capture (atrial or ventricular)
- Failure to inhibit (atrial or ventricular)
- Failure to pace (atrial or ventricular)

1. THE STANDARD 12 LEAD ECG

The standard 12-lead electrocardiogram is a representation of the heart's electrical activity recorded from electrodes on the body surface. This section describes the basic components of the ECG and the standard lead system used to record the ECG tracings.

The diagram illustrates ECG waves and intervals as well as standard time and voltage measures on the ECG recordings.



ECG WAVES AND INTERVALS: What do they mean?

- **P wave:** *sequential* depolarization of the right and left atria
- **QRS complex:** right and left ventricular depolarization
- **ST-T wave:** ventricular repolarization
- **U wave:** small 'afterdepolarization' event at the beginning of diastole
- **PR interval:** time interval from onset of atrial depolarization (P wave) to onset of ventricular muscle depolarization (QRS complex)
- **QRS duration:** duration of ventricular muscle depolarization (width of the QRS complex)
- **QT interval:** duration of ventricular depolarization and repolarization
- **PP interval:** rate of atrial or sinus cycle
- **RR interval:** rate of ventricular cycle

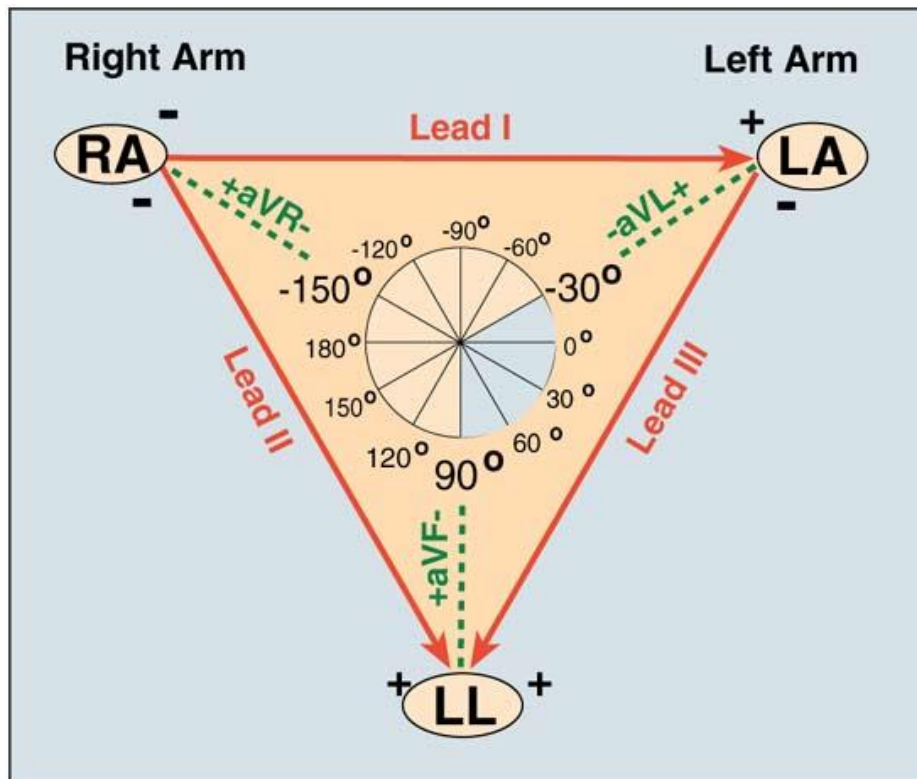
ORIENTATION OF THE 12-LEAD ECG (think in 3 dimension's):

It is important to remember that the 12-lead ECG provides spatial information about the heart's electrical activity in 3 *approximately* orthogonal directions (think: X, Y, Z):

- Right – Left (X)
- Superior – Inferior (Y)
- Anterior – Posterior (Z)

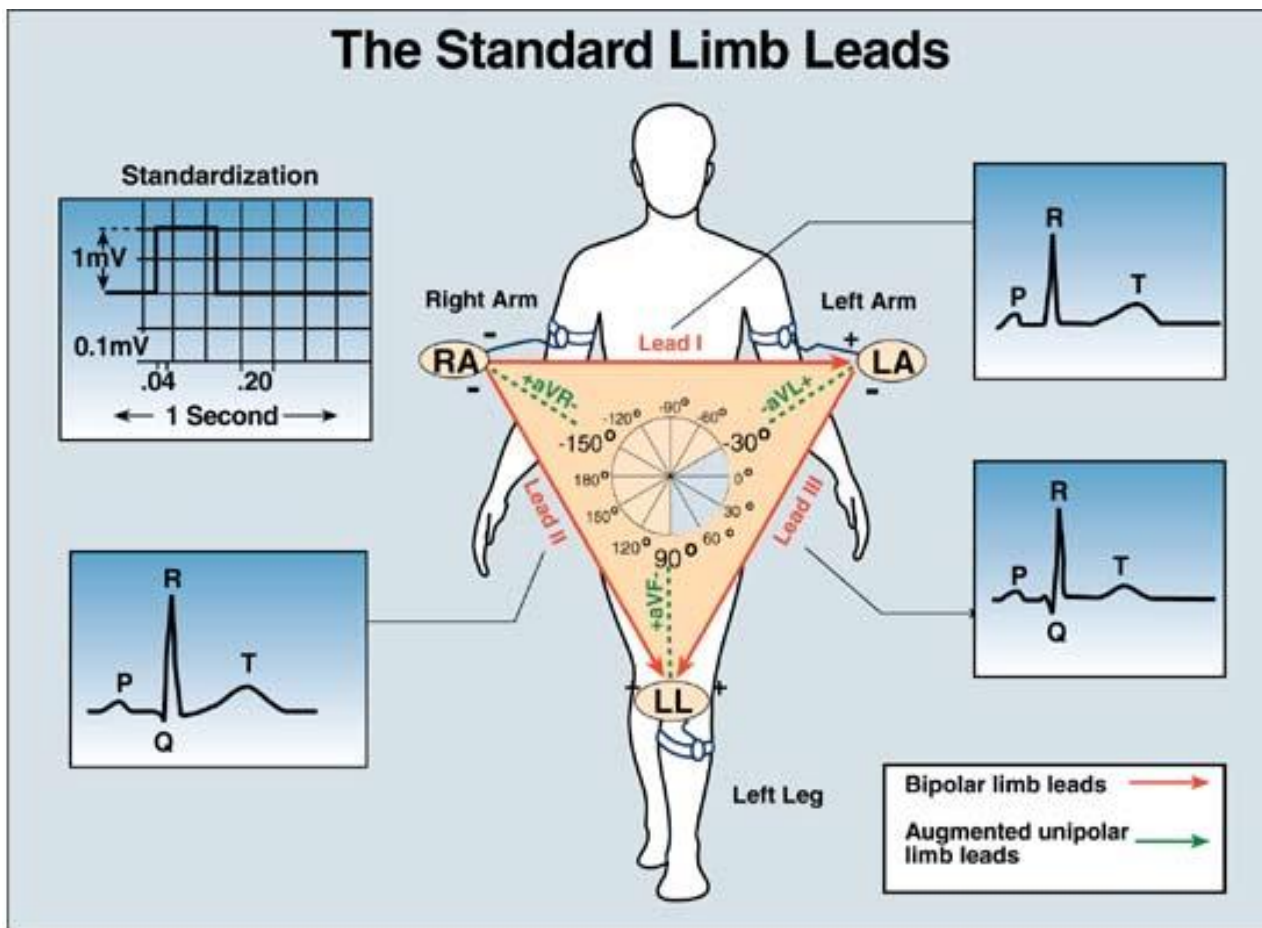
Each of the 12 leads represents a particular orientation in 3-D space, as indicated below.

- **Bipolar limb leads (frontal plane):**
 - Lead I: RA (- pole) to LA (+ pole) (Right -to- Left direction)
 - Lead II: RA (-) to LL (+) (mostly Superior -to- Inferior direction)
 - Lead III: LA (-) to LL (+) (mostly Superior -to- Inferior direction)
- **Augmented limb leads (frontal plane):**
 - Lead aVR: RA (+) to [LA & LL] (-) (mostly Rightward direction)
 - Lead aVL: LA (+) to [RA & LL] (-) (mostly Leftward direction)
 - Lead aVF: LL (+) to [RA & LA] (-) (Inferior direction)
- **"Unipolar" (+) chest leads (horizontal plane):**
 - Leads V1, V2, V3: (mostly Posterior -to- Anterior direction)
 - Leads V4, V5, V6: (mostly Right -to- Left direction)

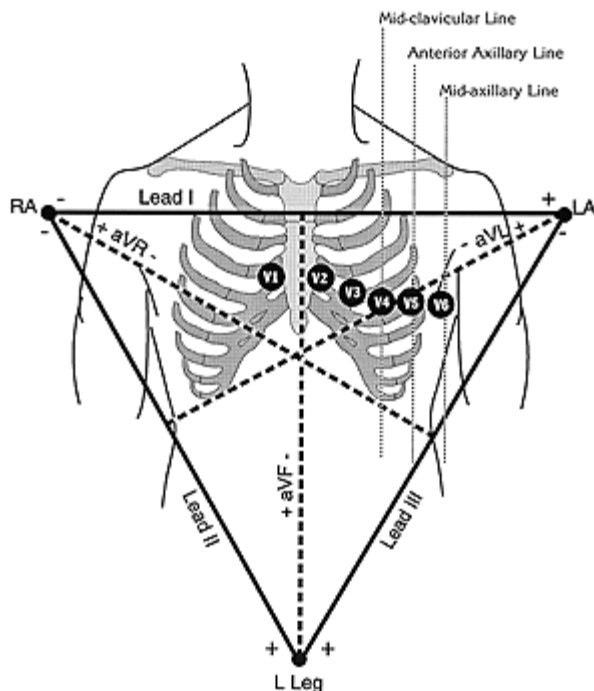


Behold: **Einthoven's Triangle!** Each of the 6 frontal plane or "limb" leads has a negative and positive pole (as indicated by the '+' and '-' signs). It is important to recognize that lead I (and to a lesser extent aVL) are right -to- left in direction. Also, lead aVF (and to a lesser extent leads II and III) are superior -to- inferior in direction. The diagrams on the next page further illustrate the frontal plane and chest lead hookup.

The Standard Limb Leads



Note: the actual ECG waveform in each of the 6 limb leads varies from person to person depending on age, body size, gender, frontal plane QRS axis, presence or absence of heart disease, and many other variables. The precordial lead sites are illustrated below.



Precordial lead placement

V1: 4th intercostal space (IS) adjacent to right sternal border

V2: 4th IS adjacent to left sternal border

V3: Halfway between V2 and V4

V4: 5th IS, midclavicular line

V5: horizontal to V4; anterior axillary line

V6: horizontal to V4-5; midaxillary line

(Note: in women with large breasts, V4-6 leads should be placed ***under the breast surface*** as close to the 5th IS as possible)

2. A "METHOD" OF ECG INTERPRETATION

This "method" is recommended when reading 12-lead ECG's. Like the approach to a physical exam, it is important to follow a standardized sequence of steps in order to avoid missing subtle abnormalities in the ECG tracing, some of which may have clinical importance. The 6 major sections in the "method" should be considered in the following order:

1. **Measurements**
 2. **Rhythm Analysis**
 3. **Conduction Analysis**
 4. **Waveform description**
 5. **Final Interpretation**
 6. **Comparison (if available) to previous ECG**
-

1. MEASUREMENTS (usually made in the frontal plane leads):

- Heart rate (state both atrial and ventricular rates, if different)
- PR interval (from beginning of P to beginning of QRS complex)
- QRS duration (width of most representative QRS)
- QT interval (from beginning of QRS to end of T)
- QRS axis in frontal plane (*see* "How to Measure QRS Axis" on p 8)

2. RHYTHM ANALYSIS:

- State the basic rhythm (e.g., "normal sinus rhythm", "atrial fibrillation", etc.)
- Identify additional rhythm events if present (e.g., "PVC's", "PAC's", etc.)
- Remember that arrhythmias may originate in the atria, AV junction, and ventricles

3. CONDUCTION ANALYSIS:

- "Normal" conduction implies normal sino-atrial (SA), atrio-ventricular (AV), and intraventricular (IV) conduction.
- The following conduction abnormalities are to be identified if present:
 - 2nd degree **SA 'exit' block** (type I, type II, or uncertain)
 - 1st, 2nd (type I or type II), and 3rd degree **AV block**
 - IV blocks: **bundle branch, fascicular**, and nonspecific blocks
 - Exit blocks are blocks just distal to the sinus or ectopic pacemaker site

4. WAVEFORM DESCRIPTION:

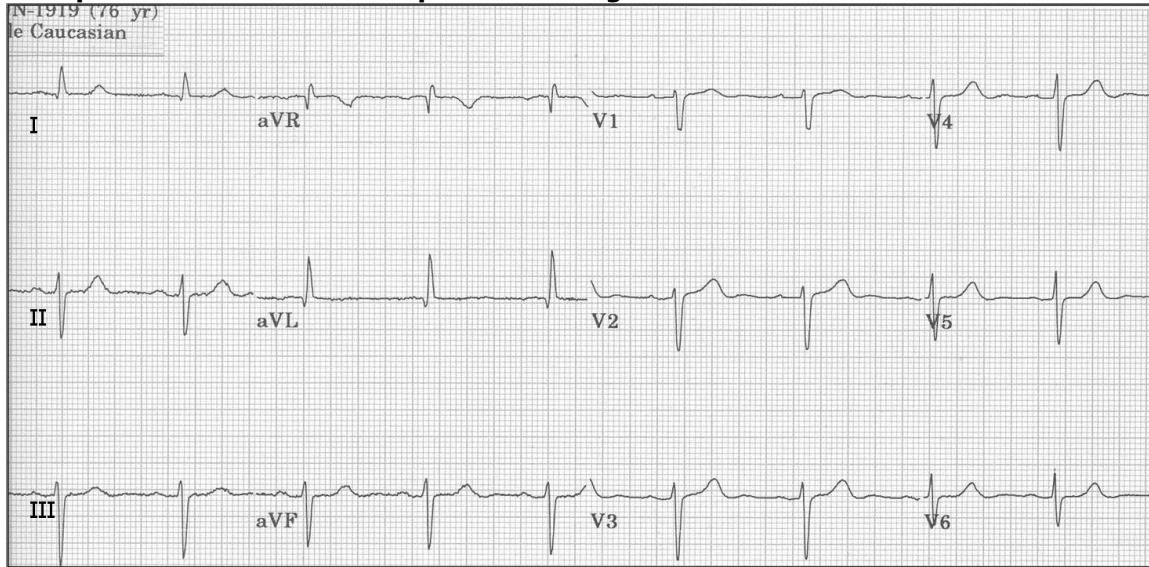
- Carefully analyze each of the 12-leads for abnormalities of the waveforms in the order in which they appear: P-waves, QRS complexes, ST segments, T waves, and.... Don't forget the U waves.
 - P waves: are they too wide, too tall, look funny (i.e., are they ectopic), etc.?
 - QRS complexes: look for pathologic Q waves, abnormal voltage, etc.
 - ST segments: look for leads with abnormal ST elevation and/or depression.
 - T waves: look for abnormally inverted T waves or unusually tall T waves.
 - U waves: look for prominent or inverted U waves.

5. FINAL ECG INTERPRETATION:

- This is the conclusion of the above analyses. Interpret the ECG as "**Normal**", or "**Abnormal**". Occasionally the term "**borderline**" is used if unsure about the significance of certain findings or for minor changes. List all abnormalities. Examples of "abnormal" statements are:
 - Inferior MI, probably acute
 - Old anteroseptal MI

- Left anterior fascicular block (LAFB)
- Left ventricular hypertrophy (LVH)
- Right atrial enlargement (RAE)
- Nonspecific ST-T wave abnormalities
- Specific rhythm abnormalities such as atrial fibrillation

Example of a 12-lead ECG interpretation using the "Method":



Measurements:	Rhythm (s):	Conduction:	Waveform:	Interpretation:
A= 67 V=67	Normal sinus rhythm	Normal SA, AV, and IV conduction	rS in II, III, aVF; S _{III} > S _{II} ; Small q in I, aVL; Poor R progression V ₁₋₄	Abnormal ECG: Left Anterior Fascicular Block
PR=180 ms				
QRS=90 ms				
QT=400 ms				
Axis= -50°				

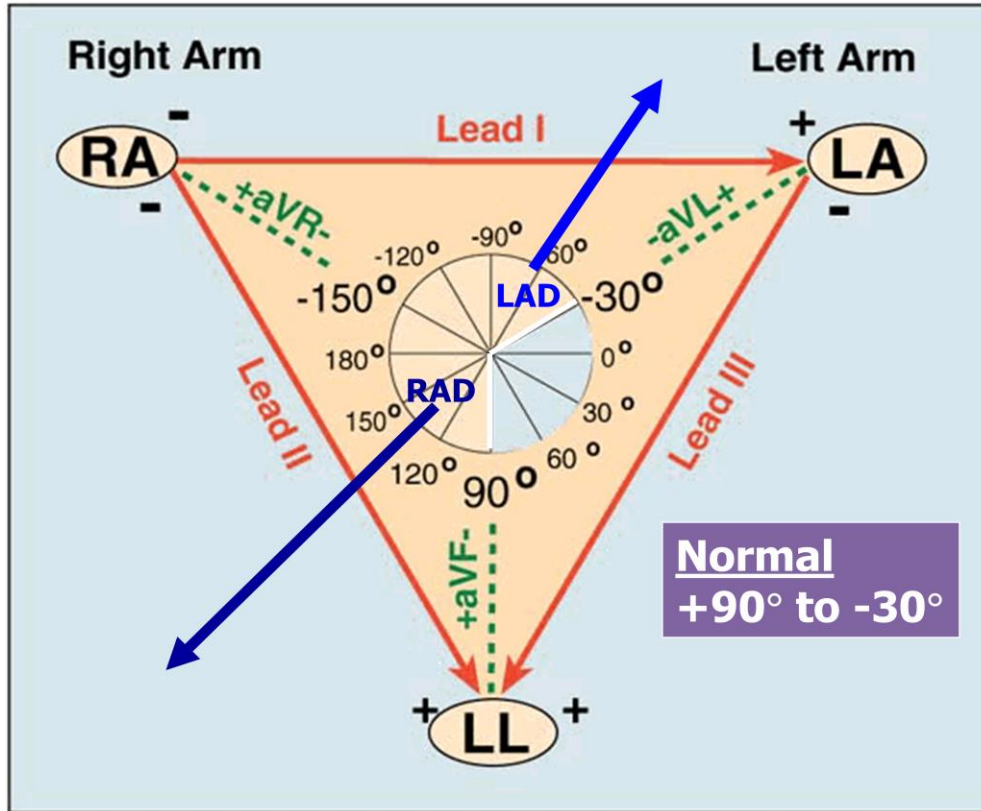
6. COMPARISON WITH PREVIOUS ECG:

- If there is a previous ECG in the patient's file, the current ECG should be compared with it to see if any significant changes have occurred. These changes may have important implications for clinical management decisions.

How to Measure the Frontal Plane QRS AXIS:

INTRODUCTION: The frontal plane QRS axis represents the average direction of all ventricular depolarization forces in the frontal plane leads. As such this measure can inform the ECG reader of changes in the sequence of ventricular activation (e.g., left anterior fascicular block), or it can be an indicator of myocardial damage (e.g., inferior myocardial infarction). Determination of the QRS axis requires an understanding of the direction of the 6 individual frontal plain ECG leads using the perspective of Einthoven's equilateral triangle.

In the next diagram the normal range is shaded grey (-30° to +90°). In the adult left axis deviation (see: superior, leftward blue arrow) is defined from -30° to -90°, and right axis deviation (see: inferior, rightward blue arrow) is defined from +90° to +180°. From -90° to ±180° is very unusual and is often due to lead placement error.



QRS Axis Determination:

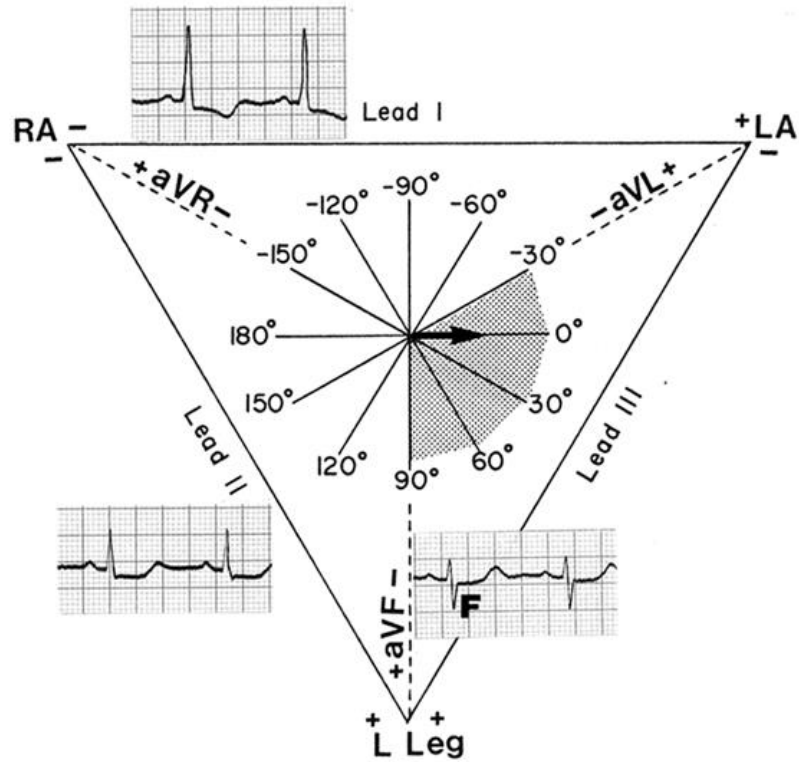
- First look for an **isoelectric** lead if there is one; it's the lead with equal QRS forces in both positive and negative direction (i.e., above and below the baseline). This is often the lead with the **smallest** QRS complex.
- The correct QRS axis is **perpendicular** (i.e., right angle or 90 degrees) to that lead's orientation (see above diagram).
- Since there are two possible perpendiculars for each isoelectric lead, one must chose the one that best fits the direction of the QRS forces in other ECG leads.

Isoelectric Lead	More likely axis	Less likely axis
I	+90	-90
II	-30	+150
III	+30	-150
aVR	-60	+120
aVL	+60	-120
aVF	0	+/-180

- If there is no isoelectric lead, there are usually **two** leads that are nearly isoelectric, and these are always 30° apart on the diagram. Find the perpendiculars for each lead and chose an approximate QRS axis within the 30° range.
- Occasionally each QRS in the 6 frontal plane leads is small and/or isoelectric. An axis cannot be determined and is called **indeterminate**. This is a normal variant.

Examples of QRS Axis Determination:

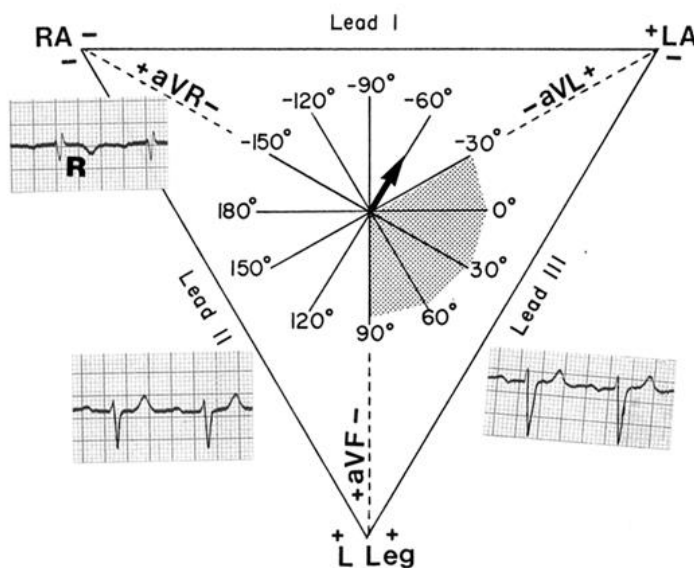
- An axis in the normal range (-30° to $+90^{\circ}$):



Analysis (see above)

1. Lead aVF is the isoelectric lead (note: equal forces positive and negative).
2. The two perpendiculars to aVF are 0° and $\pm 180^{\circ}$.
3. Note that Lead I is all positive (i.e., moving leftward).
4. Therefore, of the two choices, the axis has to be 0° .

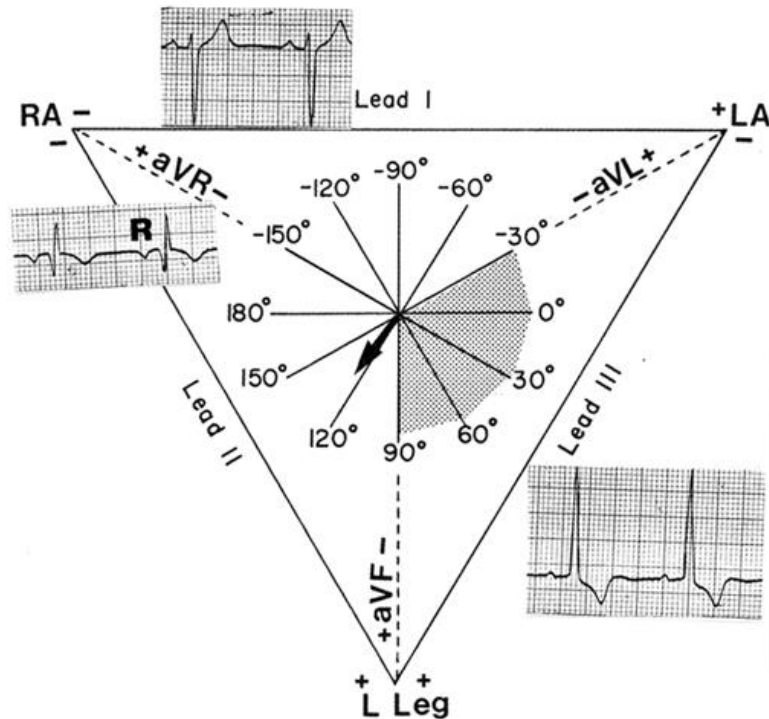
- Left Axis deviation (LAD):



Analysis

1. Lead aVR is the smallest and nearly isoelectric.
2. The two perpendiculars to aVR are -60° and $+120^\circ$.
3. Note that Leads II and III are mostly negative (i.e., moving away from the + left leg)
4. The axis, therefore, has to be -60° (LAD).
5. The differential diagnosis of LAD is listed on p16.

- **Right Axis Deviation (RAD):**



Analysis

1. Lead aVR is closest to being isoelectric (but slightly more positive than negative)
2. The two perpendiculars to aVR are -60° and $+120^\circ$.
3. Note that Lead I is mostly negative; lead III is mostly positive.
4. Therefore the axis is close to $+120^\circ$. Because aVR is slightly more positive, the axis is slightly beyond $+120^\circ$ (i.e., closer to the positive right arm for aVR, $\sim +125^\circ$)
5. The differential diagnosis of RAD is listed on p16.

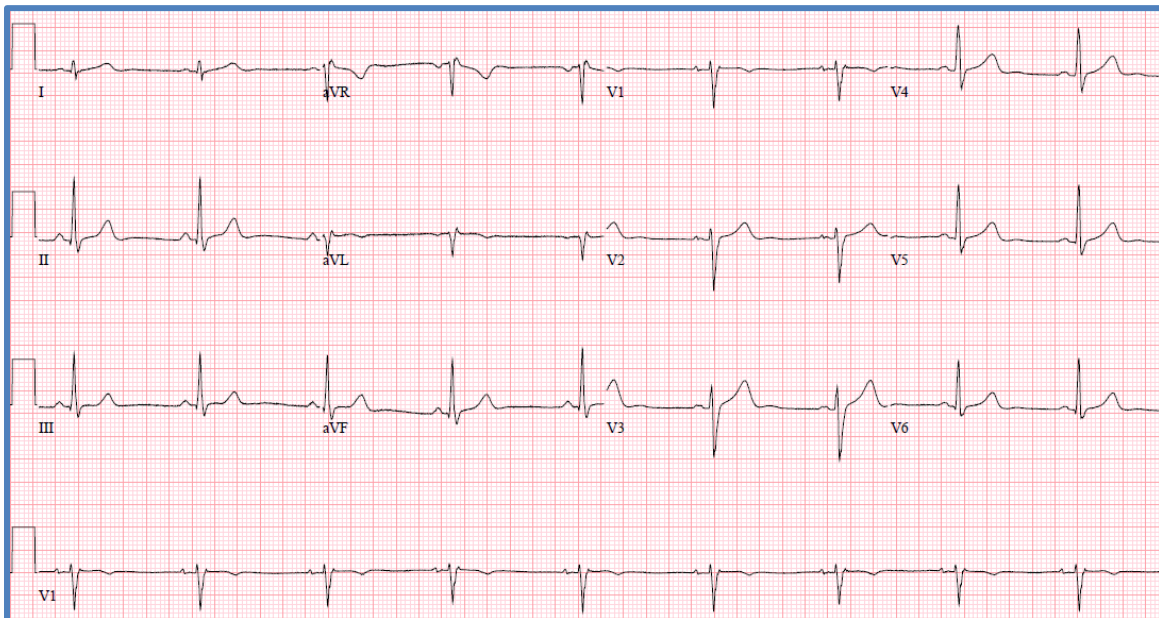
- **Indeterminate QRS Axis:**

In some normal subjects each of the 6 frontal plane leads have QRS forces above and below the baseline and all 6 look somewhat isoelectric; this is called an *indeterminate* QRS axis, and if the rest of the ECG looks normal, this is a normal variant.

3. CHARACTERISTICS OF THE 'NORMAL' ECG

It is important to remember that there is a wide range of normal variation in the 12 lead ECG. The following "normal" ECG characteristics, therefore, are not absolute. It takes considerable ECG reading experience to discover all the

normal variants. Only by following a structured ***"Method of ECG Interpretation"*** (p7) and correlating the various ECG findings with the patient's particular clinical status will the ECG become a valuable clinical tool. The normal 12-lead ECG illustrated below is an example of the usual 4-channel continuous 10 second recording including the V1 rhythm strip. The 5-step interpretation 'Method' is also shown under the ECG.



Measurements:	Rhythm (s):	Conduction:	Waveform:	Interpretation:
A=55 V=55	Normal Sinus Rhythm	Normal SA, AV, and IV conduction	Normal P, QRS, ST, and U	Normal ECG
PR=140				
QRS=106				
QT=440 uncorrected				
Axis= +80°				

I. Normal MEASUREMENTS (in adults)

- **Heart Rate: 50 - 90 bpm (some ECG readers use 60-100 bpm)**
- **PR Interval: 120 – 200 ms**
- **QRS Duration: 60 – 109 ms**
- **QT Interval (QT_c >360 ms, and <430 ms in men; >360 ms, <450 ms in women)**
 - ***Poor Man's Guide*** to the upper limit of 'raw' QT: @ 70 bpm, QT ≤ 400 ms; for every 10 bpm increase above 70 bpm subtract 20 ms, and for every 10 bpm decrease below 70 bpm add 20 ms. For example, normal QT is:
 - QT ≤ 380 ms @ 80 bpm
 - QT ≤ 420 ms @ 60 bpm
- **Frontal Plane QRS Axis: +90° to -30° (in the adult)**

II. Normal RHYTHM: Normal sinus rhythm (NSR)

III. Normal CONDUCTION: Normal Sino-Atrial (SA), Atrio-Ventricular (AV), and Intraventricular (IV) conduction

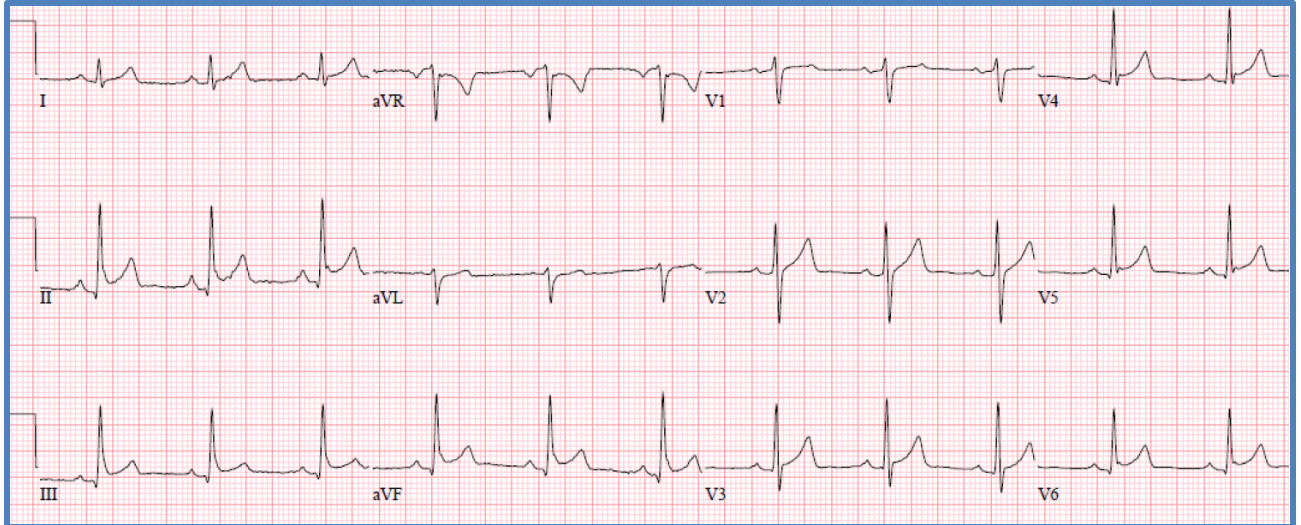
IV. Normal WAVEFORM DESCRIPTION:

P Wave: It is important to remember that the P wave represents the *sequential* activation of the right and left atria, and it is common to see notched (lead II) or biphasic P waves (Lead V1) of right and left atrial activation.

- P duration < 120 ms
- P amplitude < 2.5 mm
- Frontal plane P wave axis: 0° to +75° (i.e., P must be up-going in I and II)
- May see notched P waves in frontal plane, and biphasic P (+/-) in V1

QRS Complex: The normal QRS represents the *almost simultaneous* activation of the right and left ventricles, although most of the QRS waveform is derived from the larger left ventricular musculature.

- QRS duration: < 110 ms
- QRS amplitude is quite variable from lead to lead and from person to person. Two determinates of QRS voltages are:
 - Size of the ventricular chambers (i.e., the larger the chamber, the larger the voltage; often seen in young aerobic trained athletes)
 - Proximity of chest electrodes to ventricular chamber (the closer to the heart, the larger the voltage; seen in tall, thin people)
- Frontal plane leads:
 - The normal QRS axis range (+90° to -30°) implies that the QRS direction **must always be positive** (up-going) in leads I and II.
 - Small "septal" q-waves are often seen in leads I and aVL when the QRS axis is to the **left** of +60°, or in leads II, III, aVF when the QRS axis is to the **right** of +60° (early activation of the LV septum)
- Precordial leads:
 - Small r-waves begin in V1 **or** V2 and increase in size up to V5. The R-V6 is usually a little smaller than R-V5.
 - In reverse, small s-waves begin in V6 **or** V5 and increase in size up to V2. S-V1 is usually smaller than S-V2.
 - The usual transition from **S>R** in the right precordial leads to **R>S** in the left precordial leads is V3 or V4.
 - Small normal "septal" q-waves may be seen in leads V5 and V6.
- **ST Segment:** In a sense, the term "ST segment" is a misnomer, because a discrete ST segment distinct from the T wave is often not seen. More frequently the 'ST-and-T' is one smooth, continuous waveform beginning at the J-point (end of QRS), slowly rising to the peak of the T and followed by a more rapid descent to the isoelectric baseline or the onset of the U wave. This gives rise to asymmetrical T waves in most leads (see below). The ST segment occurs during Phase 2 (the plateau) of the myocardial cell action potentials. In some normal individuals, particularly women, T waves can be more symmetrical with a distinct horizontal ST segment.
- The ST segment is often elevated above baseline in leads with large S waves (e.g., V2-3), and the normal configuration is **concave upward**. ST segment elevation with concave upward appearance may also be seen in other leads; this is called the **early repolarization pattern**, and is often seen in young, male athletes (see next ECG for an example of "early repolarization" in leads V4-6 and the inferior leads). J-point elevation is often accompanied by a small J-wave in the lateral precordial leads. The physiologic basis for the J-wave is related to transient outward K⁺ current during phase I of the epicardial and mid-myocardial cells, but not present in the subendocardial cells. Prominent J waves can also be seen in hypothermia (aka: Osborn waves, see example on p81)



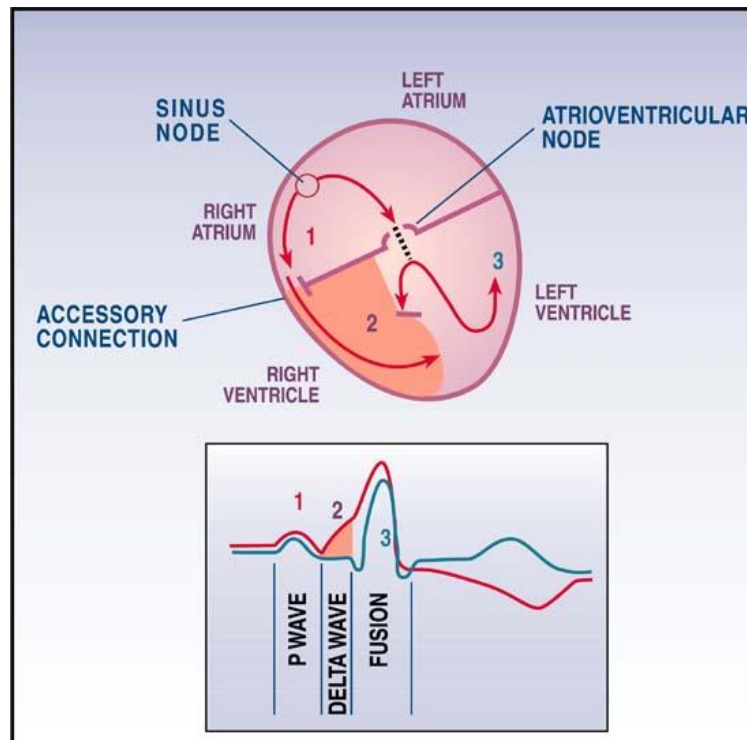
Early Repolarization in a 62 year old (not so young) asymptomatic man

4. ABNORMALITIES IN THE ECG MEASUREMENTS

Since the 5-Step "Method" begins with 'measurements', let's begin looking at each of the five measurements and consider normal and abnormal values along with some differential diagnoses for each abnormality.

1. PR Interval (measured from beginning of P to beginning of QRS in the frontal plane)

- **Normal: 120-200 ms**
- **Differential Diagnosis of Short PR: <120 ms**
 - **Preexcitation syndromes:**
 - WPW (Wolff-Parkinson-White) Syndrome: An accessory pathway (called the "Kent" bundle) connects atrial muscle to ventricular muscle (see diagram below), and this permits early but slow activation of the ventricles (a *delta* wave) with a short PR interval
 - (see diagram below for example). (see: more WPW on **P58**)



- LGL (Lown-Ganong-Levine) Syndrome: An AV nodal bypass track into the His bundle exists, and this permits early activation of the ventricles without a *delta-wave* because the ventricular activation sequence is unchanged; the PR interval, however, is short.
- The clinical 'syndromes' in WPW and LGL include episodes of supraventricular tachycardias using these accessory pathways.
- **AV Junctional Rhythms with retrograde atrial activation (inverted P waves in II, III, aVF):** Retrograde P waves may occur *before* the QRS complex (usually with shorter PR interval), *within* the QRS complex (i.e., hidden from view), or *after* the QRS complex (i.e., in the ST segment). It all depends upon the relative timing from the junctional pacemaker forward (antegrade) into the ventricles vs. backwards (retrograde) to the atria.
- **Ectopic atrial rhythms originating near the AV node** (the PR interval is short because atrial activation originates closer to the AV node; the P wave morphology is different from the sinus P and may appear inverted in some leads); they are sometimes called "**coronary sinus rhythms**".
- **Normal variant (PR 100 – 120 ms): seen in children and adolescents**
- **Differential Diagnosis of Prolonged PR: >200 ms**
 - **First degree AV block (PR interval is usually constant from beat to beat); possible locations for the conduction delay include:**
 - Intra-atrial or inter-atrial conduction delay (uncommon)
 - Slowed conduction within the AV node (most common site of prolonged PR, often resulting from vagal stimulation)
 - Slowed conduction in His bundle (uncommon)
 - Slowed conduction in one bundle branch (when the contralateral bundle is totally blocked; i.e., 1st degree bundle branch block)
 - **Second degree AV block (some P waves do not conduct to ventricles and are not followed by a QRS; other PR intervals may be normal or prolonged)**
 - Type I (aka: Wenckebach): Increasing PR until a nonconducted P wave occurs (usually due to AV nodal slowing)
 - Type II (Mobitz): Fixed and usually normal PR intervals plus nonconducted P waves (His bundle and bundle branches)
 - **AV dissociation:** Some PR's may appear prolonged or normal, but the P waves and QRS complexes are unrelated (i.e., they are dissociated, more like strangers passing in the night).

2. QRS Duration (duration of QRS complex in frontal plane):

- **Normal: 60 – 109 ms**
- **Differential Diagnosis of Prolonged QRS Duration (≥110 ms):**
 - **QRS duration 110 – 119 ms**
 - Incomplete right or left bundle branch block
 - Nonspecific intraventricular conduction delay (IVCD)
 - Some cases of left anterior or left posterior fascicular block
 - **QRS duration ≥ 120 ms**
 - Complete RBBB or LBBB (usually >140 ms)
 - Nonspecific IVCD (i.e., generalized slowing of conduction)
 - Ectopic rhythms originating in the ventricles (e.g., PVCs, ventricular rhythms, artificial pacemaker rhythms)

3. QT Interval (measured from beginning of QRS to end of T wave in the frontal plane; corrected QT (QT_c) = measured QT ÷ sq-root RR in seconds (Bazet's formula)

- **Normal QT_c:** ≤430 ms (men), ≤450 ms (women)
- **Borderline Long QT_c:** 431-450 ms (men), 451-470 ms (women)
- **Long QT_c:** >450 ms (men), >470 ms (women)
 - QT prolongation may have important clinical implications since it usually indicates a state of increased vulnerability to malignant ventricular arrhythmias, syncope, and sudden death. The prototype arrhythmia of the *Long QT Interval Syndromes (LQTS)* is **Torsade-de-pointes**, a polymorphic ventricular tachycardia characterized by varying QRS morphology and amplitude around the isoelectric baseline. Causes of QT prolongation include the following:
 - Drugs (Class I and III antiarrhythmics, tricyclics, phenothiazines, and many others)
 - Electrolyte abnormalities (↓ K⁺, ↓ Ca⁺⁺, ↓ Mg⁺⁺)
 - CNS insults (especially subarachnoid hemorrhage, stroke, head trauma)
 - Hereditary LQTS (at least 7 genotypes are now known)
 - Coronary Heart Disease (some post-MI patients)
 - Cardiomyopathy
- **Short QT Syndrome (QT_c <360 ms; range 220-360 ms):** Newly described hereditary disorder with increased risk of sudden arrhythmic death. The QT_c criteria are vague as many people with QT_c <360 ms are not at risk.

4. Frontal Plane QRS Axis

- **Normal: -30 degrees to +90 degrees**
- **Abnormalities in the QRS Axis:**
 - **Left Axis Deviation (LAD): > -30°(i.e., lead II is mostly 'negative')**
 - Left Anterior Fascicular Block (LAFB): rS complex (i.e., small r, big S) in leads II, III, aVF, small q in leads I and/or aVL, and -45 to -90° (see ECG on p 8); in LAFB, the S in lead III is > S in lead II, and the R in aVL is > R in aVR. This differentiates LAFB from other causes of LAD with rS complexes in II, III, aVF (e.g., COPD)
 - Some cases of inferior MI with Qr complex in lead II (making lead II 'negative')
 - Inferior MI + LAFB in same patient (QS or qrS complex in II)
 - Some cases of LVH
 - Some cases of LBBB
 - Ostium primum ASD and other endocardial cushion defects
 - Some cases of WPW syndrome (large negative *delta* wave in lead II)
 - **Right Axis Deviation (RAD): > +90° (i.e., lead I is mostly 'negative')**
 - Left Posterior Fascicular Block (LPFB): rS complex in lead I, qR in leads II, III, aVF (*however, must first exclude, on clinical basis, isolated right heart disease (e.g., cor pulmonale); this will also give an false ECG picture of LPFB*)
 - Many causes of right heart overload and pulmonary hypertension
 - High lateral wall MI with Qr or QS complex in leads I and aVL
 - Some cases of RBBB
 - Some cases of WPW syndrome
 - Children, teenagers, and some young adults
 - **Bizarre QRS axis: +150° to -90° (i.e., lead I and lead II are both negative)**

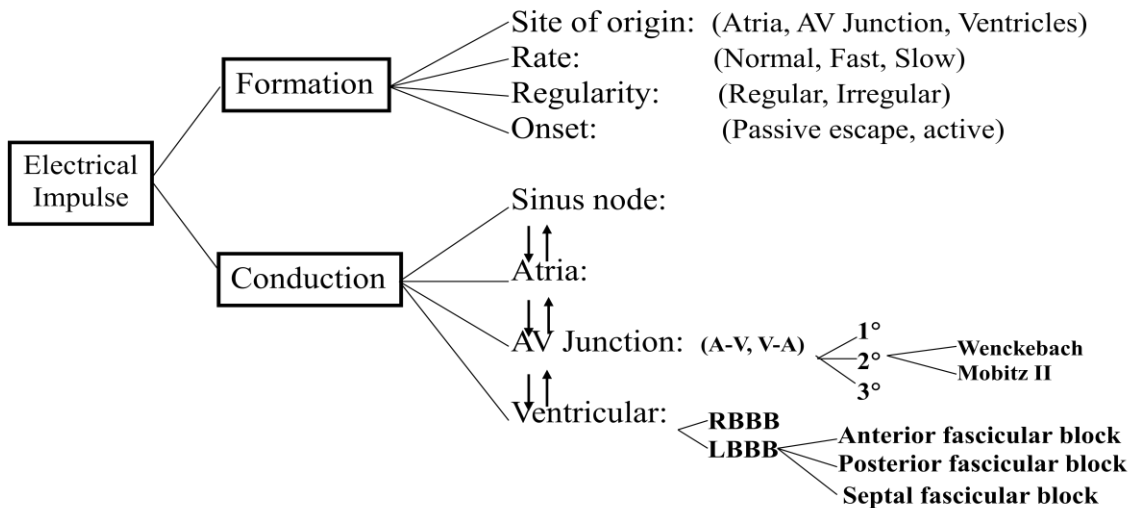
- First, consider a limb lead error (usually right and left arm reversal)
- Dextrocardia
- Some cases of complex congenital heart disease (e.g., transposition)
- Some cases of ventricular tachycardia
- Unusual myocardial infarction location

5. ECG RHYTHM ABNORMALITIES

THINGS TO CONSIDER WHEN ANALYZING ARRHYTHMIAS:

Arrhythmias may be seen on 12-lead ECGs or on rhythm strips of one or more leads. Some arrhythmias are obvious at first glance and don't require intense analysis. Others, however, are more challenging (and often more fun)! They require detective work, i.e., logical thinking. Rhythm analysis is best understood by considering characteristics of **impulse formation** (if known) as well as **impulse conduction**. Here are some things to consider as originally conceptualized by my friend, Dr. Alan Lindsay:

How To Think About Arrhythmias And Conduction Disturbances



- Descriptors of **impulse formation** (i.e., the pacemaker or site of impulse formation)
 - **Site of origin** - i.e., where does the rhythm originate?
 - Sinus Node (e.g., sinus tachycardia; sinus P waves may be hidden in the preceding T waves at very fast rates)
 - Atria (e.g., PACs, ectopic atrial rhythms, etc.)
 - AV junction (e.g., PJs and junctional rhythms)
 - Ventricles (e.g., PVCs, ventricular rhythms)
 - **Rate** (i.e., relative to the expected rate for that pacemaker location)
 - Accelerated - faster than expected for that pacemaker site (e.g., accelerated junctional rhythms @ HR's 60-100 bpm)
 - Slower than expected (e.g., marked sinus bradycardia, 38 bpm)
 - Normal (or expected) (e.g., junctional escape rhythm, 45 bpm)
 - **Regularity** of ventricular and/or atrial response
 - Regular (e.g., paroxysmal supraventricular tachycardia - PSVT)
 - Regular-irregularity (e.g., ventricular bigeminy)

- Irregular-irregularity (e.g., atrial fibrillation or MAT)
- Irregular (e.g., multifocal PVCs)
- **Onset** (i.e., how does arrhythmia begin?)
 - Active onset (e.g., PAC or PVC, PSVT)
 - Passive onset (e.g., junctional or ventricular escape beats or rhythms)
- Descriptors of **impulse conduction** (i.e., how does the rhythm move through the heart chambers?)
 - **Antegrade** (forward) vs. **retrograde** (backward) conduction
 - Conduction delays or blocks: i.e., 1st, 2nd (type I or II), 3rd degree blocks
 - Sites of potential conduction delay
 - Sino-Atrial (SA) block (one can only recognize 2nd degree SA block on the ECG; i.e., an unexpected failure of a sinus P-wave to appear, resulting in a pause in rhythm)
 - Intra-atrial or inter-atrial delay (usually recognized as a widened P wave)
 - AV conduction delays (common)
 - IV blocks (e.g., bundle branch or fascicular blocks)

The Many Rhythms In Our Lives

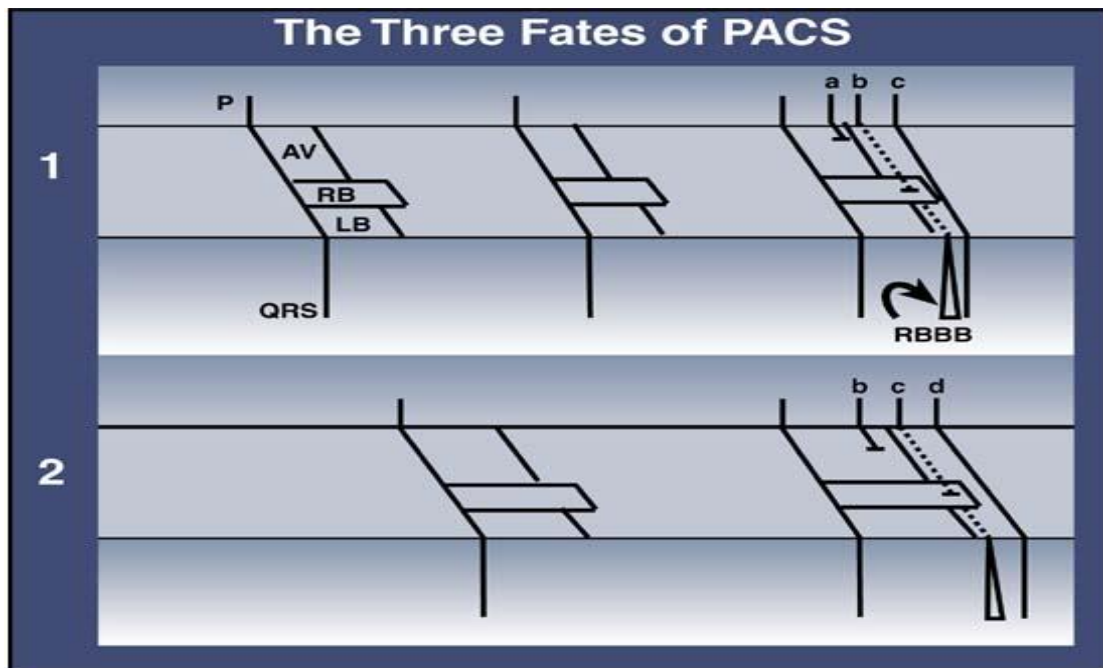
Site of Origin	Single Events	Slow Rates (<50 bpm)	Intermediate Rates (50-99 bpm)	Fast Rates (≥100 bpm)
Sinus		Sinus bradycardia	Normal sinus rhythm	Sinus tachycardia
Atria	PAC's	Ectopic atrial bradycardia (unusual)	Ectopic atrial rhythm, Atrial fibrillation, Atrial flutter (e.g., 4:1 block)	Paroxysmal SVT, Atrial fibrillation, Atrial flutter (2:1 block), Ectopic atrial tachycardia, Multifocal atrial tachycardia (MAT)
AV Junction (AVN, His)	PJC's J- escape beats	J- escape rhythm (~40-55 bpm)	Accelerated J- rhythm (~55-99 bpm)	Junctional tachycardia, Paroxysmal SVT: AVNRT, AVRT (WPW)
Ventricles (Wide QRS)	PVC's V-escape beats	V- escape rhythm (~35-50 bpm) aka: 'Idioventricular Rhythm'	Accelerated V- rhythm (~50-99 bpm)	Ventricular tachycardia, Torsade de points, Ventricular fibrillation

Now let's continue with some real rhythms.....

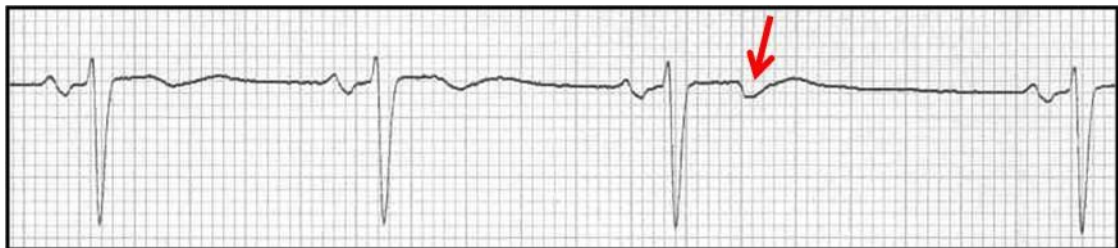I. Supraventricular Arrhythmias (origin is above the bifurcation of HIS bundle)

- **Premature Atrial Complexes (PAC's)**

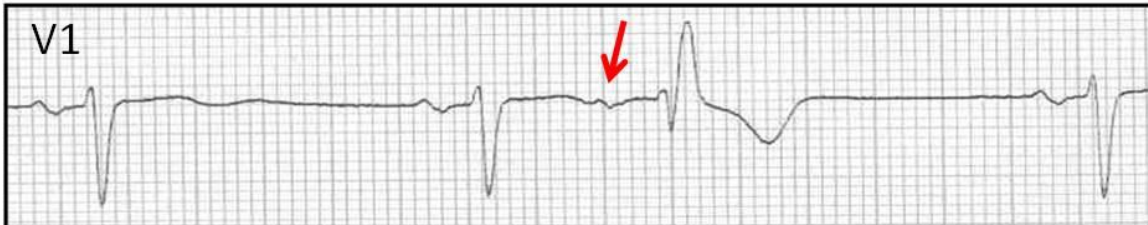- Occur as single or repetitive events and have unifocal or multifocal origins.
- The ectopic P wave (often called P') is often hidden in the ST-T wave of the preceding beat. (Dr. Henry Marriott, master ECG teacher and author, likes to say: "**Cherchez le P**" which, in French, means: "Search for a P' (on the ST or T wave), and it's clearly sexier to search in French!")
- The P'R interval can be normal or prolonged if the AV junction is partially refractory at the time the premature atrial impulse enters it.
- PAC's can have one of **three different outcomes** depending on the degree of prematurity (i.e., coupling interval from preceding sinus P wave), and the preceding cycle length (i.e., the preceding RR interval). This is illustrated in the "ladder" diagrams where normal sinus beats (P) are followed by three possible PACs (labeled a,b,c,d in the diagram below):



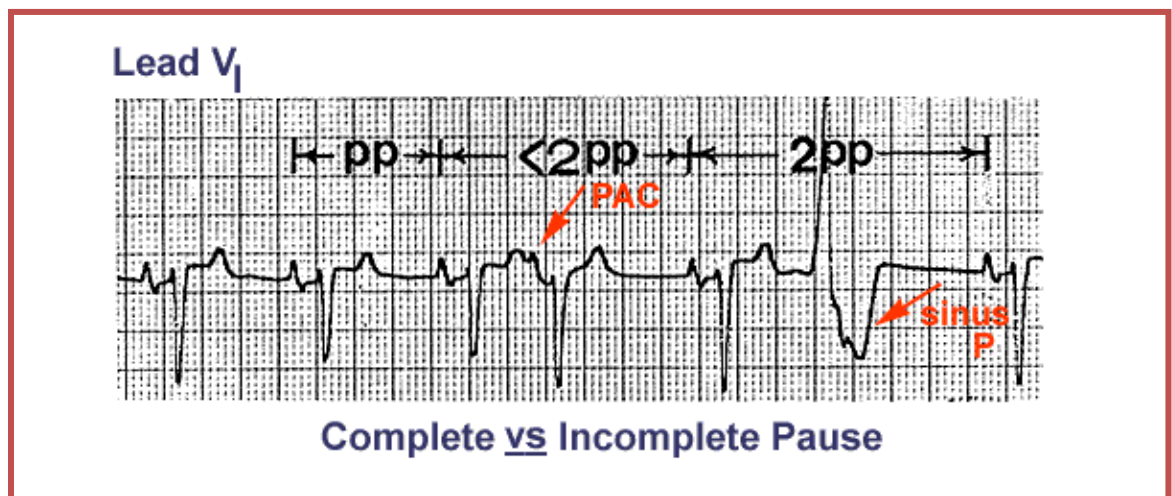
- Outcome #1. **Nonconducted** (or blocked) PAC; i.e., no QRS complex because the early PAC finds the AV node still refractory to conduction. (See PAC 'a' in the diagram above, and the nonconducted PAC in ECG shown below (red arrow); note that it's hidden and slightly distorts the ST-T wave). Note also that the last sinus P wave has been 'reset' by the PAC resulting in an incomplete pause.



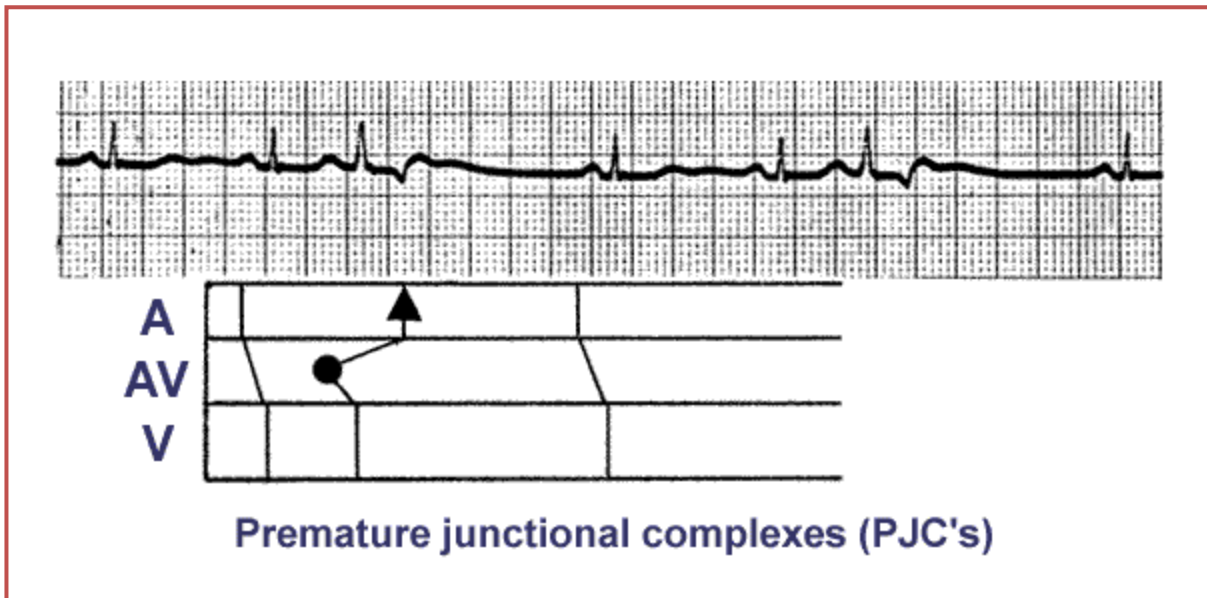
- Outcome #2. **Conducted with aberration**; a PAC conducts into the ventricles but finds one of the 2 bundle branches or one of the left bundle fascicles refractory. The resulting QRS is usually wide, and is sometimes called an **Ashman beat** (see PAC 'b' in the top ladder diagram on p19 (labeled 1) and the V1 rhythm strip below showing a PAC with RBBB aberration; note the PAC hidden in the T wave (arrow). A detailed discussion of aberrant conduction begins on p31. Don't mistake these for PVC's!



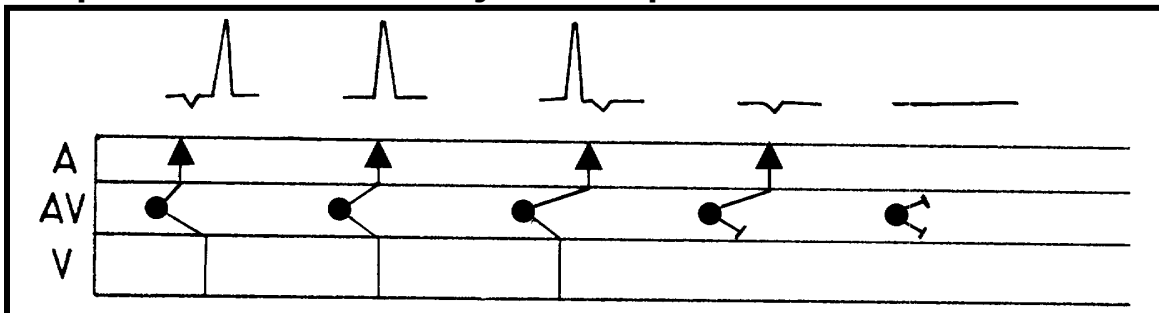
- Outcome #3. **Normal conduction**; i.e., similar to other QRS complexes in that ECG lead. (See PAC 'c' and 'd' in the ladder diagram on p19)
- In the ladder diagram (p19), labeled '2', the cycle length has increased (i.e., heart rate is slower). This results in increased refractoriness in all the ventricular conducting pathways. PAC 'b' now can't get through the AV node and is **nonconducted**; PAC 'c' is now blocked in the right bundle branch and results in a RBBB QRS complex (**aberrant conduction**); PAC 'd' occurs later and conducts normally. RBBB aberration is generally more common because the right bundle normally has a slightly longer refractory period (RP) than the left bundle. In diseased hearts, however, either bundle branch or a left bundle fascicle may have the longest RP and account for the particular aberration in QRS waveform.
- **Therefore, the fate of a PAC depends on both 1) the coupling interval or distance from the sinus P wave, and 2) the preceding cycle length or heart rate.**
- The pause after a PAC is usually **incomplete**; i.e., the PAC can **reset** the sinus node timing, causing the next sinus P to appear earlier than expected. (PVCs, on the other hand, are usually followed by a **complete** pause because the PVC usually does not disrupt the sinus node timing; see the ECG rhythm strip below and also the diagram on p29.)



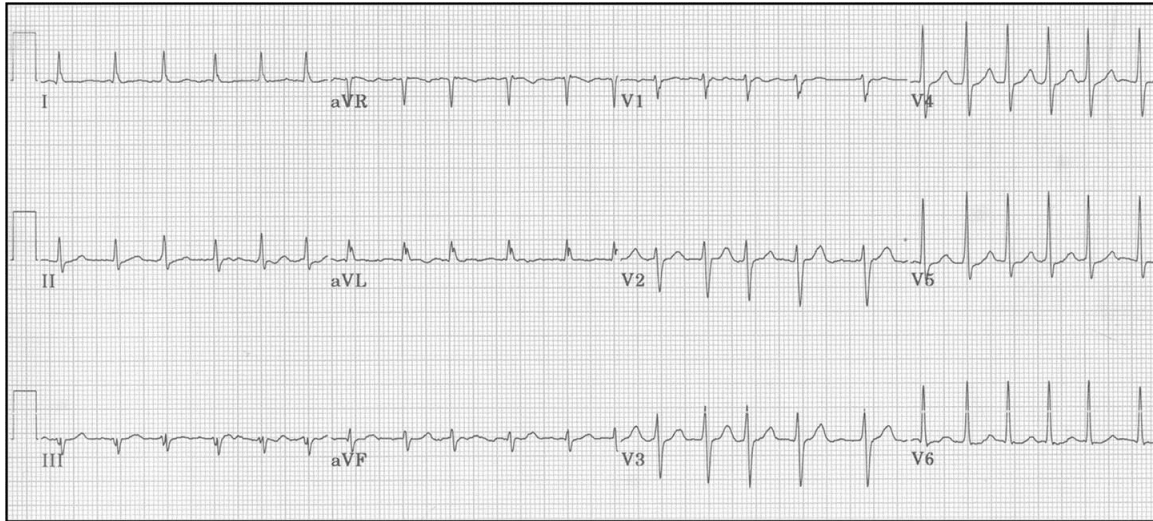
- **"Incomplete" pause:** The sinus PP interval surrounding the above PAC is less than 2 preceding normal PP intervals (because the PAC resets the sinus timing)
- **"Complete" pause:** The PP interval surrounding the above PVC is equal to 2 normal PP intervals because the sinus continued to fire at its regular rate even though it didn't conduct to the ventricle (see the sinus P hidden in the T wave of the PVC).
- **No Pause:** sometimes a PVC or PAC (less likely) is sandwiched between two sinus beats without interrupting the sinus cycle. In this case it is called an *interpolated* PVC (or PAC).
- **Premature Junctional Complexes (PJC's)**
 - Similar to PAC's in clinical implications, but less frequent.
 - The PJC focus in the AV junction (usually located in the His bundle) may capture both the atria (retrograde) and the ventricles (antegrade). The retrograde P wave can appear **before, during, or after** the QRS complex depending on conduction timing; if before, the PR interval is usually short (i.e., <120 ms). Retrograde P waves are usually inverted in the inferior leads because of the superior direction of atrial activation. The ECG tracing and ladder diagram shown below illustrates a classic PJC with retrograde P waves occurring **after** the QRS. Various other outcomes are also illustrated below.



Five possible outcomes of AV junctional premature beats

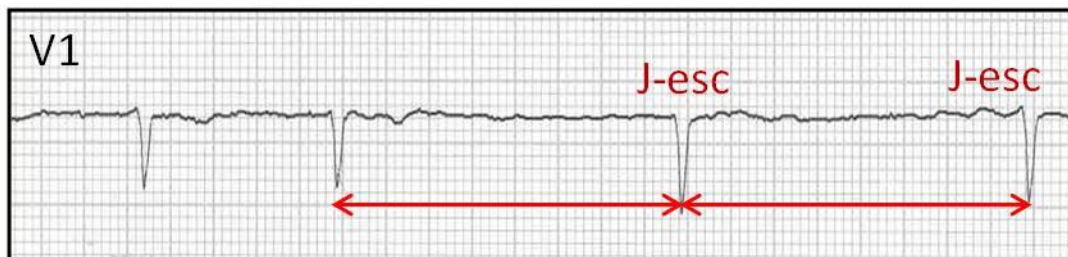

- **Atrial Fibrillation (A-fib):**

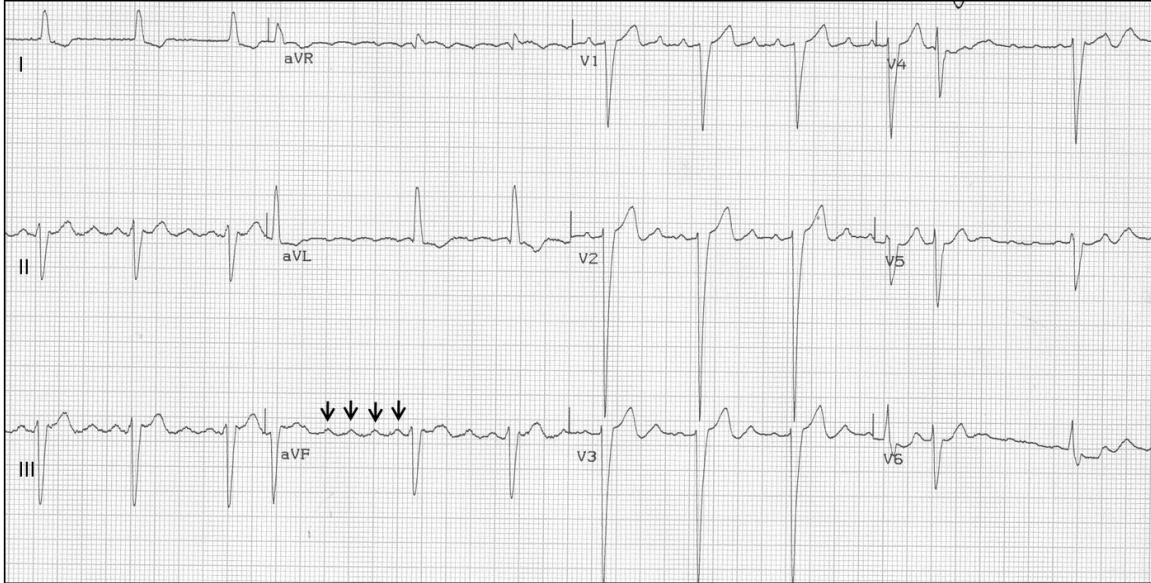


Atrial fibrillation with a rapid ventricular response (note the subtle irregularity)

- Atrial activity is poorly defined; may see coarse or fine baseline undulations (wiggles) *or* no atrial activity at all. If atrial activity is seen, it resembles the teeth on an **old saw** (when compared to atrial flutter that often resembles a **new saw** or a clean **saw-tooth pattern** especially in leads II, III, and aVF).
- Ventricular response (RR intervals) is **irregularly irregular** and may be **fast** (HR >100 bpm, indicates inadequate rate control), **moderate** (HR = 60-100 bpm), or **slow** (HR <60 bpm, indicates excessive rate control medication, AV node disease, or AV nodal blocking drugs including beta blockers and digoxin). Recent studies indicate that **resting** HR's <110 bpm may be tolerated in atrial fibrillation, although not optimal.
- A **regular** ventricular response with A-fib usually indicates high grade or complete AV block with an escape or accelerated ectopic pacemaker originating in the AV junction or ventricles (i.e., consider digoxin toxicity or AV node disease). In the ECG strip shown below the last 2 QRS complexes are junctional escapes indicating high-grade AV block due (note: the last two RR intervals are the same indicating a fixed escape rate from a backup pacemaker in the AV junction).



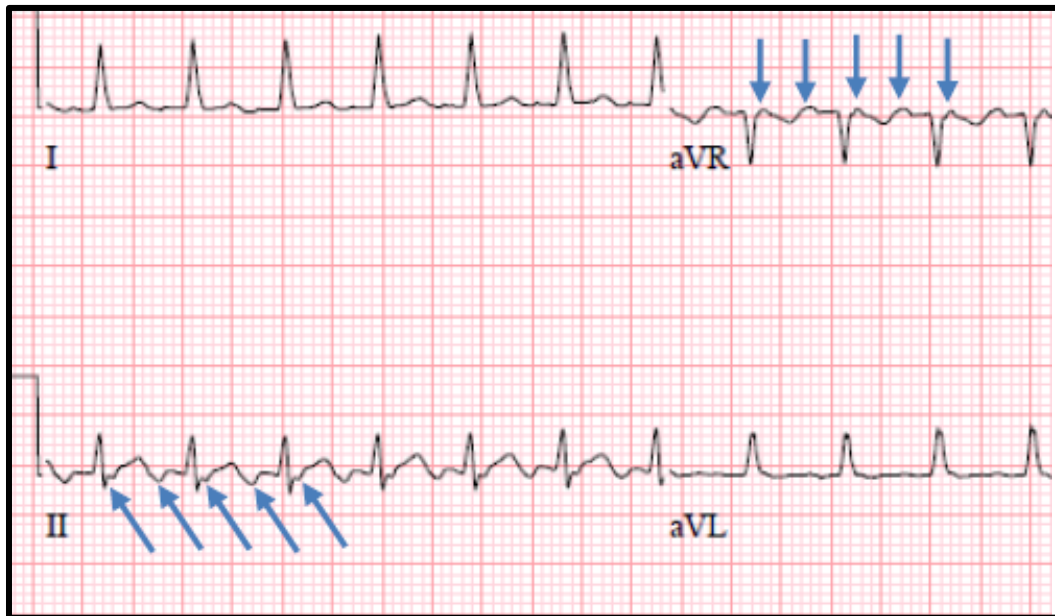
- Irregularly-irregular SVT's may also be seen in atrial flutter with variable AV block, **and** in multifocal atrial tachycardia (MAT). The differential diagnosis is often hard to make from a single lead rhythm strip; a 12-lead ECG is best for differentiating these three arrhythmias (see the next 12-lead ECG on p23).



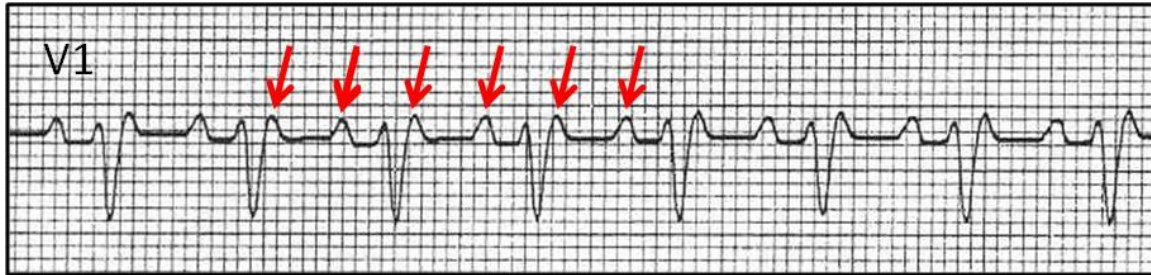Atrial flutter with variable HR (note also LVH and left anterior fascicular block, LAFB)

• **Atrial Flutter (A-flutter):**

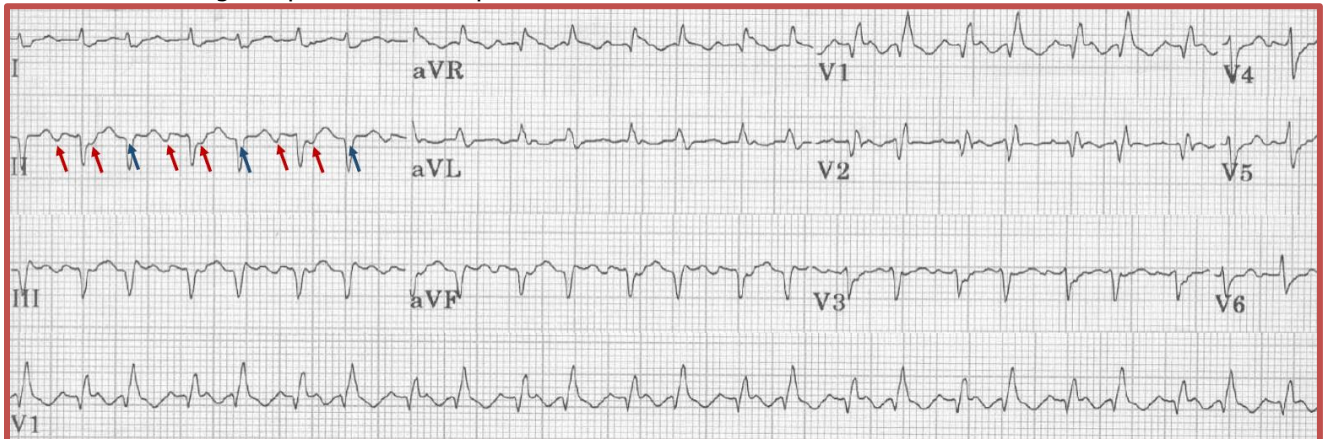
- Regular atrial activity usually with a clean **saw-tooth** or 'picket-fence' appearance best seen in leads II, III, aVF, and more discrete looking 'P' waves in lead V1. The atrial rate is usually about 300/min, but may be as slow as 150-200/min or as fast as 400-450/min. The above ECG also shows LVH and left anterior fascicular block (LAFB).
- Untreated A-flutter often presents with a 2:1 A-V conduction ratio. This the **most commonly missed arrhythmia diagnosis** because the flutter waves are often difficult to find. Therefore, always think: **"atrial flutter with 2:1 block" whenever there is a regular SVT @ approximately 150 bpm!** (You aren't likely to miss it if you look for it.) In the 12-lead ECG shown above varying RR ratios are seen. Below are selected leads of 2:1 atrial flutter. Note the ventricular rate ~160 bpm and the atrial rate ~320 bpm. (Arrows are usually not present on your ECG's. Just think: 'atrial flutter with 2:1 block'!)



- The ventricular response in atrial flutter may be 2:1, 3:1 (rare), 4:1, or variable depending upon AV conduction properties. A-flutter with 2:1 block is illustrated in the V1 rhythm strip below; one of the flutter waves occurs at the end of the QRS (pseudo RBBB pattern). Atrial rate =280 bpm, ventricular rate =140 bpm. Flutter waves in lead V1 often look like upright P waves, don't they?.



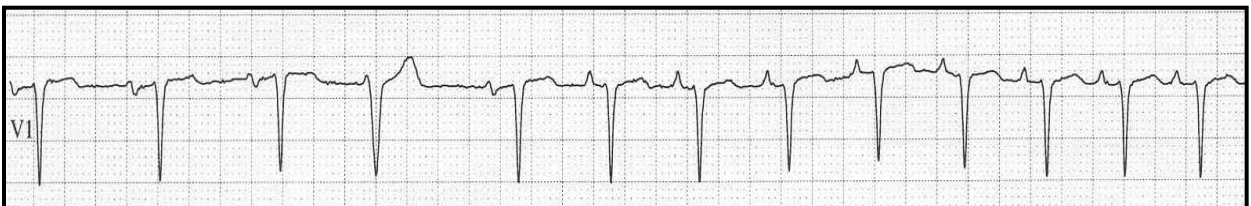- Occasionally atrial flutter can conduct with a 3:2 ratio resulting in a confusing bigeminal QRS pattern as seen in the next ECG from a patient with an old inferior myocardial infarction. Red arrows indicate the conducted flutter waves and blue arrows the nonconducted ones. Note also alternating complete and incomplete RBBB best seen in lead V1.



Atrial flutter with 3:2 AV conduction

• **Ectopic Atrial Tachycardia and Rhythms**

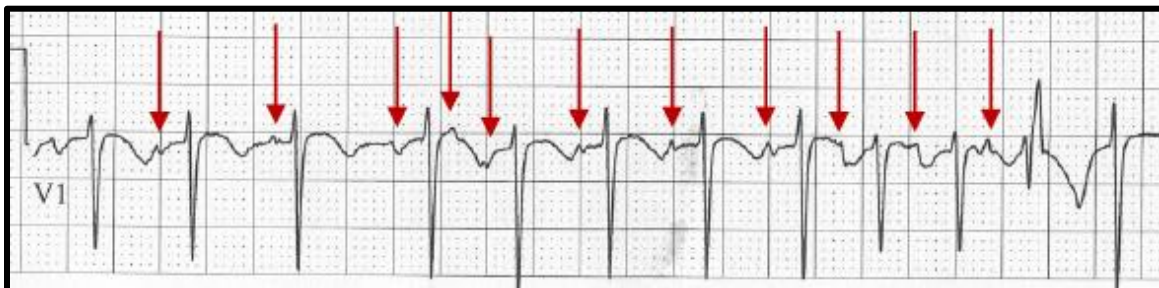
- Ectopic, discrete looking, unifocal P waves with atrial rates <250/min (not to be confused with slow atrial flutter).
- Ectopic P' waves usually precede QRS complexes with P'R interval < RP' interval (i.e., not to be confused with paroxysmal supraventricular tachycardia with retrograde P waves shortly after the QRS complexes).



- The above V1 strip begins with a sequence of 3 sinus beats followed a PVC and one more sinus beat; after this 4th sinus beat note the onset of an ectopic atrial tachycardia (HR >100 bpm) and different, unifocal P wave morphology).
- Ventricular response may be 1:1 (as in the above ECG strip) **or** with varying degrees of AV block (especially in the setting of digoxin toxicity).

- Ectopic atrial rhythms are similar to ectopic atrial tachycardia, but with HR < 100 bpm. The ectopic P' wave morphology is clearly different from the sinus P wave.
- **Multifocal Atrial Tachycardia (MAT) and rhythm**
 - Discrete, multifocal P' waves occurring at rates of 100-250/min and with varying P'R intervals (one usually sees at least 3 different P wave morphologies in a given lead).
 - Ventricular response is irregularly irregular (i.e., often confused with A-fib).
 - May be intermittent, alternating with periods of normal sinus rhythm.
 - MAT is seen most often in elderly patients with chronic or acute medical problems such as exacerbation of chronic obstructive pulmonary disease.
 - If the atrial rate is <100 bpm, call it **multifocal atrial rhythm**.
 - May be confused with atrial fibrillation in some leads; look for discrete P waves!

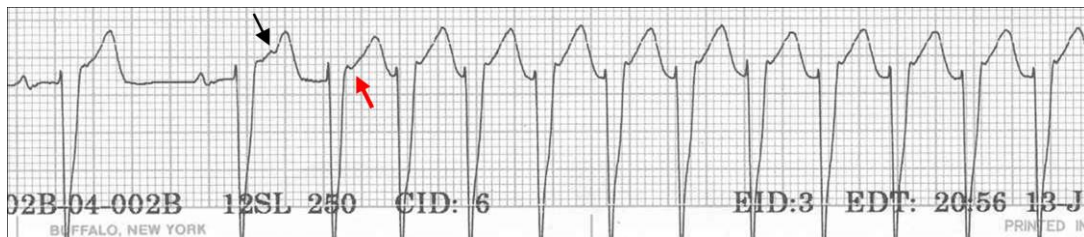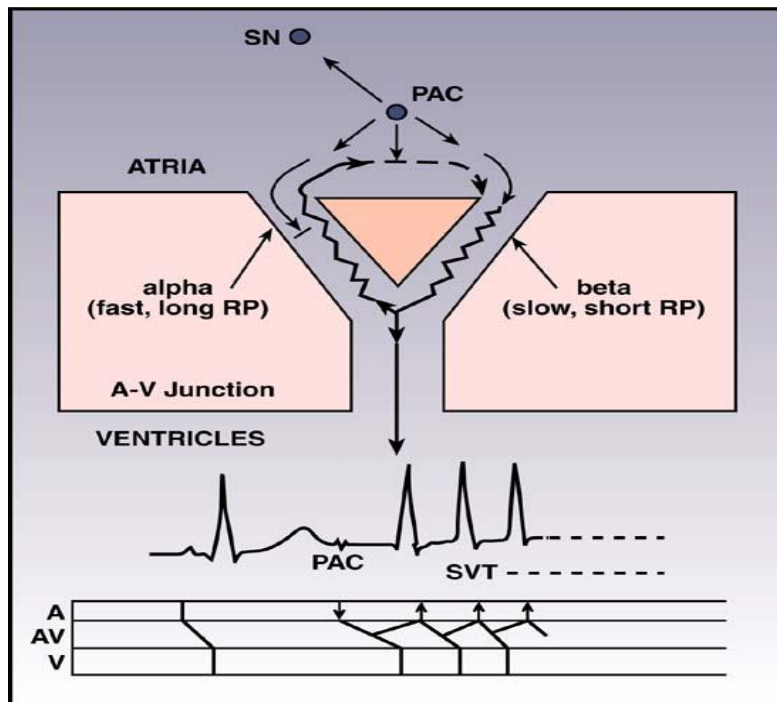
MAT: Look at next V1 rhythm strip for discrete multifocal conducted and nonconducted P waves (red arrows), and note the one aberrantly conducted beat (rsR'). (Remember, arrows are not present in the ECG's you interpret)



Multifocal Atrial Tachycardia (MAT)

Paroxysmal Supraventricular Tachycardia (PSVT)

- **Basic Considerations:** Unlike ectopic pacemaker rhythms these arrhythmias are '*circus movement*' tachycardias that use the mechanism of **reentry**, they are also called **reciprocating** tachycardias. The onset is sudden, usually initiated by a premature beat, and the arrhythmia also stops abruptly - which is why they are called **paroxysmal** tachycardias. They are usually narrow-QRS tachycardias unless there is preexisting bundle branch block (BBB) or aberrant ventricular conduction (i.e., rate related BBB). There are several types of PSVT depending on the location of the reentry circuit.
- **AV Nodal Reentrant Tachycardia (AVNRT):** This form of PSVT accounts for approximately 75% of all symptomatic PSVTs. The next diagram illustrates the mechanism involving dual AV nodal pathways, labeled **alpha** and **beta**, each having different electrical properties. In the diagram **alpha** is a faster pathway but with a longer refractory period (RP); **beta** is a slower pathway but with a shorter RP. During sinus rhythm **alpha** is always used because it is faster, and there is plenty of time between sinus beats for alpha to recover. An early PAC, however, may find **alpha** still refractory but conducts down the slower **beta** pathway to reach the ventricles. As it slowly traverses **beta**, **alpha** has had time to recover allowing retrograde conduction back to the atria. The retrograde P wave (sometimes called an **atrial echo**) occurs simultaneous with or just after the QRS and may not be easily seen on the ECG; but it can 'reenter' the AV junction because of **beta's** short RP and continue the circus-movement tachycardia. Vagal maneuvers and AV nodal slowing drugs and break the circuit and end the tachycardia.



The above ECG V1 strip begins with 2 sinus beats followed by an early PAC (black arrow) that initiates the onset of **AVNRT**. Retrograde P waves (red arrow) immediately follow each QRS (seen as a little dip at onset of ST segment – resembling a pseudo r' in the V1 lead).

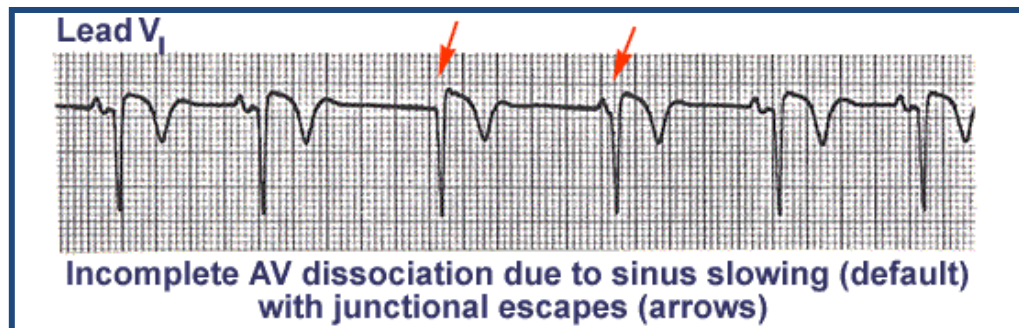
Rarely, an atypical form of AVNRT occurs with the retrograde P wave appearing in front of the next QRS (i.e., RP' interval > 1/2 the RR interval), implying antegrade conduction down the faster **alpha**, and retrograde conduction up the slower **beta** pathway.

- **AV Reciprocating Tachycardia (AVRT, Extranodal bypass pathway):** This is the second most common form of PSVT and is seen in patients with the WPW syndrome. The WPW ECG, seen in the diagram on p14, has a short PR, a **delta** wave, and somewhat widened QRS.
- This type of PSVT can even occur in the absence of the typical WPW QRS pattern when in sinus rhythm if the accessory pathway only allows retrograde conduction (i.e., **concealed** WPW). Like AVNRT, the onset of PSVT is usually initiated by a PAC that finds the bypass track refractory, conducts through the slower AV junction into the ventricles, and reenters the atria through the bypass track. In this type of PSVT retrograde P waves usually appear a little later after the QRS in the ST segment (i.e., RP' < 1/2 RR interval). Rarely the antegrade limb for this circuit uses the bypass track, and the retrograde limb uses the AV junction; the PSVT then resembles a wide QRS tachycardia and must always be differentiated from ventricular tachycardia.

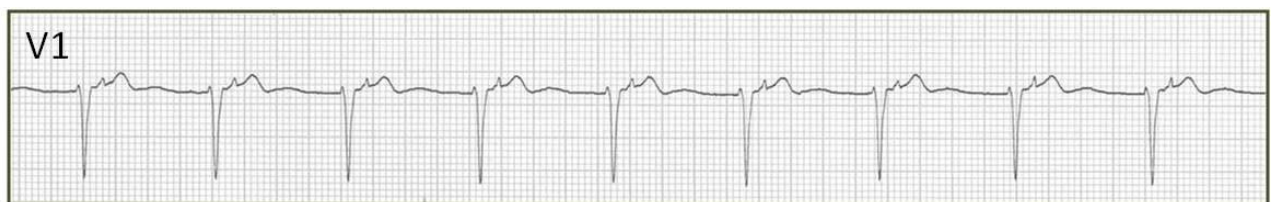- **Sino-Atrial Reentrant Tachycardia:** This is a rare form of PSVT where the reentrant circuit is between the sinus node and the right atria. The ECG looks just like sinus tachycardia, but the tachycardia is paroxysmal; i.e., it starts and ends abruptly.

- **Junctional Rhythms and Tachycardias**

- **Junctional Escape Beats:** These are *passive*, beats originating from a backup pacemaker in the AV junction. The pacemaker's basic firing rate is ~40-60 bpm; junctional escapes are programmed to occur whenever the primary pacemaker (i.e., sinus node) defaults or the AV node blocks the atrial impulse from reaching the ventricles. The next ECG strip shows marked sinus arrhythmia with two junctional escapes (red arrows) due to sinus slowing. Incomplete AV dissociation is also seen during the junctional escapes; the sinus P waves are hidden in the junctional beats.



- **Junctional Escape Rhythm:** This is a sequence of 3 or more junctional escape beats occurring by default at a rate of ~40-60 bpm. There may be AV dissociation, or the atria are captured retrogradely from the junctional focus. These rhythms may occur normally (e.g., in athletes) when the resting sinus rate slows (due to increased vagal tone) below the escape rate of the junctional pacemaker. They may also occur in patients with sick sinus node disease or those on heart rate slowing drugs (e.g., beta blockers).
- **Accelerated Junctional Rhythm:** This is an *active* junctional pacemaker rhythm caused by perturbations that excite pacemaker cells in the AV junction (e.g., ischemia, inflammation, drugs, and some electrolyte abnormalities). The accelerated rate is 60-99 bpm. The V1 rhythm strip shown below shows an accelerated junctional rhythm at ~70 bpm with retrograde P waves hiding in the ST segment. The clinical question is: what is causing this accelerated rhythm, and what, if anything, needs to be done?

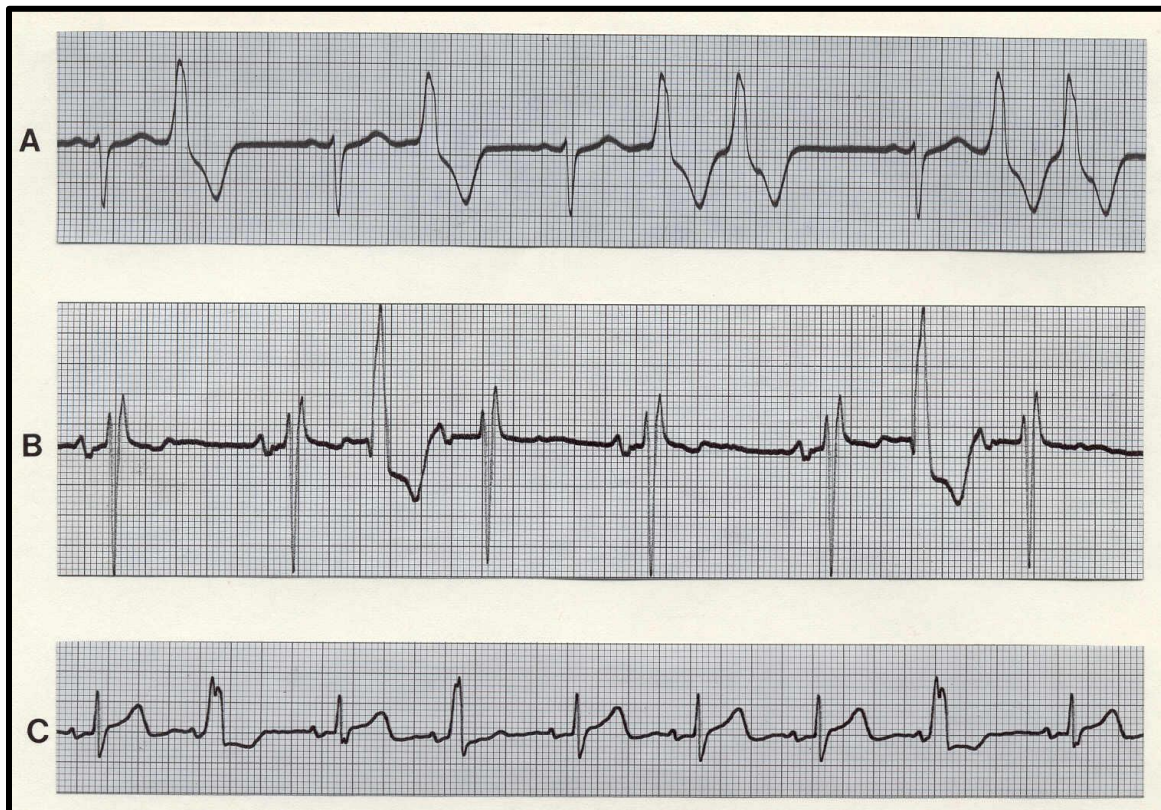


- **Nonparoxysmal Junctional Tachycardia:** This usually begins as an accelerated junctional rhythm but the heart rate gradually increases to ≥ 100 bpm. There may be AV dissociation, or retrograde atrial capture may occur. Ischemia (usually from right coronary artery occlusion in acute inferior MI patients) and digoxin intoxication are the two common causes.

II. Ventricular Arrhythmias

• **Premature Ventricular Complexes (PVCs)**

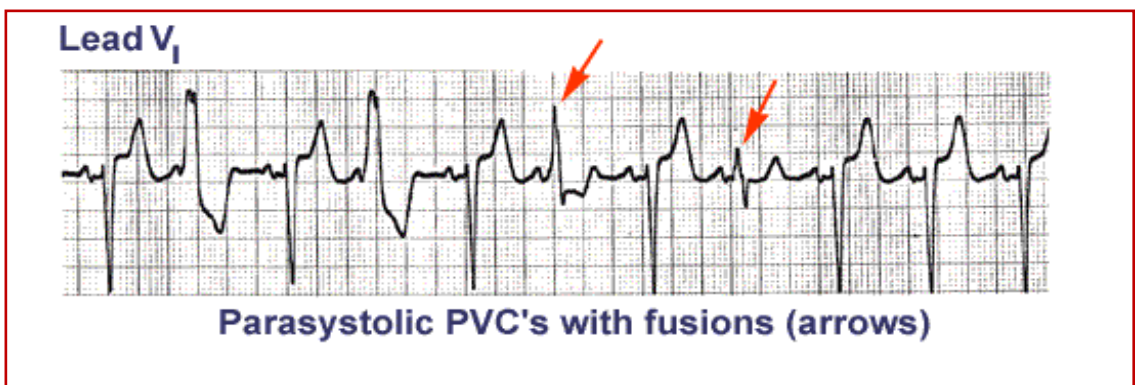
- PVCs may be unifocal, multifocal or multiformed. *Multifocal* PVCs have different sites of origin and different coupling intervals (from previous QRS complexes). Multiformed PVCs usually have the same coupling intervals (because they originate in the same ectopic site but their conduction through the ventricular myocardium varies. Multiformed PVCs used to be common in digoxin intoxication, but dig-toxicity is rarely seen today due to infrequent use and lower doses. PVCs can occur as isolated, single events or as couplets, triplets, and salvos (4-6 PVCs in a row) which are actually short runs of nonsustained ventricular tachycardia.
- PVC's are almost always wide QRS complex arrhythmias ($QRS \geq 120$ ms) because they originate in either the right or left ventricle and conduct sequentially into the other ventricle. Analyzing the direction of the QRS in various ECG leads usually enables one to determine the ventricle of origin and even the approximate location in the ventricle.
- Clinically, infrequent and even frequent PVC's may be seen in healthy subjects as a result of external perturbations from stimulants or stressful situations. They are also common in various heart diseases and may be precursors to more malignant ventricular arrhythmias, cardiac arrest, and sudden death episodes.



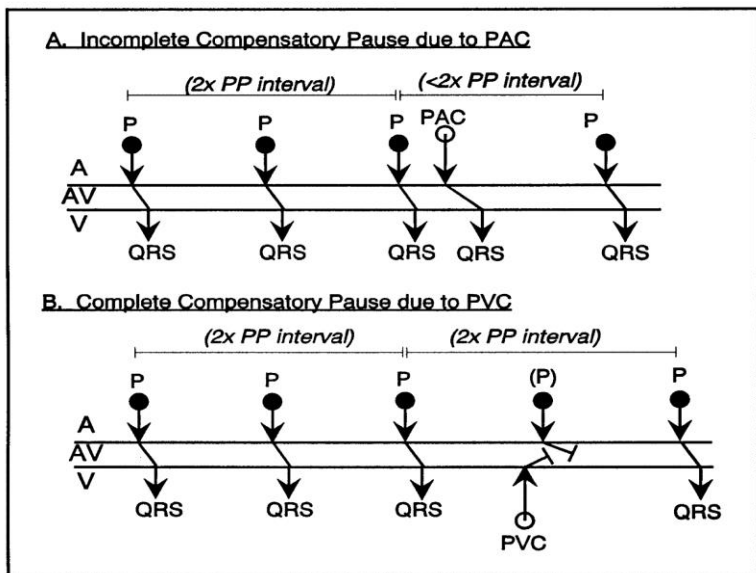
- In the above ECG strips 'A' illustrates single, unifocal PVCs and PVC couplets; 'B' illustrates **interpolated** PVCs (i.e., sandwiched between 2 regular sinus beats, not followed by a pause; the PR interval after the interpolated PVC is prolonged because the PVC retrogradely enters the AV junction slowing the subsequent antegrade sinus conduction); 'C' illustrates late or **end-diastolic** PVCs with and without fusion. PVCs may occur early in the cycle (R-on-T phenomenon), after the T wave, or late in the cycle - often fusing with the next sinus QRS (called a *fusion beat*; see the 2nd PVC in

strip 'C'). R-on-T PVCs may be especially dangerous in acute ischemic settings, because the ventricles are more vulnerable to ventricular tachycardia or fibrillation.

- In the next ECG strip, late (end-diastolic) PVCs are illustrated with varying degrees of **fusion**. For fusion to occur the sinus P wave must have already entered the ventricles to initiate the ventricular activation sequence. Before ventricular activation is completed, however, the "late" PVC occurs resulting in a QRS looking a bit like the normal QRS, and a bit like the PVC; i.e., a fusion QRS (see arrows in the next strip). This is similar to the 2nd PVC with fusion in strip 'C' above.



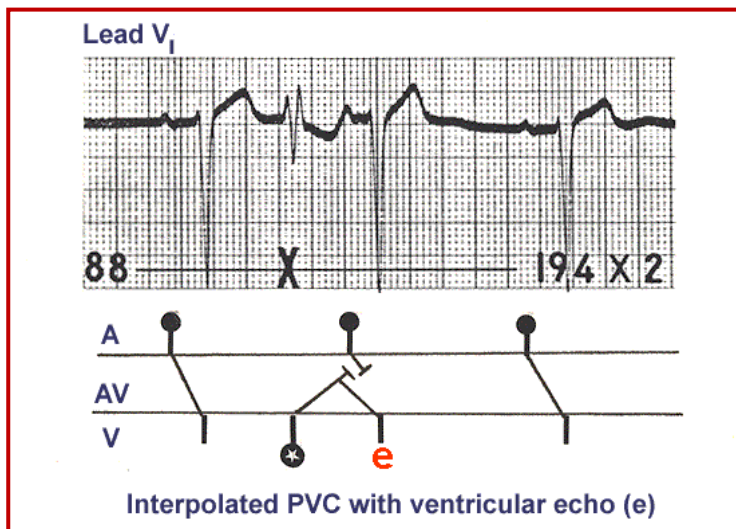
- The events following a PVC are also of interest. Usually a PVC is followed by a complete compensatory pause, since the sinus timing is usually not interrupted by the PVC; one sinus P wave occurs during the ST-T of the PVC and can't conduct to the ventricles because the ventricles are refractory; the next sinus P wave occurs on time based on the underlying sinus rate. In contrast, PACs are usually followed by an incomplete pause because the PAC resets the sinus node timing; this enables the next sinus P wave to appear earlier than expected. These concepts are illustrated in the diagram below as well as in the ECG strip seen on the bottom of p20.



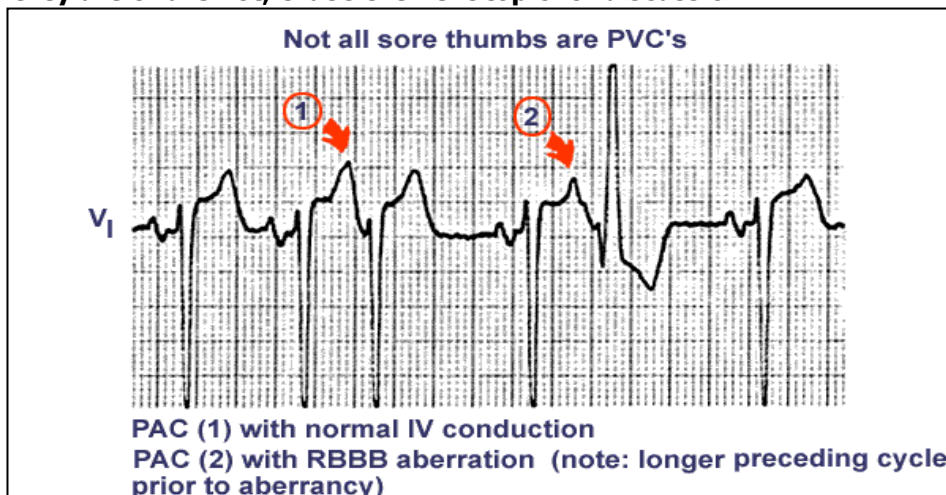
- Not all PVCs are followed by a pause. If a PVC occurs early enough (especially when the sinus rate is slow), it can be "sandwiched" between two normal sinus beats. These PVC's are called **interpolated** PVCs as discussed on p28. The sinus P wave following the PVC usually has a longer PR interval because of *retrograde concealed*

conduction by the PVC into the AV junction slowing subsequent conduction of the sinus impulse (see strip 'B' on p28).

- Some PVCs conduct retrogradely into the atria and reset the sinus node timing resulting in an *incomplete pause*. Often the retrograde P wave can be seen hiding in the ST-T wave of the PVC.
- A most unusual post-PVC event occurs when retrograde activation of the AV junction (or atria) re-enters (or comes back to) the ventricles as a **ventricular echo**. This is illustrated in next ECG strip of lead V1. The "ladder" diagram under the ECG helps us understand the mechanism. The P wave following the PVC is in fact the next sinus P wave, **but** the PR interval is too short for it to have caused the next QRS. (Remember, the PR interval following an interpolated PVC is usually longer than normal, not shorter!). The PVC must have conducted retrogradely into the AV junction (but not into the atria) and then 'reentered' the ventricles resulting in a normal QRS complex (called an echo beat, 'e' for ventricular echo). Note the timing of the sinus P waves is not interrupted. Amazing, isn't it?



- PVCs usually stick out like "sore thumbs" or funny-looking-beats (FLB's), because they are wide and different-looking in morphology compared to the normal QRS complexes. However, not all premature "sore thumbs" are PVCs. In the example below 2 PACs are seen: #1 has a normal QRS like the sinus beats, and #2 has a QRS with RBBB aberrancy (rsR') - which sticks out like a sore thumb (FLB). **The diagnostic challenge, therefore, is to differentiate sore thumbs for what they are or are not; that's the next topic for discussion!**



(The following section [pp 31-42] on "Aberrant Ventricular Conduction" was written jointly by Drs. Alan Lindsay, Frank Yanowitz, and J. Douglas Ridges in the 1980's. – almost 40 years ago! Appropriate modifications and additions from the original have been made for the 21st Century.)

ABERRENT VENTRICULAR CONDUCTION

INTRODUCTION

Aberrant ventricular conduction (AVC) is a very common source of confusion in interpreting 12-lead ECGs and rhythm strips. A thorough understanding of its mechanism and recognition is essential to all persons (and computers) who interpret ECGs.

Before we can understand aberrant ventricular conduction we must first review how normal conduction of the electrical impulse occurs in the heart (Figure 1). **What a magnificent design!** Impulses from the fastest center of automaticity (usually the SA node) are transmitted through the atria and over specialized tracts, including **Bachmann's bundle** into the left atrium and three inter-nodal tracts to the AV node. The AV node provides sufficient conduction delay to allow atrial contraction to contribute to ventricular filling. Following slow AV node conduction high velocity conduction tracts deliver the electrical impulse to the right and left ventricles (through the His bundle, bundle branches and fascicles, and into the Purkinje network). **Near-simultaneous** activation of the two ventricles results in a **NORMAL, NARROW QRS COMPLEX** (60-109 ms QRS duration). Should conduction delay or block occur in one of the two bundle branches an **ABNORMAL WIDE QRS COMPLEX** will reflect **sequential** activation of the ventricles. (A delay or block in a fascicle of the left bundle branch will also result in an abnormal, but not necessarily wide QRS but one of different morphology (e.g., a change in frontal plane QRS axis) from the person's normal QRS morphology).

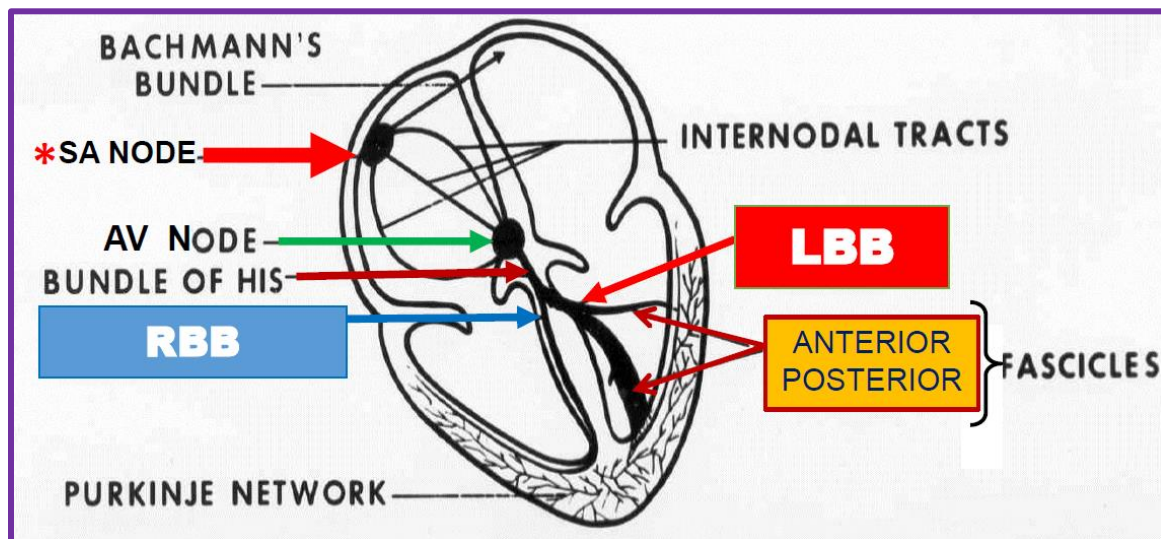


Figure 1 (note: the left bundle often has a third branch called the *septal fascicle*, not shown in the above figure)

The next ECG strip (Figure 2) illustrates a basic principle of AVC. AVC refers to a *temporary alteration of QRS morphology when one might expect a normal QRS complex*. Permanent or rate-dependent bundle branch block (BBB) is **NOT AVC**.

In this discussion we will concentrate on AVC through normal bundle branch and fascicular pathways and not consider conduction through accessory pathways (e.g., as in WPW syndrome). The ECG illustrated in Figure 2 from lead V1 begins with two normal sinus beats followed by a premature atrial complex (PAC, first arrow). The narrow QRS complex of the PAC resembles the QRS morphology of the sinus beats. After an incomplete pause, another sinus beat is followed by a slightly earlier PAC. Now, because of this slightly increased prematurity (and also the longer preceding RR interval), the QRS morphology is wide and different (rsR' morphology of RBBB). If not careful one might mistake this wide funny looking beat (FLB) as a PVC and attach a different clinical significance (and possible therapy). The diagram and examples on p19-20 also illustrate the different "fates" of PACs. The important clues to recognizing AVC in Figure 2 are:

1. Searching for a premature P-wave (P') or ***Cherchez le P*** (in French)
2. Recognizing the typical RBBB triphasic QRS morphology (rsR' in lead V1)

Lead V1

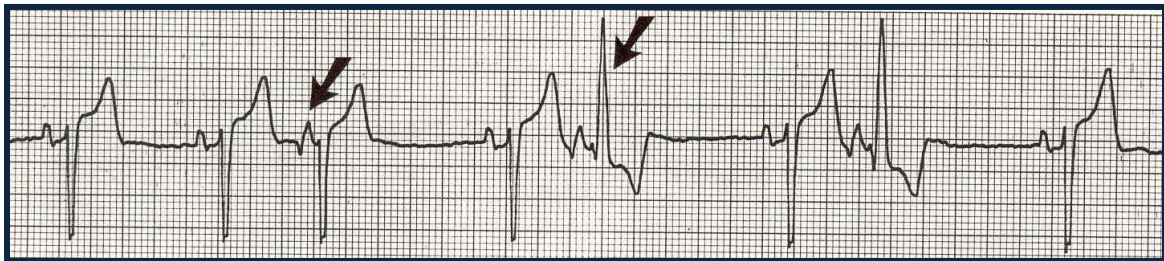


Figure 2

ABERRANT VENTRICULAR CONDUCTION

A term that describes a temporary alteration of QRS morphology under conditions where a normal QRS is be expected. The common types are:

- 1. Using normal conduction pathways:**
 - **Cycle-length dependent (aka, Ashman phenomenon)**
 - **Rate-dependent tachycardia or bradycardia**
- 2. Using accessory pathways (e.g., Kent bundle)**

Five features or clues help identify AVC of the **right bundle branch block** variety, the most common form of AVC. It should be emphasized that although RBBB morphology is the most common form of AVC, LBBB or block in one or more of its three fascicles may also occur, particularly in persons with more advanced left heart disease or those taking cardiovascular drugs. In healthy people the right bundle branch has a slightly longer refractory period than the left bundle at normal heart rates and, therefore, is more likely to be unavailable when an early PAC enters the ventricles. Feature #5, the "second-in-a-row" phenomenon, will be illustrated later in this section.

FEATURES FAVORING RBBB ABERRANT CONDUCTION

- 1. Preceding atrial activity (premature P wave)**
- 2. rsR' or rSR' morphology in lead V1**
- 3. qRs morphology in lead V6**
- 4. Same initial r wave as the normal QRS complex (in lead V1)**
- 5. "Second-in-a-row" phenomenon**

The **Ashman Phenomenon** is named after the late Dr. Richard Ashman who first described, in 1947, AVC of the RBBB variety in patients with atrial fibrillation. Ashman reasoned, from

observing ECG rhythms in patients with a-fib, that the refractory period (during which conducting tissue is recovering and cannot be activated) was directly proportional to the RR cycle length or heart rate. The longer the cycle length (or slower the heart rate) the longer the refractory period. In Figure 3 PACs (arrows) are normally conducted when the preceding cycle length is of short or medium duration but are blocked in the right bundle if the preceding RR cycle is long. Ashman observed this in atrial fibrillation when long RR cycles were followed by short RR cycles and the QRS terminating the short RR cycle was wide in duration (looking like RBBB).

Look at the 'old' ECG rhythm strips in Figure 3. Simultaneous Lead II and Lead V1 are recorded. The first PAC (first arrow in V1) conducts to the ventricles with a normal QRS duration because the preceding cycle was of normal or medium length. The second PAC (next arrow) conducts with RBBB (rsR' in V1) because the preceding cycle was **LONGER**. Both PACs have identical coupling intervals from the preceding sinus P wave. Thus, a long cycle-short cycle sequence often leads to AVC. Unfortunately this sequence helps us **UNDERSTAND AVC** but is not **DIAGNOSTIC OF AVC**. PVCs may also occur in a long cycle-short cycle sequence. It is important, therefore, to have other clues to the differential diagnosis of funny looking QRS beats (FLBs).

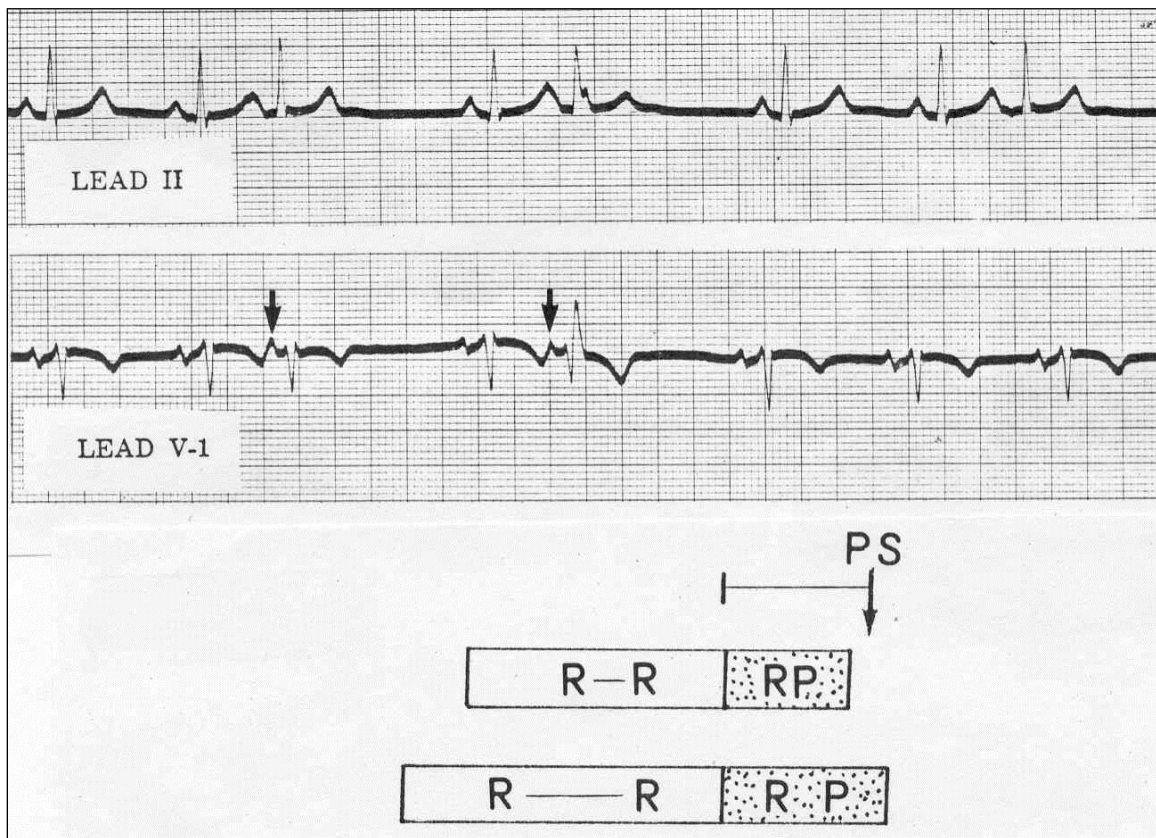


Figure 3

Years ago **Dr. Henry Marriott**, a wonderful master teacher of electrocardiography and author of many outstanding ECG textbooks and journal articles offered valuable morphologic clues to aberrant QRS morphologies (especially as seen in lead V1). These morphologies contrasted with the QRS complexes often seen with PVCs and enhanced our ability to diagnose AVC. For example, if the QRS in lead V1 is predominately up-going or positive (Figure 4) the differential diagnosis is between RBBB aberrancy and ventricular ectopy usually from the left ventricle. A

careful look at each of the 5 QRS morphologies in Figure 4 will identify the “Las Vegas” betting odds of making the correct diagnosis.

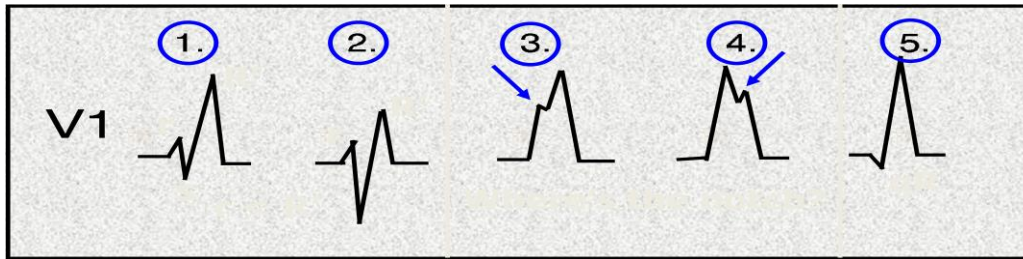


Figure 4

QRS #1 and #2 are “classic” triphasic RBBB morphologies with rsR’ or rSR’ QRS shapes. When either of these is seen in a V1 premature beat we can be at least 90% certain that they are aberrant RBBB conduction and not ventricular ectopy. Examples #3 and #4 are notched or slurred monophasic R waves resembling ‘rabbit ears’. Where’s the notch or slur? If the notch or slur is on the **downstroke** of the R wave (see smaller right rabbit ear in Example #4), then the odds are almost 100-to-1 that the beat is a left ventricular ectopic beat (i.e., a PVC). If, on the other hand, the notch or slur is on the **upstroke** of the R wave (smaller rabbit ear on the left as in Example #3), then the odds are only 50:50 and not helpful in the differential diagnosis. Finally if the QRS complex has just a qR configuration (Example #5) than the odds are reasonably high that the beat in question is a left ventricular ectopic beat and not AVC. Two exceptions to this last rule (#5) need to be remembered. Occasionally the normal QRS in V1 does not have an initial little r-wave in the QRS (i.e., just a QS morphology). If RBBB occurs in such a person the QRS morphology in V1 will be a qR instead of an rsR’. Secondly, in a person with a previous anteroseptal myocardial infarction the QRS in V1 will have a QS morphology, and new RBBB in such a person will also have a qR pattern (where the R is really the R’ of RBBB).

Now consider mostly down-going or negative wide QRS morphologies in lead V1 (Figure 5). Here the differential diagnosis is between LBBB aberration (Example #1) and right ventricular ectopy (Example #2). Typical LBBB in lead V1 may or may not have a “thin” initial r-wave, but will always have a rapid and clean descending S-wave as seen in #1. On the other hand, any one of three features illustrated in #2 is great betting odds that the beat in question is of ventricular origin and not AVC. The three features are: 1) fat initial r-wave, 2) notch or slur in the descending limb of the S wave, and 3) a 0.06 sec or more delay from the beginning of the QRS to the nadir of the S wave.

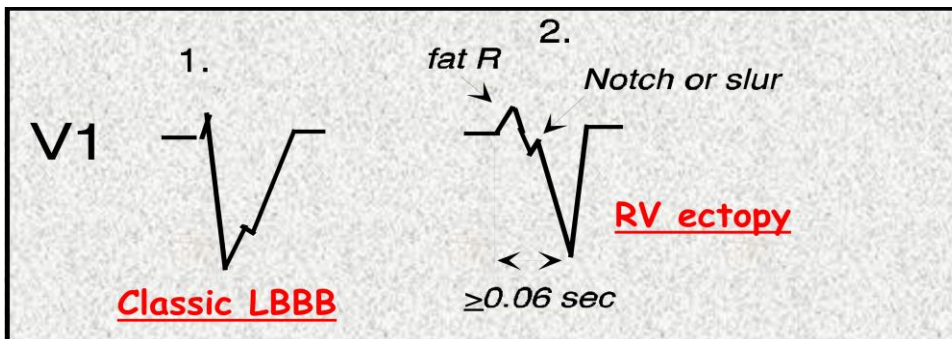


Figure 5

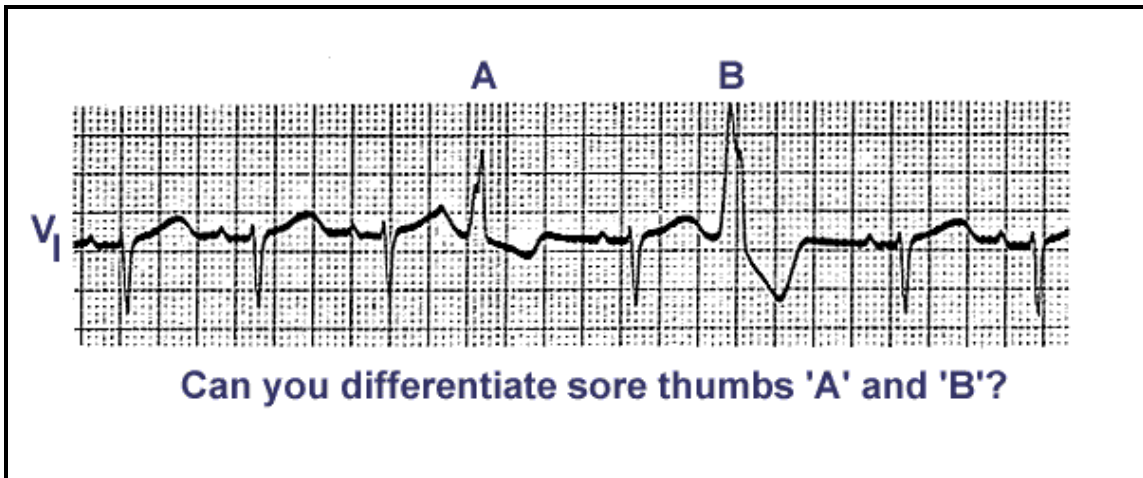


Figure 6

Now, let's look at some real ECG examples of the preceding QRS morphology clues. We will focus on the V1 lead for now since it is the best lead for differentiating RBBB from LBBB, and right ventricular ectopy from left ventricular ectopy.

Figure 6 (above) illustrates two premature funny-looking beats (FLBs) for consideration. FLB 'A' has a small notch on the upstroke of the QRS complex resembling #3 in Figure 4. Remember, that's only a 50:50 odds for AVC and therefore not helpful in the differentiating it from a PVC. However, if you look carefully at the preceding T wave, you will see that it is more pointed than the other T waves in this V1 rhythm strip. There is very likely a hidden premature P-wave in the T before 'A', making the FLB a PAC with RBBB aberrancy. Dr. Marriott would say: "**Cherchez le P**" which is sexy way in French to say "**Search for the P**" before a FLB to determine if the FLB is a PAC with AVC. FLB 'B', on the other hand, has a small notch or slur on the downstroke of the QRS resembling #4 in Figure 4. That's almost certainly a PVC (and originating in the left ventricle (because it's moving in an anterior direction in the V1 lead). Also note that 'A' is followed by an incomplete pause; 'B' has a complete pause.

Unfortunately sometimes there are exceptions to the morphology rules! In Figure 7, after 2 sinus beats with incomplete RBBB, a bigeminal rhythm develops. The 3 premature FLBs have **TYPICAL TRIPHASIC RBBB MORPHOLOGY** (rSR') and yet they are PVCs and not AVC! How can we tell? They are not preceded by premature P-waves, but are actually followed (look in the ST segment) by the next normal sinus P-wave which can't conduct because the ventricles are refractory at that time. The subsequent sinus P wave comes on time (i.e., a complete pause).

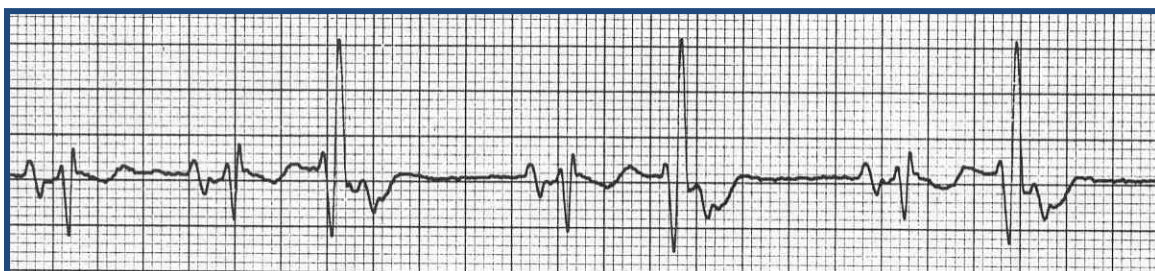


Figure 7 (three PVC's)

The rhythm illustrated in the six leads of Figure 8 was actually interpreted as "Ventricular bigeminy" in our ECG lab by a tired physician reading late at night. Try to see if you can do better. The first thing to notice is that the two premature beats in lead V1 have RBBB (rsR')

morphology...already a 10:1 odds favoring AVC. Note also that some the T waves of the sinus beats look a little “funny” – particularly in Leads 1, 2, and V2. They are small, short, and peak too early, a very suspicious signal that they are, indeed, hidden premature P-waves in the T waves (Cherchez-le-P).

The clincher, however, is that the premature beats are followed by **INCOMPLETE COMPENSATORY PAUSES**. How can you tell in a bigeminal rhythm? One lead (aVF) has no premature beats, so the exact sinus rate (P-P interval) can be measured. Taking 2 sinus cycles from this lead (with your calipers), you can now tell in the other leads that the P waves following the FLBs come earlier than expected suggesting that the sinus cycle was reset by the premature P waves (a common feature of PACs, but not PVCs). The correct diagnosis, therefore, is atrial bigeminy with RBBB aberration of the PACs.

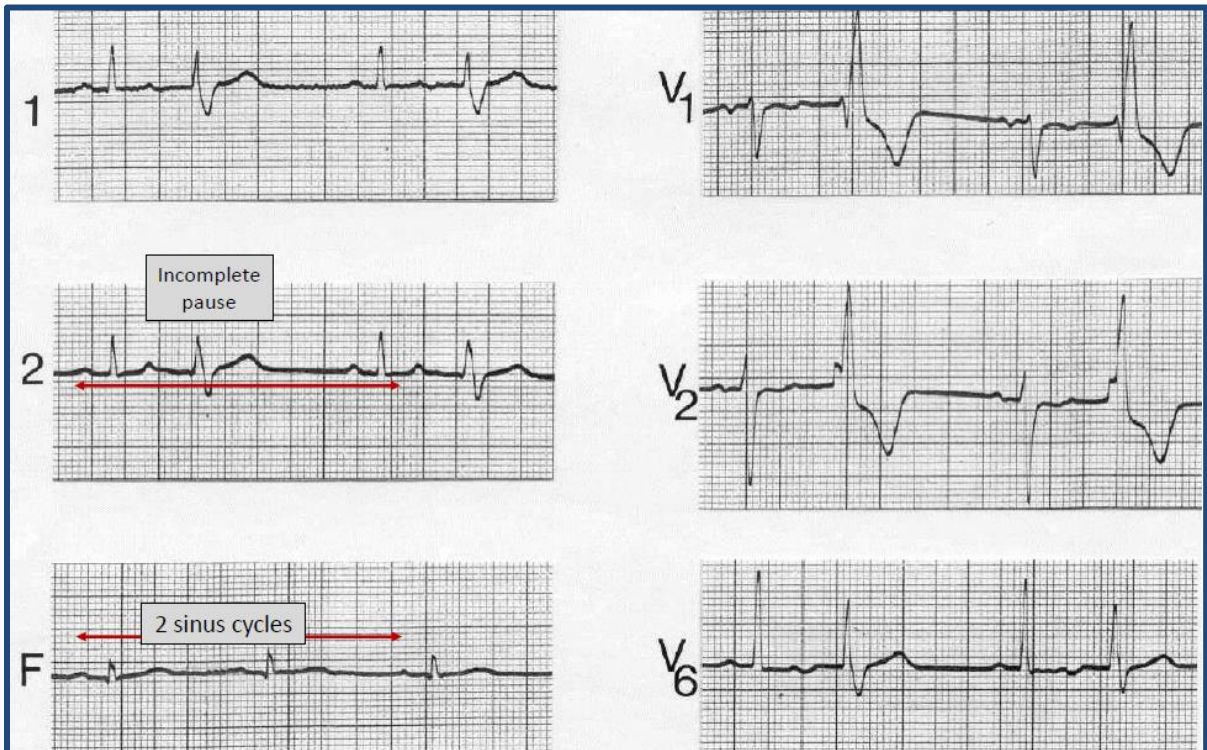


Figure 8

As discussed on p29, the diagram now reproduced in Figure 9 helps us understand the difference between a “complete” compensatory pause (characteristic of most PVCs) and an “incomplete” pause (typical of most PACs). The top half of Figure 9 shows (in “ladder” diagram form) three sinus beats followed by a PAC. The sinus P wave after the PAC comes earlier than expected because the PAC entered the sinus node and reset its timing. In the bottom half of Figure 9 three sinus beats are followed by a PVC. As you can see the sinus cycle is not interrupted, but one sinus beat cannot conduct to the ventricles because the ventricles are refractory due to the PVC. The next P wave comes on time making the pause a complete compensatory pause.

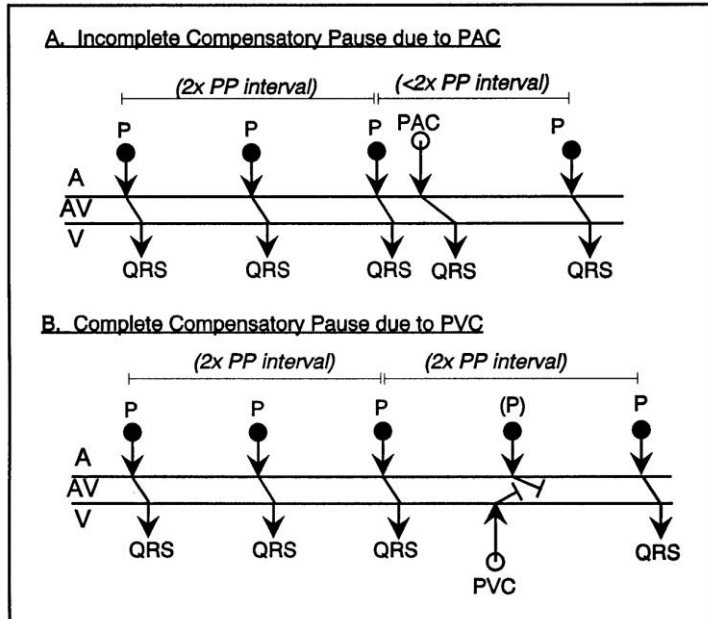


Figure 9

The top ECG strip in Figure 10 illustrates sinus rhythm with 2 PACs conducted with AVC. Note (in French) how the premature P-wave peaks and distorts the preceding T-wave (Cherchez-le-P). The first PAC conducts with LBBB aberrancy and the second with RBBB aberrancy. In the second strip atrial fibrillation is initiated by the 2nd PAC with RBBB aberration (note the long preceding RR interval followed by a short coupled PAC). The aberrantly conducted beat that initiates atrial fibrillation is an example of the "second-in-a-row" phenomenon which is frequently seen in atrial tachyarrhythmias with AVC. It's the second beat in a new sequence of fast supraventricular beats that is often conducted with AVC because of the long-short rule (Ashman phenomenon).

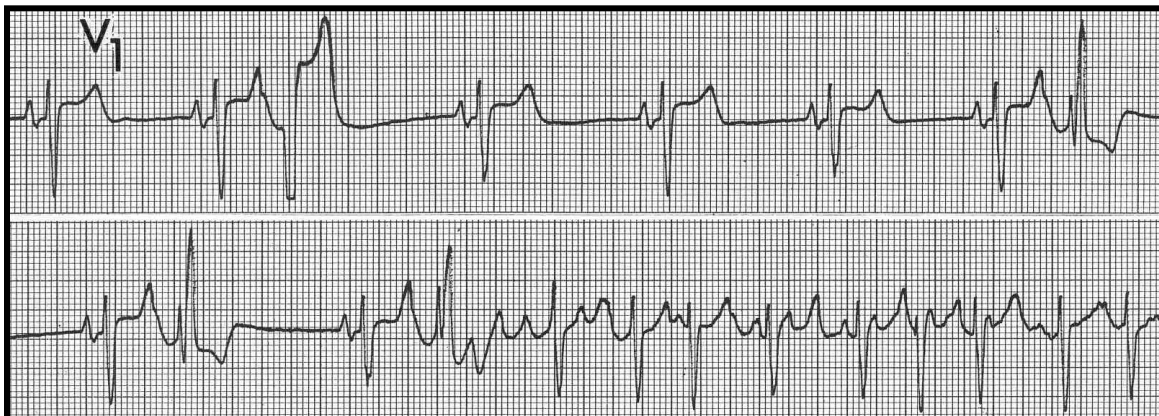

Figure 10

In Figure 11 you can see Ashman beats at their finest. RBBB beats in lead V1 follow the long cycle-short cycle sequence. Since the atria are fibrillating, we can't identify a PAC or "preceding atrial activity" so you have to presume that all QRS's are conducted from the atria. Note that the 2nd FLB in the top strip is followed by a quicker but narrow QRS beat – the right bundle is now responding to a short cycle-short cycle sequence and conducts normally. Dr. Ashman first published this observation in 1947! His name has become a permanent icon in the ECG world.

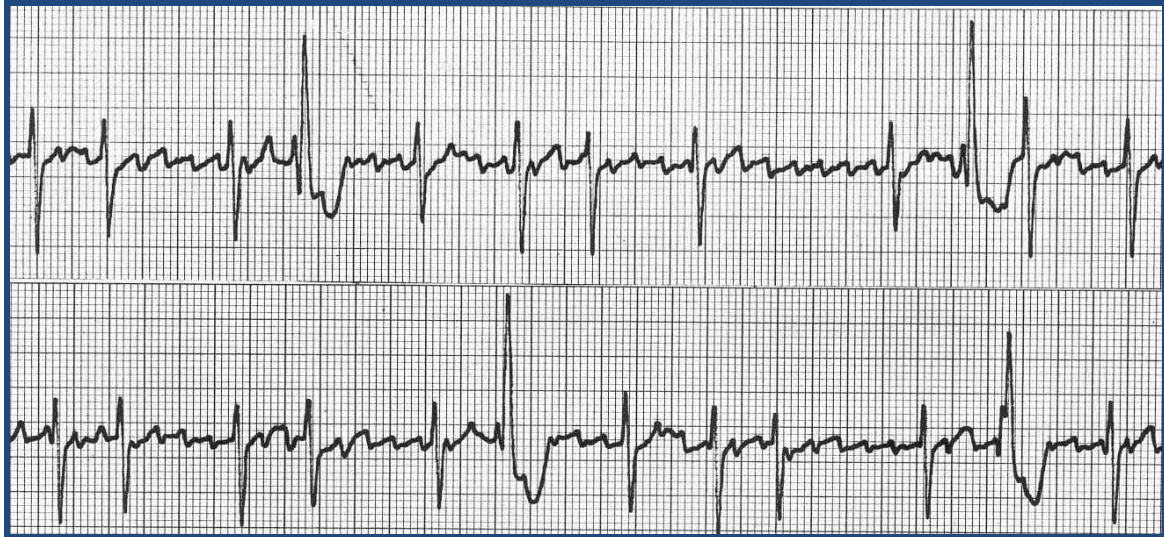


Figure 11 (atrial fibrillation with occasional 'Ashman' beats)

If you're ready for something really interesting, consider the next ECG rhythm illustrated in Figure 12 (originally published by Dr. Alan Lindsay). This unfortunate man suffered from occasional palpitations and dizziness when he swallowed. What we see is the onset of an ectopic atrial tachycardia (after the first 2 sinus beats) with intermittent RBBB aberrant conduction. The arrows point to ectopic P-waves firing at nearly 200 bpm. Note during the tachycardia how the PR intervals gradually lengthen until the 4th ectopic P-wave in the tachycardia fails to conduct (i.e., 2^o AV block or Wenckebach phenomenon). This initiates a pause (longer RR cycle), and when 1:1 conduction resumes the second and subsequent beats have upright QRS complexes of atypical RBBB (note slight slur on upslope of QRS). This is such a *cool* ECG rhythm strip! The man was told to stop swallowing so much!

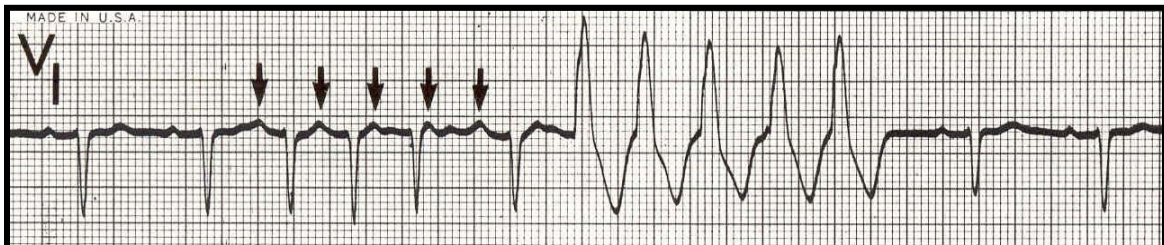


Figure 12 ('Deglutition' induced atrial tachycardia)

Bundle branch block aberration can also occur during a "critical rate" change which means that AVC can appear with gradual changes in heart rate and not necessarily with abrupt changes in cycle length as seen in the Ashman phenomenon. Think of a "tired" but not "dead" bundle branch. This is illustrated in Figure 13 (lead II), an example of rate-dependent or acceleration-dependent AVC. When the sinus cycle, in this instance 71 bpm, is shorter than the refractory period of the left bundle then LBBB ensues. It is almost always the case that as the heart rate subsequently slows it takes a slower rate for the LBBB to disappear (@ 50 bpm), as seen in the lower strip.

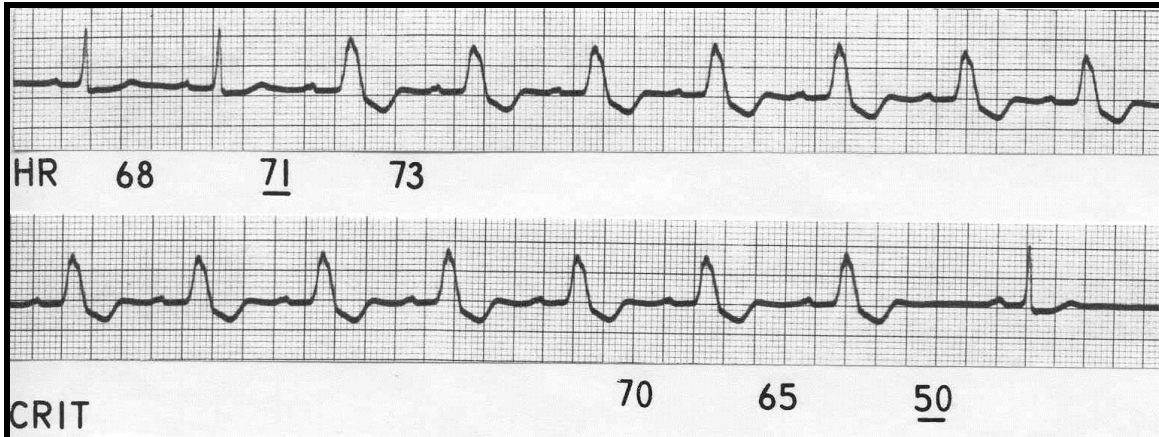


Figure 13

Figure 14 shows another example of acceleration-dependent RBBB, this time in the setting of atrial fibrillation. Even the "normal" beats have a minor degree of incomplete RBBB (rSR'). At critically short cycles, however, complete RBBB ensues and remains until the rate slows again. You can tell that these are not PVCs and runs of ventricular tachycardia because of the typical RBBB morphology (rSR' in lead V1) and the irregular RR cycles characteristic of atrial fib.

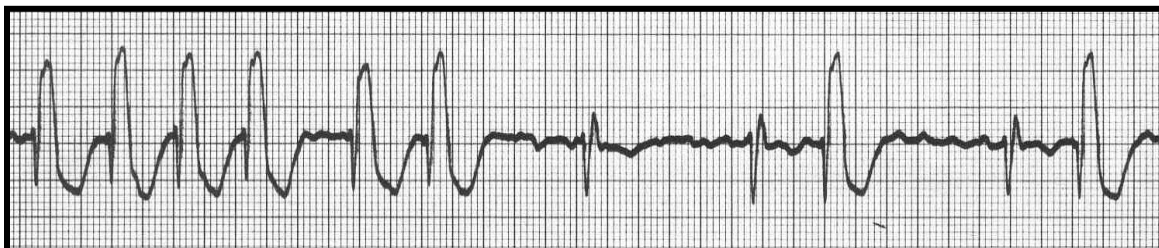

Figure 14

Things can really get scary in the coronary care unit in the setting of acute myocardial infarction. Consider the case illustrated in Figure 15 (lead V1) with intermittent runs of what looks like ventricular tachycardia. Note that the basic rhythm is irregularly irregular indicating atrial fibrillation. The wide QRS complexes are examples of tachycardia-dependent LBBB aberration, not runs of ventricular tachycardia. Note the morphology of the wide beats. Although there is no initial "thin" r-wave, the downstroke of the S wave is very rapid (see #1 in Figure 5, p34).

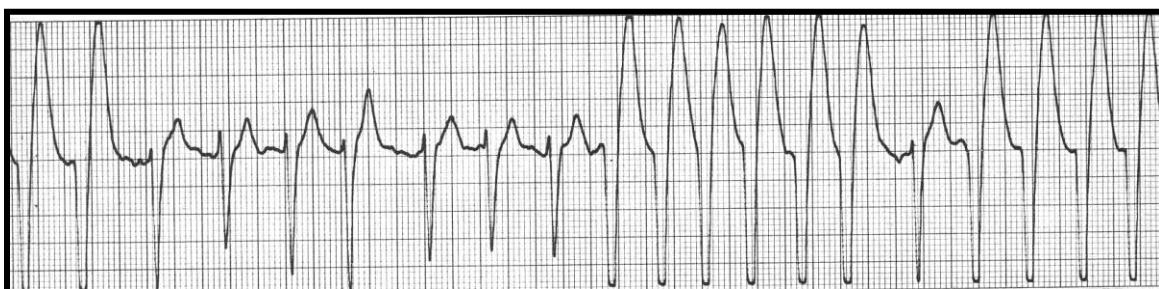

Figure 15

Finally we have an example in Figure 16 of a very unusual and perplexing form of AVC --- **deceleration or bradycardia-dependent aberration**. Note that the QRS duration is normal at rates above 65 bpm, but all longer RR cycles are terminated by beats with LBBB. What a paradox! You have to be careful not to classify the late beats *ventricular escapes*, but in this case the QRS morphology of the late beats is classic for LBBB (see #1 in Figure 5, p34) as evidenced by the

“thin” r-wave and rapid downstroke of the S-wave. This type of AVC is sometimes called “Phase 4” AVC because it’s during Phase 4 of the action potential that latent pacemakers (in this case located in the left bundle) begin to depolarize to become escape beats. Sinus beats entering the partially depolarized left bundle conduct more slowly and sometimes are nonconducted (resulting in LBBB).

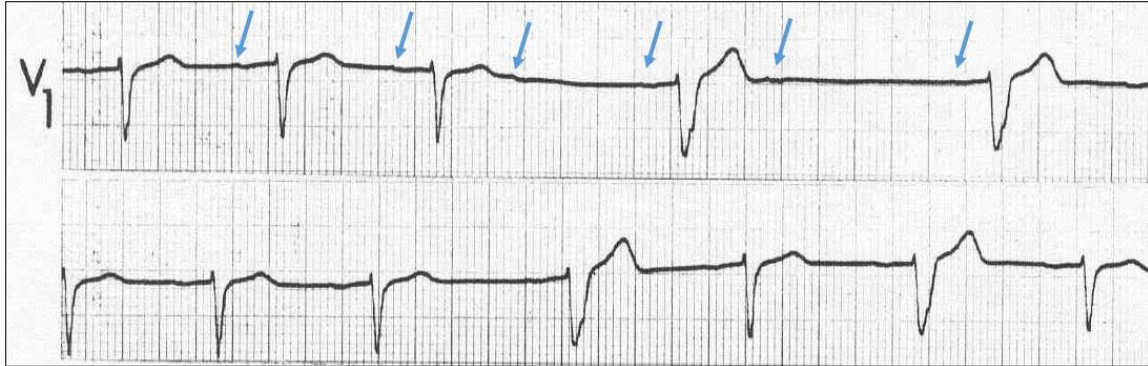

Figure 16

The basic rhythm in Figure 16 is difficult to recognize because sinus P-waves (arrows) are not easily seen in this V1 lead. P-waves were better seen in other leads from this patient. The rhythm is sinus arrhythmia with intermittent 2nd degree AV block (note the nonconducted P waves after the 3rd and 4th QRS).

The ECG strips in Figure 17 summarize important points made in this section. In strip '1' intermittent RBBB is seen during atrial fibrillation. The first two RBBB beats result from an accelerating heart rate (tachycardia-dependent RBBB) while the later triplet of RBBB beats are a consequence of the Ashman phenomenon (long cycle-short cycle sequence). Strip '2' from the same patient (in sinus rhythm) shows two premature FLB's. The first FLB has a QR configuration similar to #5 in Figure 4 (p33) and is most certainly a PVC as the pause following it is a complete compensatory one. The 2nd FLB has the classic triphasic rsR' morphology of RBBB AVC (#1 in Figure 4). The pause following this beat is incomplete which is expected for PACs.

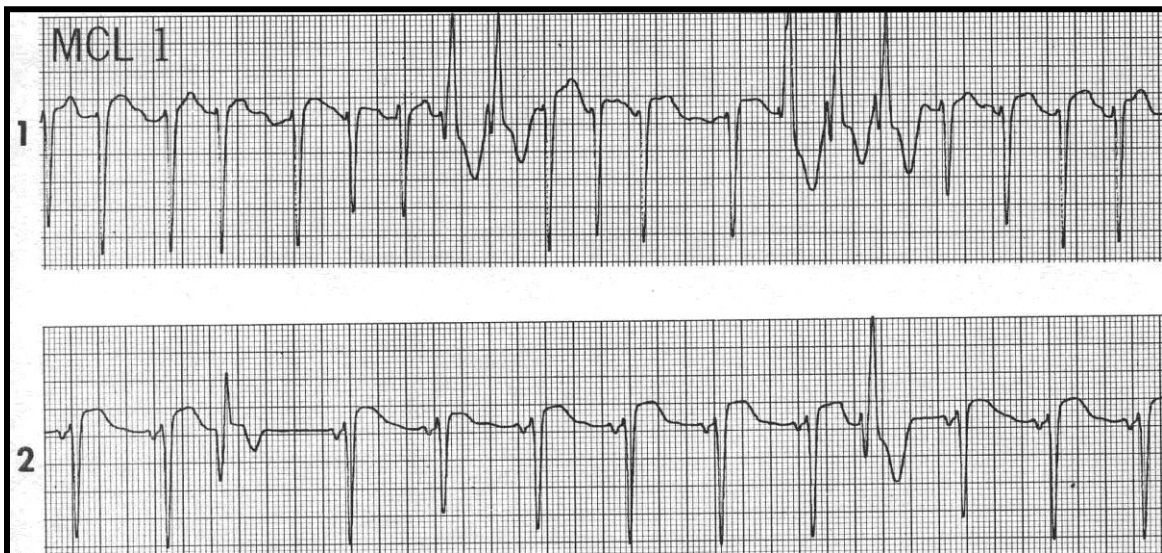


Figure 17 (lead MCL1, monitored in an ICU, is similar to standard lead V1)

Let's look at one more fascinating ECG (Fig 18) with funny-looking beats. On this 12-lead ECG there are 4 PACs (best seen in the V1 rhythm strip). The arrows point to each of the four PACs (three of which are hidden in the T waves). The first PAC conducts with a qR complex in lead V1 indicating an atypical RBBB (see #5 in Figure 4, p33). The lack of an initial 'r'-wave is because the other sinus beats in lead V1 also lack an initial 'r' wave. Note also that in leads I, II and III the QRS of this first PAC has marked left axis deviation (superior, leftward forces) indicative of additional left anterior fascicular block AVC. The second PAC hidden in the T wave has a LBBB type of AVC (see #1 in Figure 5) with a rapid downslope in the QRS complex. The third PAC (also hidden in the T wave) does not have a QRS complex following it and is, therefore, a **nonconducted PAC**. Nevertheless it resets the sinus node which accounts for the pause in rhythm. **(Remember: the most common cause of an unexpected pause in a rhythm is a nonconducted PAC.)** The fourth PAC (seen after the T wave) conducts normally because it's late enough for the conduction pathways to be fully recovered. **This 12-lead ECG is a wonderful example of the three fates of a PAC: 1) normal conduction, 2) aberrant conduction, and 3) no conduction.** It also illustrates that AVC can occur with different forms of aberrancy including bundle branch as well as fascicular conduction delays.

An unrelated, but interesting finding in Figure 18 is the increased U-wave amplitude in leads V1-3 following the nonconducted PAC. This is because the first beat in these leads follows the long pause after the nonconducted PAC. U-waves generally increase in amplitude at slower heart rates. Notice how the U-waves for the 2nd QRS in V1-3 are somewhat smaller reflecting the shorter RR cycle length. More about U-waves later. In other words, "see U later!" and then we can say, "nice seeing U again!" (Note also the voltage criteria for LVH.)

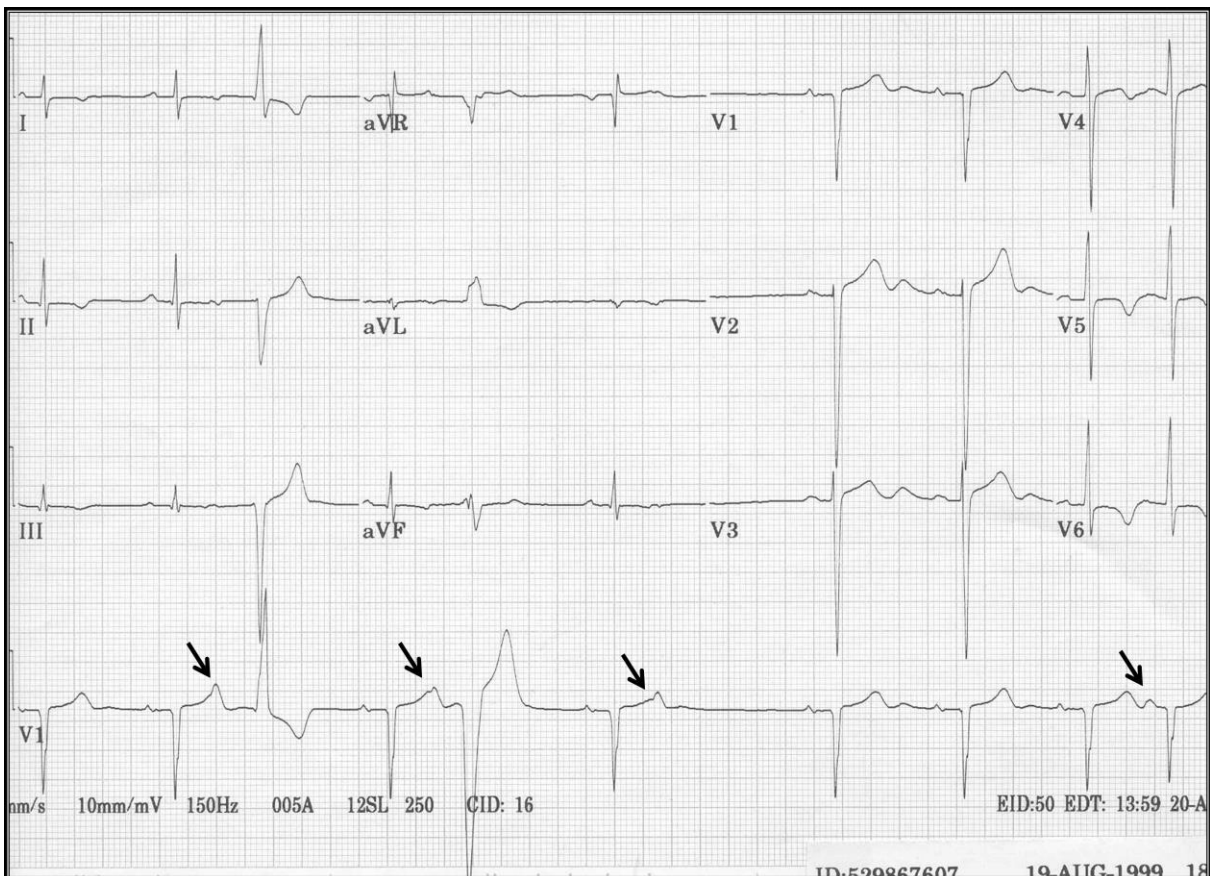


Figure 18

AVC SUMMARY

The differential diagnosis of FLBs is intellectually challenging and has important clinical implications. This section has provided clues that help distinguish wide QRS complexes that are supraventricular in origin with AVC from ectopic beats of ventricular origin (PVCs and ventricular rhythms). When looking at single premature FLBs always search for hidden premature P-waves in the ST-T wave of the preceding beat (Cherchez-le-P). Measure with calipers the pause after the FLB to determine if it's compensatory or not. Remember the lead V1 morphology clues offered in Figures 4 and 5 (p34) that provide reliable (although not perfect) betting odds that a particular beat in question is supraventricular or ventricular in origin. These morphology clues may be the only way to correctly diagnose wide QRS-complex tachycardias.

Don't be fooled by first impressions. **Not all FLBs are ventricular in origin!**

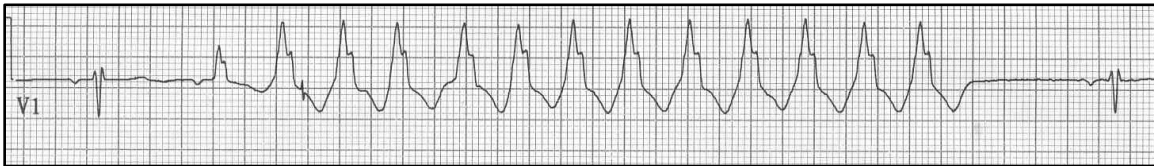
The next section focuses on ECG aspects of ventricular tachycardia and the differential diagnosis of wide QRS tachycardias. Other ventricular rhythms are also briefly discussed.

Ventricular Tachycardia

- Descriptors to consider when thinking about ventricular tachycardia:
 - Sustained (lasting >30 s) vs. nonsustained
 - Monomorphic (uniform morphology) vs. polymorphic vs. Torsade-de-pointes (**Torsade-de-pointes**: a polymorphic ventricular tachycardia associated with the long-QT syndromes characterized by phasic variations in the polarity of the QRS complexes around the baseline. Ventricular rate is often >200 bpm and ventricular fibrillation is often a consequence causing sudden cardiac death.)
 - Presence of AV dissociation (independent atrial activity) vs. retrograde atrial capture
 - Presence of fusion QRS complexes (also called 'Dressler' beats) which occur when supraventricular beats (usually of sinus origin) slip into the ventricles during the ectopic ventricular activation sequence.
- Differential Diagnosis: just as for single premature funny-looking beats, **not all wide QRS 'funny looking' tachycardias are ventricular in origin (they may be supraventricular tachycardias with bundle branch block or WPW preexcitation)!**
 - ***Differential Diagnosis of Wide QRS Tachycardias***
 - Although this is an ECG tutorial, let's not forget some simple bedside and **clinical clues** to ventricular tachycardia (VT):
 - Presence of advanced heart disease (e.g., coronary heart disease and heart failure) favors ventricular tachycardia
 - Cannon 'a' waves in the jugular venous pulse suggests ventricular tachycardia with AV dissociation. Under these circumstances atrial contraction from a dissociated sinus rhythm may sometimes occur when the tricuspid valve is closed causing retrograde blood flow into the jugular veins (giant 'a' wave).
 - Variable intensity of the S1 heart sound at the apex (mitral closure); again this is seen when there is AV dissociation resulting in varying position of the mitral valve leaflets depending on the timing of atrial and ventricular systole.
 - If the patient is hemodynamically unstable, it's probably ventricular tachycardia and act accordingly!
 - **ECG Clues:**
 - Regularity of the rhythm: Sustained monomorphic (i.e., all QRS's look the same) ventricular tachycardias are usually regular (i.e., equal RR intervals); an

irregularly-irregular wide-QRS rhythm suggests atrial fibrillation with aberration or with WPW preexcitation. (Of course, it could also be VT)

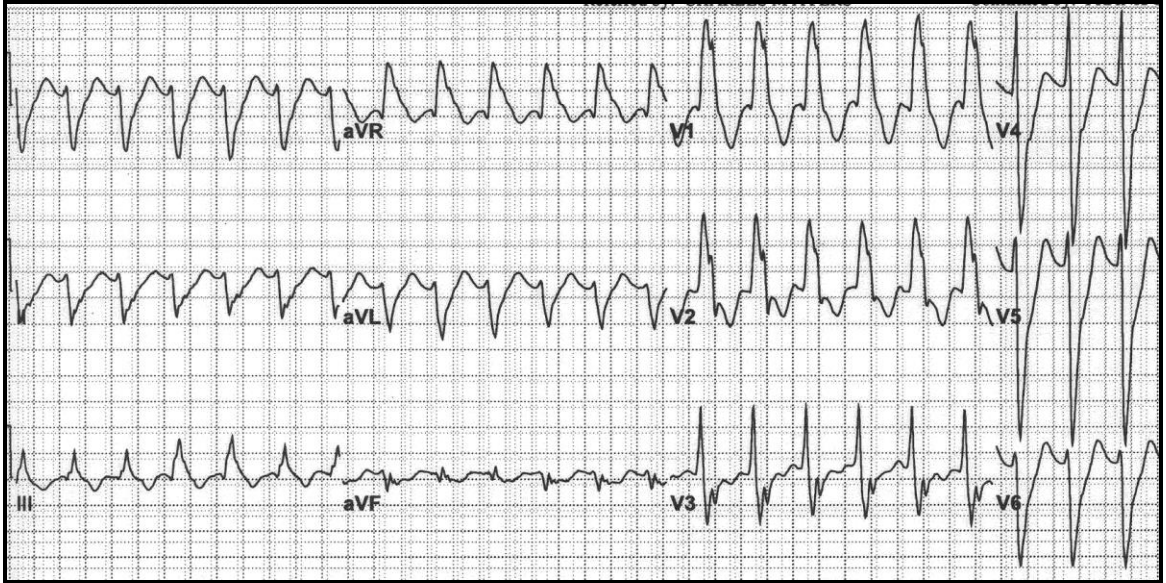
- A-V Dissociation strongly suggests ventricular tachycardia! Unfortunately AV dissociation only occurs in ~50% of ventricular tachycardias (the other 50% have retrograde atrial capture or "V-A association"). Of the V-tachs' with AV dissociation, it can only be easily recognized when the tachycardia rate is <150 bpm. Faster heart rates make it difficult to detect or 'see' the dissociated P waves.
- Fusion beats or captures often occur when there is AV dissociation and this also strongly suggests a ventricular origin for the wide QRS tachycardia.
- QRS morphology in lead V1, illustrated in Figures 4 and 5 (p34), is often the **best clue** to the origin, so go back and check out these clues (betting odds)!



Nonsustained 'left' ventricular tachycardia (note the first beat in the run is a **fusion beat**)

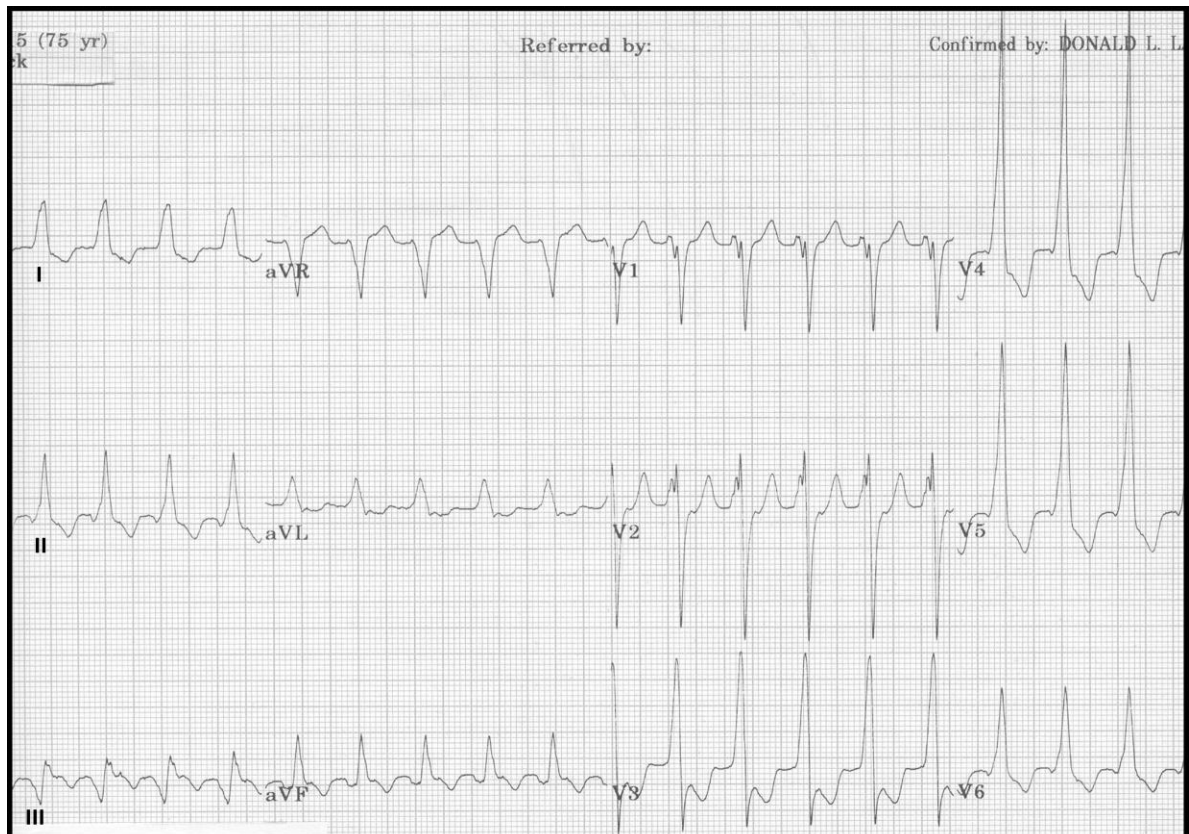
- Also consider a few additional morphology clues:
 - Bizarre frontal-plane QRS axis (i.e. from +180 degrees to -90 degrees or NW quadrant) suggests ventricular tachycardia
 - QRS morphology during the tachycardia is identical to previously seen PVCs suggests ventricular tachycardia
 - If all the QRS complexes from V1 to V6 are in the same direction (either all positive or all negative), ventricular tachycardia is likely.
 - Mostly or all negative QRS morphology in V6 suggests ventricular tachycardia
 - Especially wide QRS complexes (>0.16s) suggests ventricular tachycardia
 - Also consider the famous **Four-Question Algorithm** reported by *Brugada et al, Circulation 1991;83:1649*:
 - **Step 1:** Absence of RS complex in all leads V1-V6? If **Yes: Dx is ventricular tachycardia!**
 - **Step 2: No:** Is interval from beginning of R wave to nadir of S wave >0.1s in any RS lead? If **Yes: Dx is ventricular tachycardia!**
 - **Step 3: No:** Are AV dissociation, fusions, or captures seen? If **Yes: Dx is ventricular tachycardia!**
 - **Step 4: No:** Are there morphology criteria (see p32) for VT present both in leads V1 and V6? If **Yes: Dx is ventricular tachycardia!**
 - If **NO: Diagnosis is supraventricular tachycardia with aberration!**

The ECG shown next illustrates several clues to typical VT: 1) QRS morphology in lead V1 looks like #4 in Figure 4, p34; the notch is on the downstroke of the R wave; 2) the QRS is mostly negative in lead V6; 3) bizarre northwest quadrant frontal plane QRS axis of -180 degrees (both leads I and II are predominately negative. This VT is most likely from the left ventricle (note the direction of QRS forces is rightward and anterior; i.e., the QRS originates in the leftward, posterior LV).



Left Ventricular Tachycardia

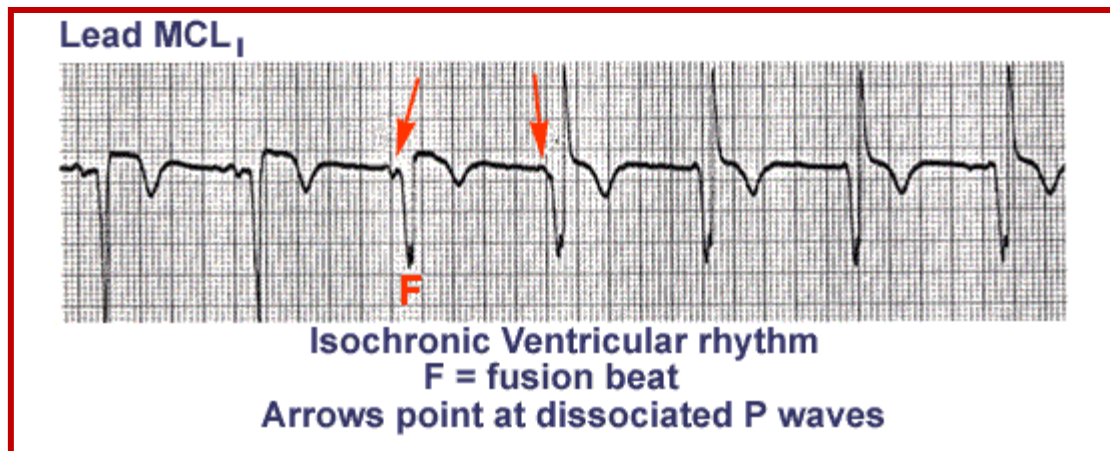
The ECG illustrated below shows another typical sustained monomorphic VT, but this time originating in the right ventricle. Note the V1 QRS morphology has all the features of a left ventricular VT origin (see Figure 5, p34) including 1) fat, little R wave; 2) notch on the downstroke or the S-wave; and 3) >0.06 s delay from QRS onset to the nadir (bottom) of the S-wave. The direction of QRS forces is leftward and posterior (i.e., coming from a rightward and anterior RV)



Right ventricular Tachycardia

Accelerated Ventricular Rhythms (see ECG below)

- An "active" ventricular rhythm due to enhanced automaticity of a ventricular pacemaker site (often seen after thrombolytics or PCI Rx in acute STEMI, an expression of gratitude to the interventional cardiologist; i.e., a benign reperfusion arrhythmia).
- Ventricular rate can be 60-99 bpm (anything faster would be ventricular tachycardia)
- Sometimes this is called an **isochronic ventricular rhythm** if the ventricular rate is not too different from the basic sinus rate (see next ECG strip).
- May begin and end with fusion beats (**F**), ventricular activation partly due to the normal sinus activation of the ventricles and partly from the ectopic ventricular focus).



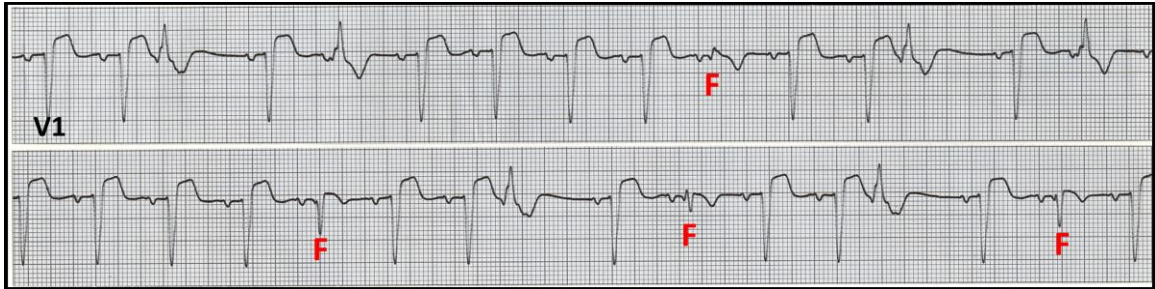
- Usually benign, short lasting and not requiring any particular antiarrhythmic therapy.

Idioventricular Rhythm (aka: Ventricular Escape Rhythm)

- A slow "passive" wide QRS rhythm that occurs by default whenever higher-level pacemakers in AV junction or sinus node fail to control ventricular activation.
- Ventricular escape rates are usually in the range of 30-50 bpm.
- Seen most often in 3rd degree AV block with AV dissociation or in other bradycardia conditions.
- The QRS morphology is clearly of ventricular origin (see Figures 4 and 5, p34).

Ventricular Parasystole

- Parasystolic PVCs come from protected ectopic pacemaker cells in the ventricles that fire at a fixed rate independent of the underlying basic rhythm (usually sinus). As a result they appear as PVCs with varying coupling intervals after the sinus beats, and, if late enough in the cardiac cycle they may fuse with the next sinus beat (fusion beats).
- These non-fixed coupled PVCs have inter-ectopic intervals (i.e., timing between PVCs) that are some multiple (i.e., 1x, 2x, 3x, ...etc.) of the basic rate of the parasystolic focus
- The PVCs have uniform morphology unless fusion beats occur
- There is usually an entrance block around the ectopic focus, which means that the primary rhythm (e.g., sinus rhythm) cannot enter the ectopic site and reset its timing (unlike a PAC that can reset the sinus pacemaker).
- May also see an intermittent exit block just distal to the parasystolic site; i.e., the output from the ectopic site may occasionally be blocked or non-conducted (i.e., no PVC occurs when one is expected).
- Fusion beats (**F**) are common when the ectopic site in the ventricle fires while ventricles are already beginning activation from sinus beats. In the next rhythm strip non-fixed coupled PVC's are seen with fusion beats (**F**). When the PVC occurs late enough in the sinus cycle they can partially fuse with the sinus beats. Note (with calipers) that the interval between parasystolic beats is constant or ~2x that interval.



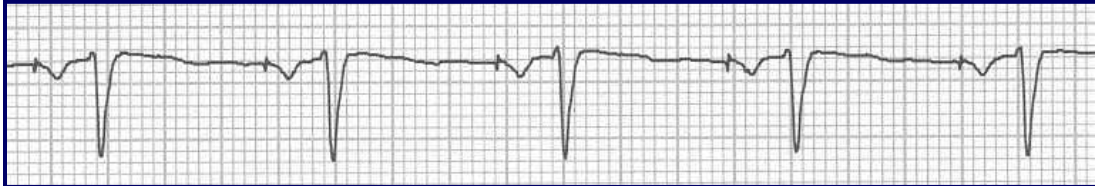Ventricular Parasystole

- Parasystolic rhythms may also originate in the atria (i.e., with non-fixed coupled PAC's) and within the AV junction (very rare).

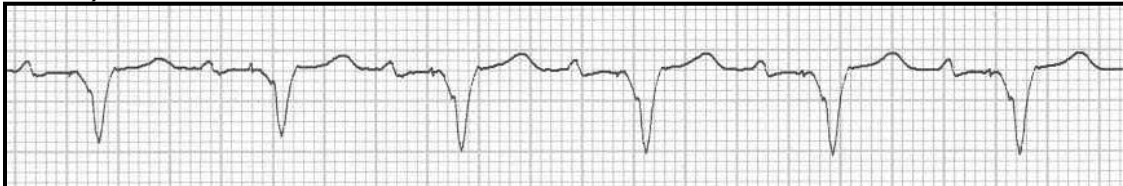Pacemaker Rhythms

- Pacemakers come in a wide variety of programmable features. The following ECG rhythm strips illustrate the common types of pacing functions.

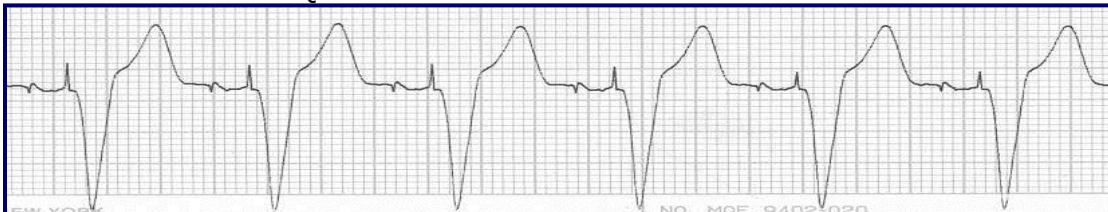- **Atrial pacing:** note small pacemaker spikes before every P wave followed by normal QRS complexes (used mostly for sinus node disease and related bradycardias)



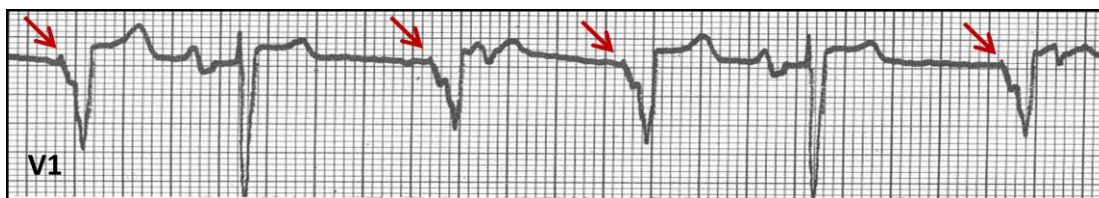
- **A-V sequential** pacing with ventricular pacing (note tiny spike before each QRS) and atrial *sensing* of normal sinus rhythm (note: pacemaker spikes are sometimes difficult to see):



- **A-V sequential** pacing with both atrial and ventricular pacing (note pacing spikes before each P wave and each QRS)



- Normal functioning ventricular **demand pacemaker**. Small pacing spikes (arrows) are seen before QRS #1, #3, #4, and #6 representing the paced beats. There is marked sinus bradycardia (that's the reason for the pacemaker), but when P waves are able to conduct they do (see QRS #2 and #5). This is also a nice example of incomplete AV dissociation due to sinus slowing where the artificial pacemaker takes over by default. Note also, in this V1 rhythm strip the morphology of the paced beats resemble QRS #2 in Figure 5 (p34) indicative of a RV ectopic pacemaker focus (note: notched downstroke).



Demand ventricular pacing (incomplete AV dissociation due to sinus slowing)

6. ECG CONDUCTION ABNORMALITIES

INTRODUCTION: This section considers all disorders of impulse conduction that may occur within the cardiac conduction system. Heart block can be conceptualized in terms of three cardiac *regions* where heart block can occur and three *degrees* of conduction failure in each region. The three regions of heart block include the sino-atrial connections (SA), the AV junction (AV Node and His Bundle), and the bundle branches including their fascicles. The three degrees include slowed conduction (**1st degree**), intermittent conduction failure (**2nd degree**), or complete conduction failure (**3rd degree**). In addition, there are two varieties of 2nd degree heart block: Type I (**Wenckebach**) occurring mostly in the Ca⁺⁺ channel cells of the AV node and Type II (**or Mobitz**) usually found in the Na⁺ channel cells of the His bundle, bundle branches and fascicles. In Type I (2nd degree) block **decremental conduction** is seen where the conduction velocity progressively slows beat-by-beat until failure of conduction occurs. This is the form of conduction block in the AV node. Type II block is **all or none** and is more likely to occur in the His bundle or in the bundle branches and fascicles. The term **exit block** is a special term used to identify a conduction delay or failure immediately distal to a pacemaker site. Sino-atrial (SA) block, for example, is an exit block. The table below summarizes the three degrees and three general locations of heart block.

Three Locations			
Three Degrees	Sino-Atrial	AV Junction: (AV Node, His Bundle)	Intraventricular
First (1°) Always conducts, but slower)	?	1° AV Block (PR >200 ms)	Incomplete RBBB Incomplete LBBB
Second (2°) Sometimes conducts, sometimes doesn't	2° SA Block	2° AV Block Type I (Wenckebach) Type II (Mobitz)	Type II (Mobitz)
Third (3°) Never conducts	?	3° AV Block	RBBB LBBB LAFB LPFB LSFB Bi- & Tri-fascicular Blocks Bilateral BBB

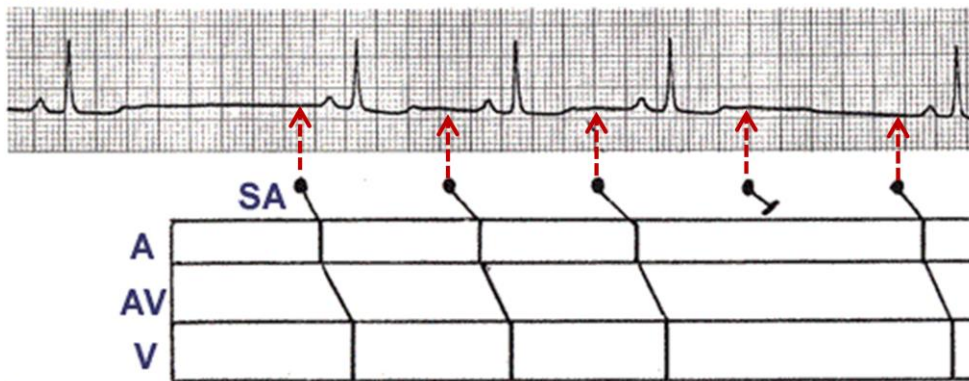
SINO-ATRIAL EXIT BLOCK (SA Block):

- **2nd Degree SA Block:** Although three degrees of SA block can occur only 2nd degree SA block can be recognized on the surface ECG because the sinus discharge doesn't appear on the surface ECG. (i.e., one can only 'see' an intermittent conduction failure between the sinus node and the right atrium). Two types of 2nd degree SA block have been

described but, unlike 2nd degree AV block, differentiating type I from type II is clinically unimportant. Also marked sinus arrhythmia may be confused with 2nd degree SA block.

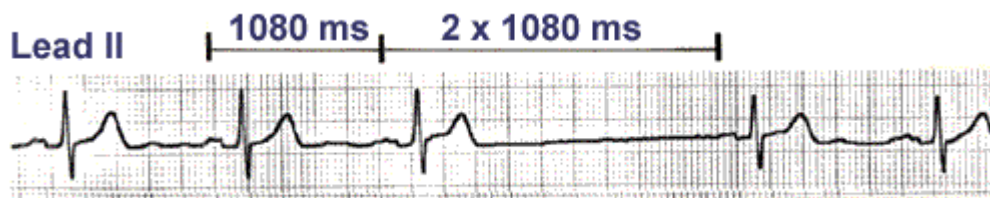
- **Type I SA block** (SA Wenckebach): the following 3 rules represent the classic rules of Wenckebach which were originally described for Type I 2nd degree **AV block**. The rules are the result of *decremental conduction* where the **increment** in conduction delay for each subsequent impulse gets smaller and smaller until conduction failure occurs. For Type I SA block (in the absence of sinus arrhythmia) the three rules are:
 1. PP intervals that gradually **shorten** until a pause occurs (i.e., when the blocked sinus impulse fails to reach the atria and the expected sinus P-wave is missing on the ECG).
 2. The PP interval of the pause is **less than** the two preceding PP intervals before the pause
 3. The PP interval just following the pause is **greater than** the PP interval just before the pause (not seen on the ECG example below). The dotted red arrows point to an *educated guess* as to when the sinus fired before each P wave. Note how it takes longer and longer to the P wave, and then a P wave doesn't appear.

Lead II



Sino-Atrial Exit Block (type I)

- **Differential Diagnosis:** marked sinus arrhythmia without SA block. The rhythm strip above illustrates SA Wenckebach with a ladder diagram to show the progressive conduction delay between SA node and the atrial P wave. Note the similarity of this rhythm to marked sinus arrhythmia. Note also that the PP interval of the pause is less than the 2 preceding PP intervals. Also remember: *the most common cause of an unexpected pause in rhythm is a nonconducted PAC* (see p19), not SA block.
- **Type II 2nd degree SA Block:**
 - PP intervals are fairly constant (unless sinus arrhythmia present) until conduction failure occurs.
 - The pause is approximately **twice** the basic PP interval



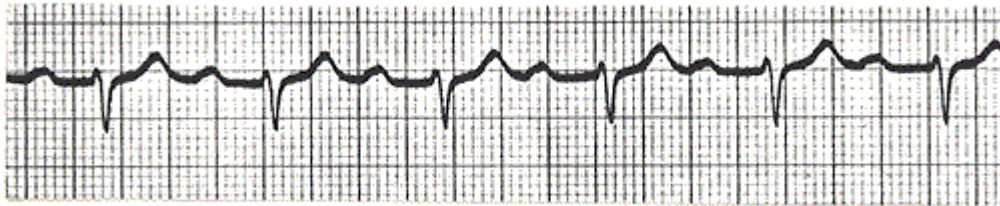
Sino-Atrial Exit Block (Type II)

- **Both** Type I and Type II SA block indicate sinus node disease (intrinsic or drug induced).

ATRIO-VENTRICULAR (AV) BLOCKS:

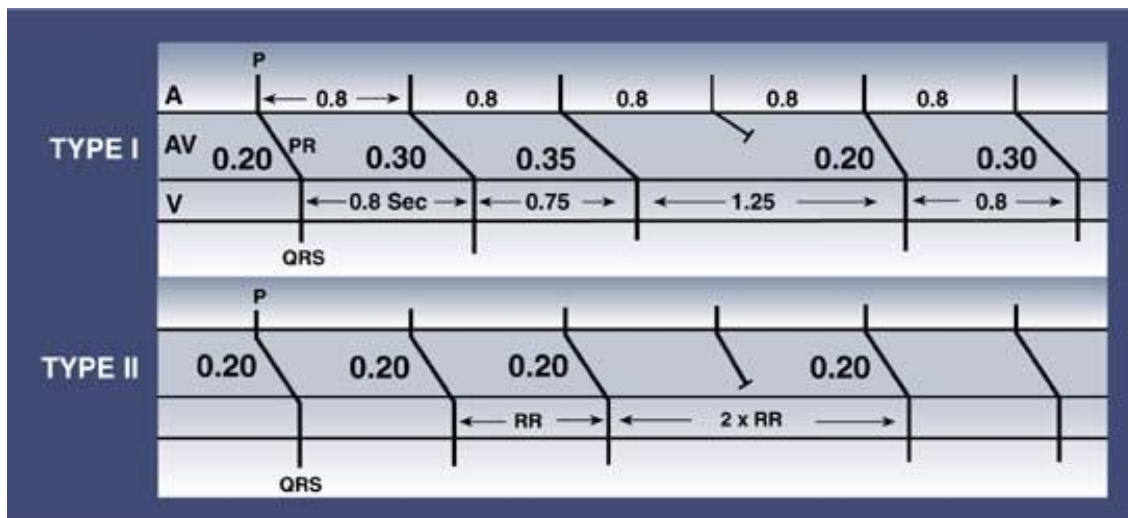
Possible sites of AV block:

- AV node (most common)
 - His bundle (uncommon)
 - Bundle branch and fascicular divisions (in presence of already existing bundle branch block)
- **1st Degree AV Block: PR interval > 200 ms; all P waves conduct and are followed by QRS complexes.**



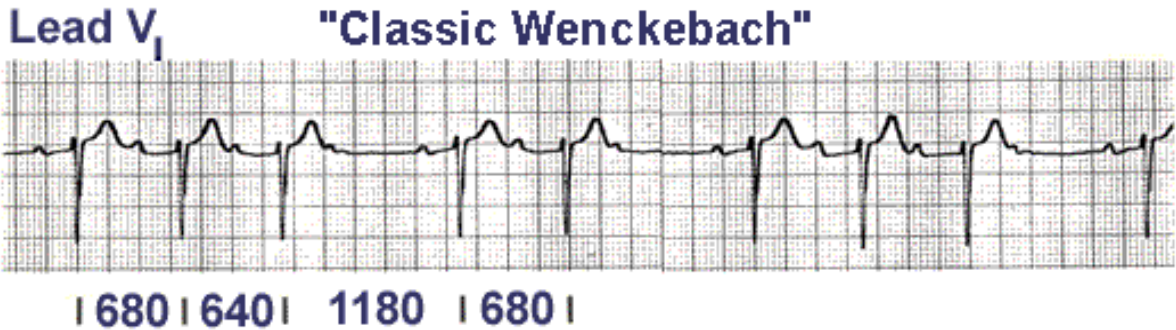
1st degree AV block (PR = 280 ms)

- **2nd Degree AV Block: The ladder diagrams below illustrate the differences between Type I (Wenckebach) and Type II 2nd degree AV block.**



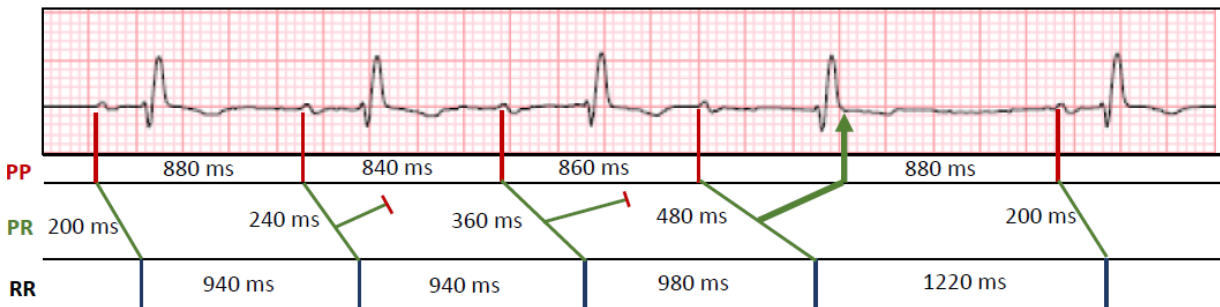
- In "classic" Type I (**Wenckebach**) AV block the PR interval gets longer and longer (**by smaller and smaller increments**) until a nonconducted P wave occurs. The RR interval of the pause is **less than** the two preceding RR intervals, and the RR interval after the pause is **longer than** the RR interval just before the pause. These are the 3 classic rules or "footprints" of **Wenckebach** (just described on p48 for the PP intervals in SA Wenckebach). In Type II (**Mobitz**) AV block the PR intervals are constant (**for at least 2 consecutive PR intervals**) until a nonconducted P wave occurs. The RR interval of the pause is **equal to** the two preceding RR intervals (assuming a regular sinus rate). In **2:1 AV block** one cannot distinguish type I from type II block (because PR is fixed in both cases). There are often other ECG clues to the correct 'type' in **2:1 AV block**:

- Wide QRS complexes (BBB's) suggest type II; narrow QRS complexes suggest type I.
- Prolonged PR intervals of the conducted beats suggest type I (Wenckebach)
- **Type I (Wenckebach) 2nd degree AV block (note the duration of RR intervals in ms illustrating the 3 classic rules):**

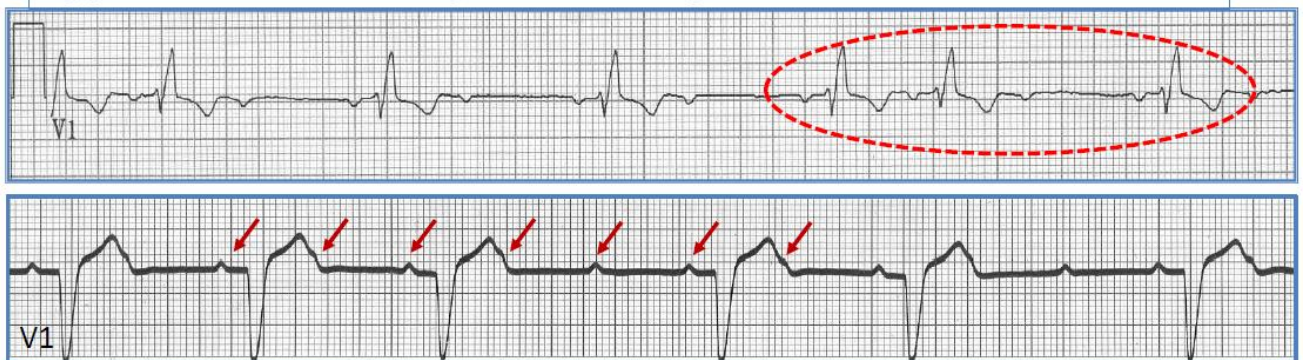

NOTE: Type I AV block is *almost always* located in the AV node itself, which means that the QRS duration is usually normal unless there is also a preexisting bundle branch block. Note also the 4:3 and 3:2 groupings of P's and QRS's; "group beating" is common in type I 2nd degree AV block.

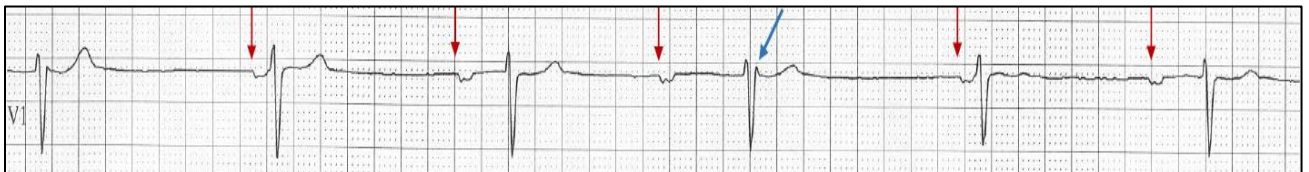
- **Atypical Wenckebach:** Below is an example where the classic footprints of Wenckebach don't apply because of partial and complete retrograde conduction. In this example the PR intervals are increasing by *increasing* increments until complete retrograde conduction (thick green arrow) into the atria **resets** the sinus (note the retrograde P wave is hidden in the QRS, but is inferred because the last sinus P wave has been reset). In other words the 2nd degree block is 'aborted' and the sinus never fails to conduct! (*Isn't that cool?*) Note also the RBBB.



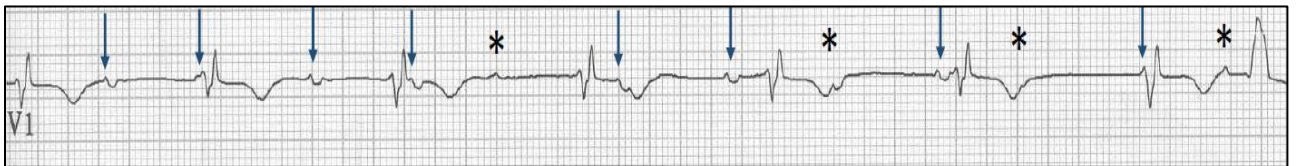
Type II (Mobitz) 2nd degree AV block: (2 examples)



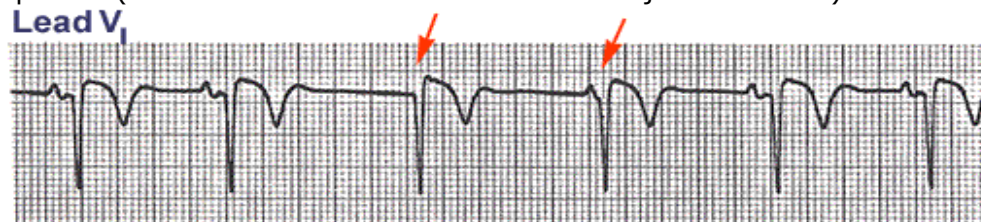- Above are two examples of type II 2nd degree AV block. In the top strip (RBBB) there is 3:2 and 2:1 AV conduction. Note that in the 3:2 grouping (red outline) the 2 conducted PR intervals are constant and have normal duration. In the lower strip (LBBB) there is 2:1 conduction and several longer RR intervals where multiple P waves are nonconducted, a characteristic of type II AV block that is **not** seen in type I (Wenckebach) 2nd degree AV block.
- **Complete (3rd Degree) AV Block:**
 - Usually there is **complete AV dissociation** because the atria and ventricles are each controlled by independent pacemakers.
 - Narrow QRS rhythms in 3rd degree AV block suggest a junctional escape focus indicating that the AV block is proximal to the bifurcation of the HIS bundle. In the strip below 3rd degree AV block is seen with a junctional escape rhythm. Note the dissociated sinus P waves (vertical red arrows). The slanted blue arrow shows a nonconducted PAC at the end of the QRS that resets the next sinus P wave.



- Wide QRS escape rhythms suggest a ventricular escape focus – often called an **idioventricular rhythm** or a **ventricular escape rhythm**. In the strip below, 3rd degree AV block is illustrated with a number in other interesting findings. The sinus rhythm is ~85 bpm (arrows), but it is often **reset** by nonconducted PAC's (*). The wide QRS rhythm (~48 bpm) is either a junctional escape rhythm with RBBB or a left ventricular escape rhythm. Complete AV dissociation is present. The last QRS is a PVC.

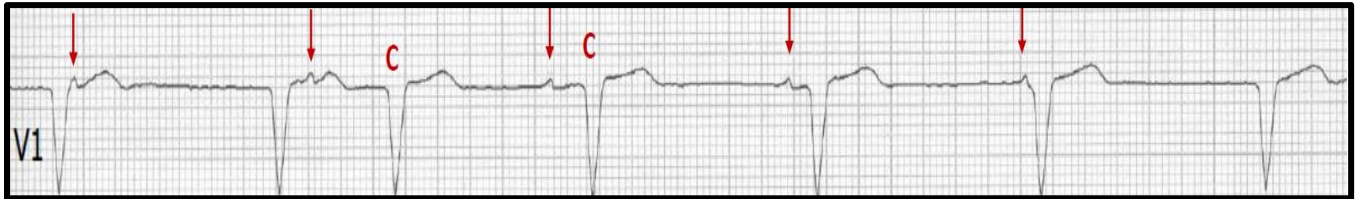

- **AV Dissociation (independent rhythms in atria and ventricles):**
 - Not synonymous with 3rd degree AV block, although AV block is one of the causes.
 - **Complete vs. incomplete:** In complete AV dissociation the atria and ventricles are always independent of each other as seen in 3rd degree AV block (see above). In incomplete AV dissociation there are opportunities for either intermittent *retrograde* atrial capture from the ventricles or *antegrade* ventricular capture from the atria.
 - There are **three categories** or situations where AV dissociation occurs (categories 1 & 2 are always **incomplete** AV dissociation):
 1. **Slowing** of the primary pacemaker (i.e., SA node); a subsidiary backup or **escape** pacemaker takes over by **default** because the sinus rate is slower than the escape pacemaker rate. In the following example of sinus arrhythmia two junctional beats (arrows) take over when the sinus rate falls below the junctional escape rate. (dissociated sinus P waves are hidden in the junctional beats)



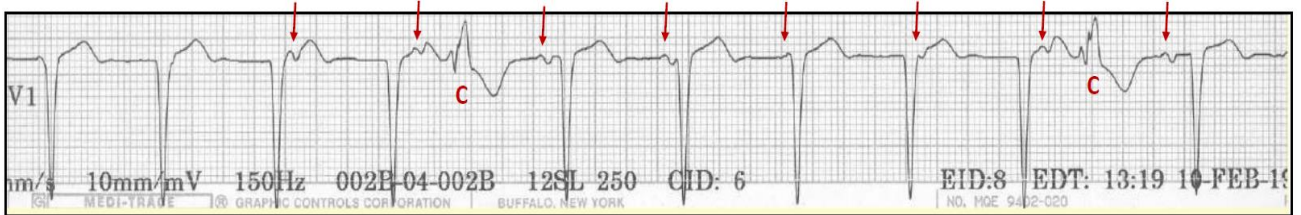Incomplete AV dissociation due to sinus slowing (default) with junctional escapes (arrows)

In the example below a *sick* sinus rhythm has slowed to ~35 bpm (arrows) and a junctional escape rhythm with LBBB (~40 bpm) has taken over. Two sinus captures (C) are identified by the shorter RR intervals (relative to the junctional escape interval). The first sinus capture has a long PR interval because the junction had just fired and the AV junction was somewhat refractory. The second sinus capture has a normal PR interval.



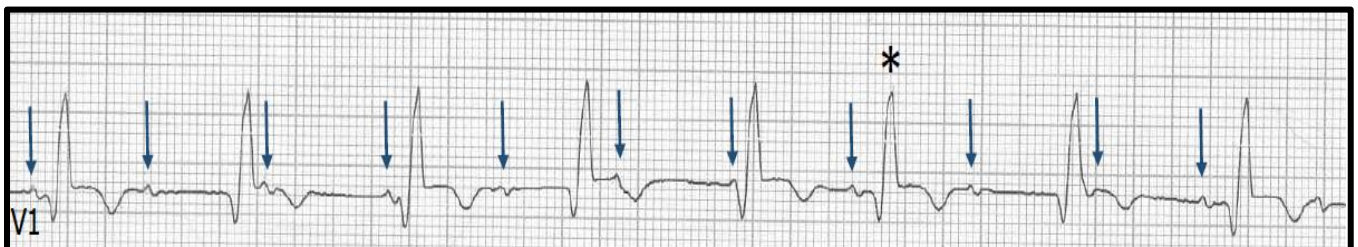Incomplete AV dissociation (by default)

2. Acceleration of a subsidiary pacemaker that is slightly faster than the normal basic sinus rhythm; i.e., takeover by **usurpation**. In the example below an accelerated junctional rhythm at approximately 80 bpm has taken over a slower (but normal) sinus rhythm (arrows) at 70 bpm. Two sinus captures are seen with RBBB aberrancy. The captured sinus beats (C) occur just following the junctional QRS and found the right bundle still refractory.



Incomplete AV dissociation (by usurpation)

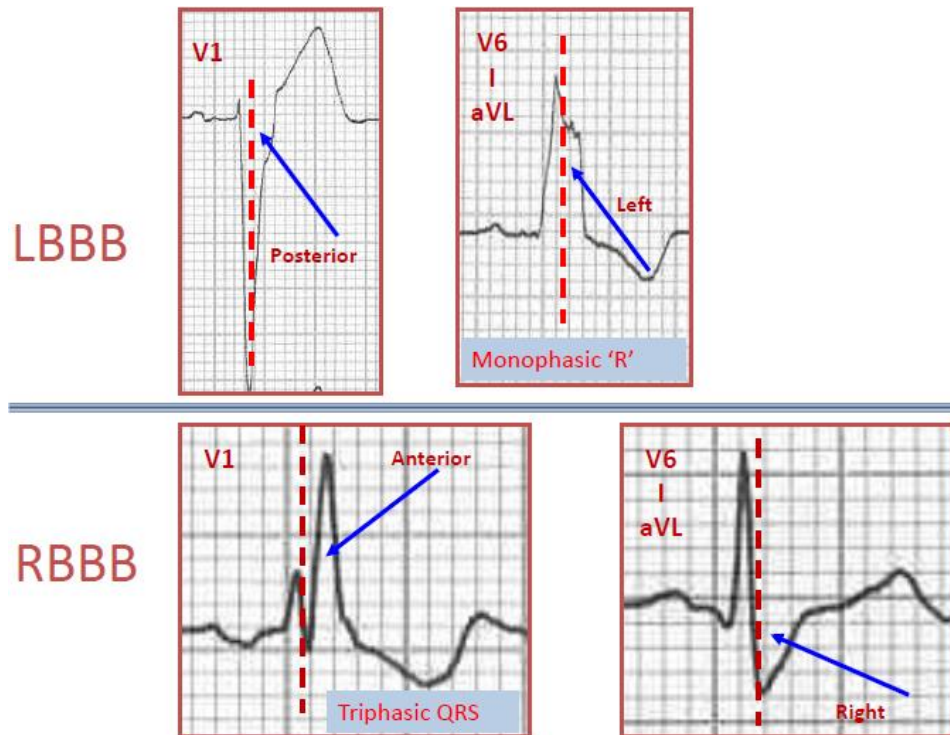
3. 2nd or 3rd degree AV block with an escape rhythm from a junctional or ventricular site: In the example below, high-grade 2nd degree AV block is present in a patient with a recent anteroseptal STEMI and RBBB. There is incomplete AV dissociation. The dissociated sinus P waves (~100 bpm) are indicated by the arrows, and the slightly accelerated junctional rhythm (~65-70 bpm) has taken over. The early QRS (*) is a sinus capture with RBBB. (The normal PR of the sinus capture suggests a type II 2nd degree AVB.)



Incomplete AV dissociation due to high-grade AV block

III. INTRAVENTRICULAR (IV) BLOCKS

Intraventricular blocks involve one or more portions of the IV conduction system including the bundle branches and their fascicles (see table on p47). 'Complete' or 3rd degree blocks of the bundle branches will be considered first. The QRS complexes in complete BBB will always be of wide duration (≥ 0.12 s) because the ventricles are depolarized *sequentially* rather than *simultaneously* as in normal ventricular activation. The ventricle with the blocked bundle will affect the 2nd half of the widened QRS. Remember, the right ventricle sits to the *right* of and *anterior* to the left ventricle; the left ventricle is to the *left* of and *posterior* to the right ventricle. ECG leads that best reflect right vs. left and anterior vs. posterior are illustrated below:

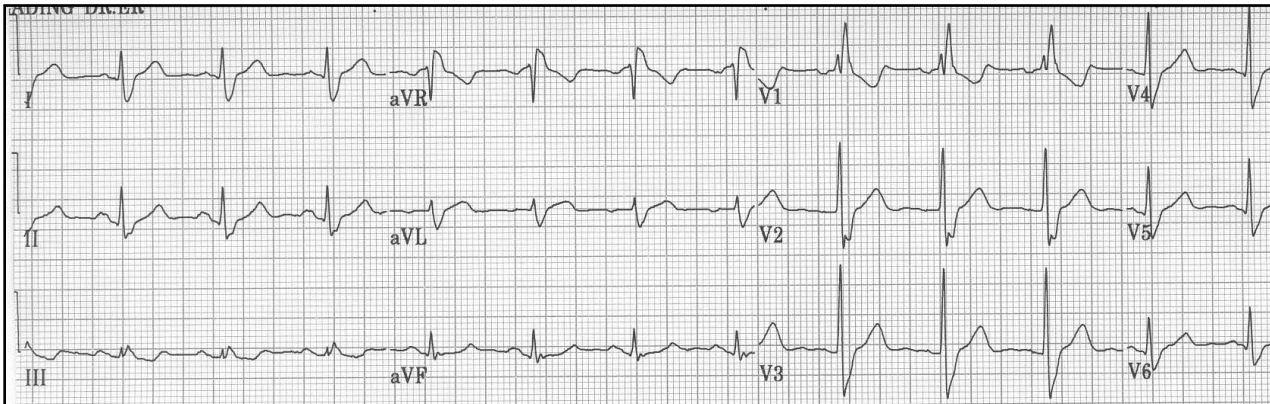


First, consider left bundle branch block (LBBB) in the above figure. The vertical dotted lines divide the QRS into two parts with the 2nd half representing the activation of the ventricle with the blocked bundle branch. Since the left ventricle is to the left and posterior to the right ventricle the 2nd half of the QRS is downgoing in lead V1 (posterior) and upgoing in leads I, aVL, and V6 (leftward). Similarly in right bundle branch block (RBBB) the 2nd half of the QRS is upgoing in lead V1 (anterior), and downgoing in leads I, aVL, and V6 (rightward). Note also the first part of each QRS in BBB moves more quickly than the 2nd part because activation of the ventricle with the intact bundle branch proceeds normally through the bundle branch and subsequent Purkinje network. Activation of the ventricle with the blocked bundle is slower because of the aberrant nature of the activation sequence.

Now let's consider the 12-lead ECG's of complete BBB.

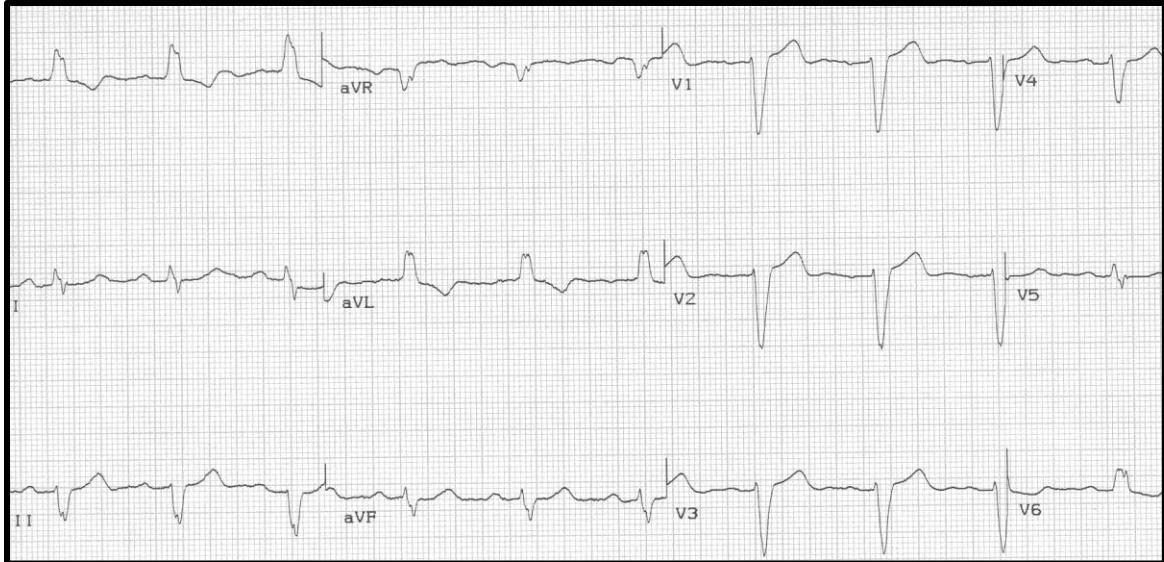
- **Right Bundle Branch Block (RBBB):**
 - "Complete" RBBB has a QRS duration ≥ 0.12 s (120 ms)
 - Close examination of QRS complex in various leads reveals that the late forces (i.e., 2nd half of each QRS) are directed rightward and anterior because the right ventricle is depolarized **after** the left ventricle in RBBB.

- Terminal R' wave in lead V1 (usually see rSR' complex) indicating late **anterior** forces (in uncomplicated RBBB the R' in V1 should always be taller than the initial r wave)
- Terminal S waves in leads I, aVL, V6 indicating late **rightward** forces
- Terminal R wave in lead aVR also indicating late **rightward** forces



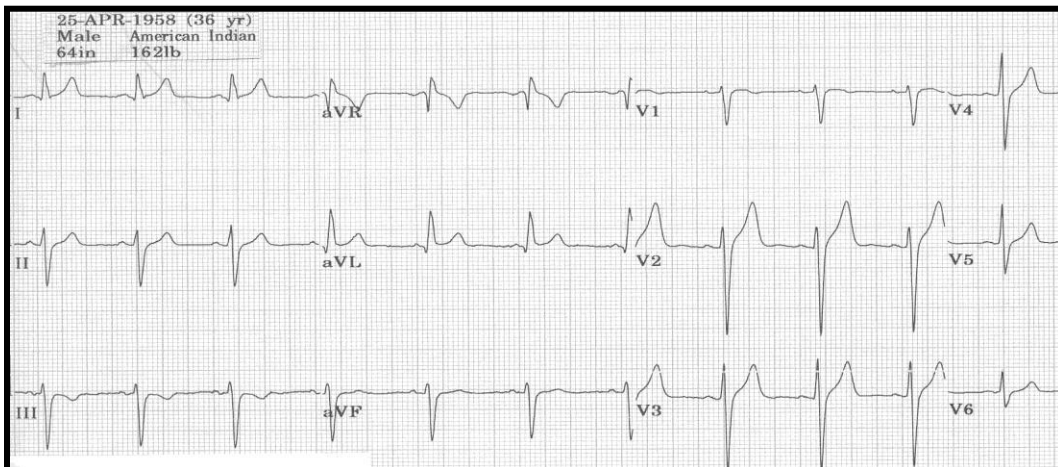
RBBB

- The frontal plane QRS axis in RBBB is usually in the normal range (i.e., -30 to +90 degrees). If left axis deviation is present, one must also consider **left anterior fascicular block**, and if right axis deviation is present, one must consider **left posterior fascicular block** in addition to the RBBB (i.e., bifascicular block). ECG criteria for the fascicular blocks are discussed later. (pp55-57)
- "Incomplete" RBBB has a QRS duration of 100-120 ms with the same 2nd half QRS features. This may be a normal variant, but could be seen in people with slowed (1st degree or slowed conduction in the RBB)
- The "normal" ST-T wave morphology in RBBB is oriented opposite to the direction of the late QRS forces or last half of the QRS; i.e., in leads with terminal R or R' forces (e.g., V1) the ST-T should be downwards (negative); in leads with late S forces (e.g., I, V6) the ST-T should be positive. If the ST-T waves are in the **same direction** as the terminal QRS forces, they should be labeled **primary ST-T wave abnormalities** because they may be related to other conditions affecting ST-T wave morphology (e.g., ischemia, drug effects, electrolyte abnormalities)
- **Left Bundle Branch Block (LBBB)**
 - "Complete" LBBB" has a QRS duration ≥ 140 ms (men) and ≥ 130 ms (women)
 - Close examination of wide QRS complex (see next ECG) in various leads reveals that the late forces (i.e., 2nd half of QRS) are oriented leftward and posterior because the left ventricle is depolarized later **after** the right ventricle.
 - Late S waves in lead V1 indicating late **posterior** forces
 - Late R waves in lead I, aVL, V6 indicating late **leftward forces**.
 - Mid-QRS notching or slurring should be seen in 2 or more leads. (Wide QRS complexes resembling LBBB but without the notching or slurs represent *nonspecific* IVCDs often in the setting of severe LVH)
 - QRS complexes in leads I, aVL, and V6 are **monophasic** meaning that there should not be initial q-waves or terminal s-waves in these leads (just wide R-waves with mid-QRS notches or slurs). The presence of q-waves and/or s-waves in these leads may indicate scarred LV areas from old myocardial infarctions (or nonspecific IVCD's).



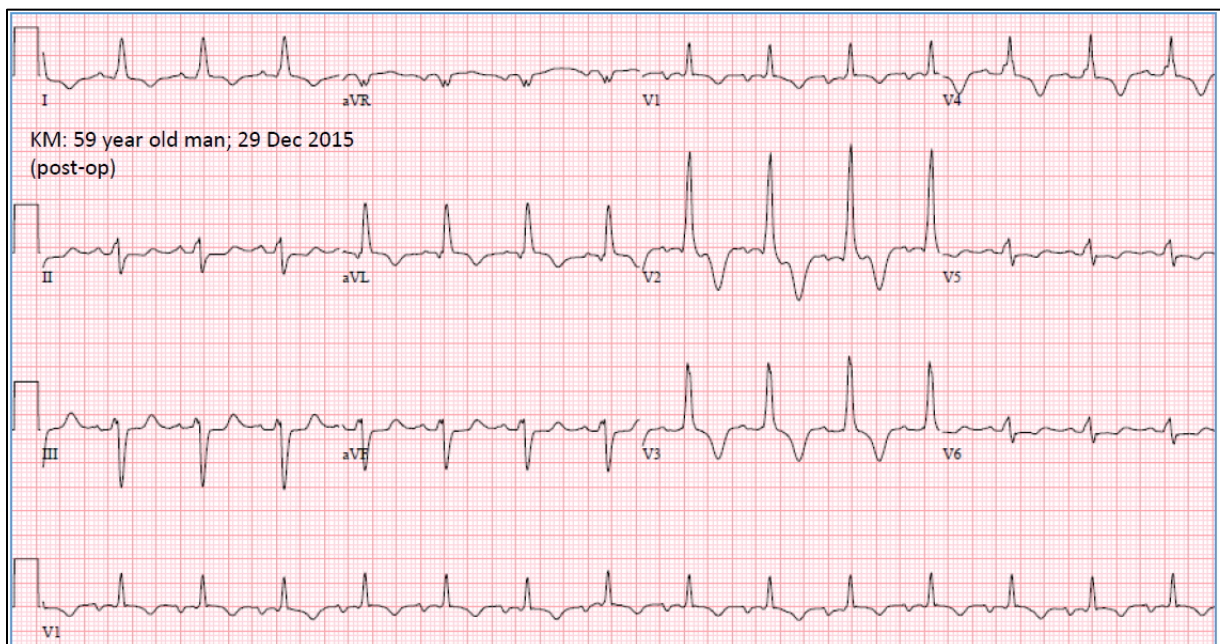
LBBB

- The "normal" ST-T waves in LBBB should be oriented opposite to the direction of the terminal QRS forces; i.e., in leads with terminal R or R' forces the ST-T should be downwards (negative) (see I, aVL); in leads with terminal S forces the ST-T should be upwards (positive) (see III, V1-3). If the ST-T waves are in the **same direction** as the terminal QRS forces, they should be labeled **primary ST-T wave abnormalities**. In the above ECG the ST-T waves are "normal" for LBBB; i.e., they are **secondary** to the change in the ventricular depolarization sequence.
- "Incomplete" LBBB looks like LBBB but QRS duration is 100-130 ms with less ST-T change. This is often the result of long standing LVH or slowed LBBB conduction (1st degree block).
- **Left Anterior Fascicular Block (LAFB)..... the most common intraventricular conduction defect (IVCD)**
 - Left axis deviation in frontal plane, usually -45 to -90 degrees
 - rS complexes in leads II, III, aVF (i.e., small initial r, large S)
 - S in III > S in II; R in aVL > R in aVR
 - Small q-wave in leads I **and/or** aVL
 - R-peak time in lead aVL >40 ms, often with slurred R wave downstroke
 - QRS duration usually <120 ms unless coexisting RBBB
 - Usually see poor R progression in leads V1-V3 and deeper S waves in leads V5 and V6
 - May **mimic** LVH voltage in lead aVL, and **mask** LVH voltage in leads V5, V6



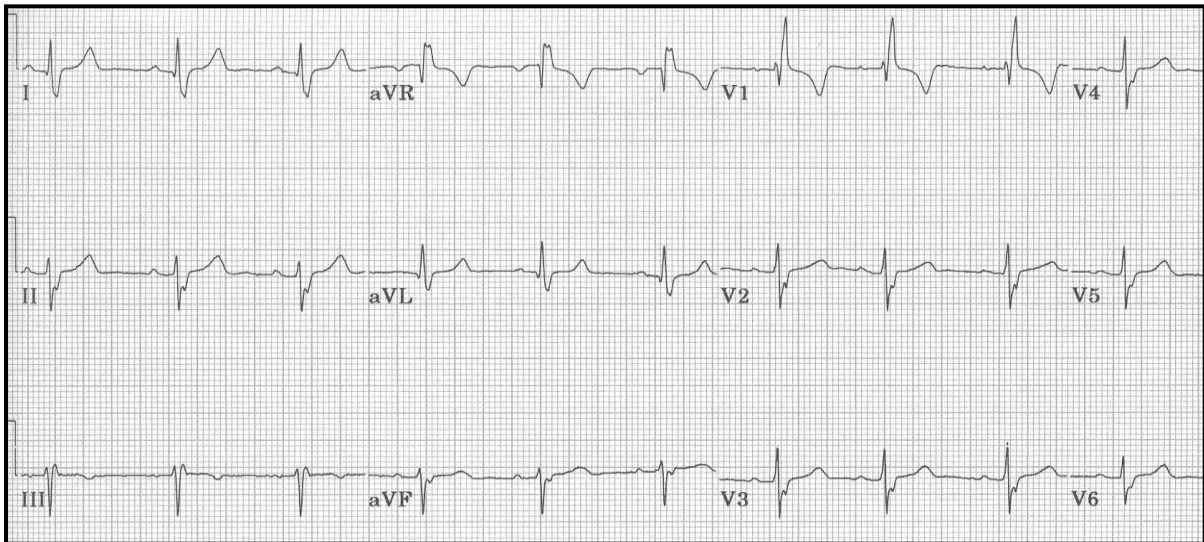
In the above ECG, note -45° QRS axis, rS complexes in II, III, aVF, tiny q-wave in I, aVL, S in III $>$ S in II, R in aVL $>$ R in aVR, and late S waves in leads V5-6. QRS duration is normal, and there is a slight slur to the R wave downstroke in lead aVL. **This is classic LAFB!**

- **Left Posterior Fascicular Block (LPFB).... Very rare IVCD !**
 - Right axis deviation in the frontal plane (usually $> +100^\circ$)
 - rS complex in lead I, aVL
 - qR complexes in leads II, III, aVF, with R in lead III $>$ R in lead II
 - Notch (or slur) in descending limb of R in lead III
 - q-wave III $>$ q-wave in II or aVF
 - QRS duration usually $<$ 120 ms unless coexisting RBBB
 - **Must first exclude (on clinical information or imaging) other causes of right axis deviation including vertical heart (ectomorphic biotype), right heart disease, pulmonary hypertension, large lateral wall MI, etc. because these conditions can result in right axis deviation!**
- **Left Septal Fascicular Block (LSFB):** This 'new' and somewhat controversial ECG diagnosis has recently become a credible entity as there is increasing anatomical evidence that the left bundle often has three divisions (rather than the usual two) that simultaneously initiate left ventricular activation in three distinct areas. The following ECG criteria have been proposed (Perez Riera et al *Ann of Noninvasive Electrocardiol* 2011; 16:196).
 - QRS duration up to 110 ms
 - Normal frontal plane QRS axis (unless additional LAFB or LPFB)
 - Prominent anterior forces (PAF)
 - R wave voltage in V1 $>$ 5 mm)
 - R/S ratio V1-2 $>$ 2
 - R wave voltage V2 $>$ 15 mm
 - Intermittent PAF in setting of ischemia (acute MI or positive stress test)
 - Transient PAF in an aberrantly conducted PAC
 - Small q-waves V1-2, or V2-3
 - Absence of q-waves in left precordial leads



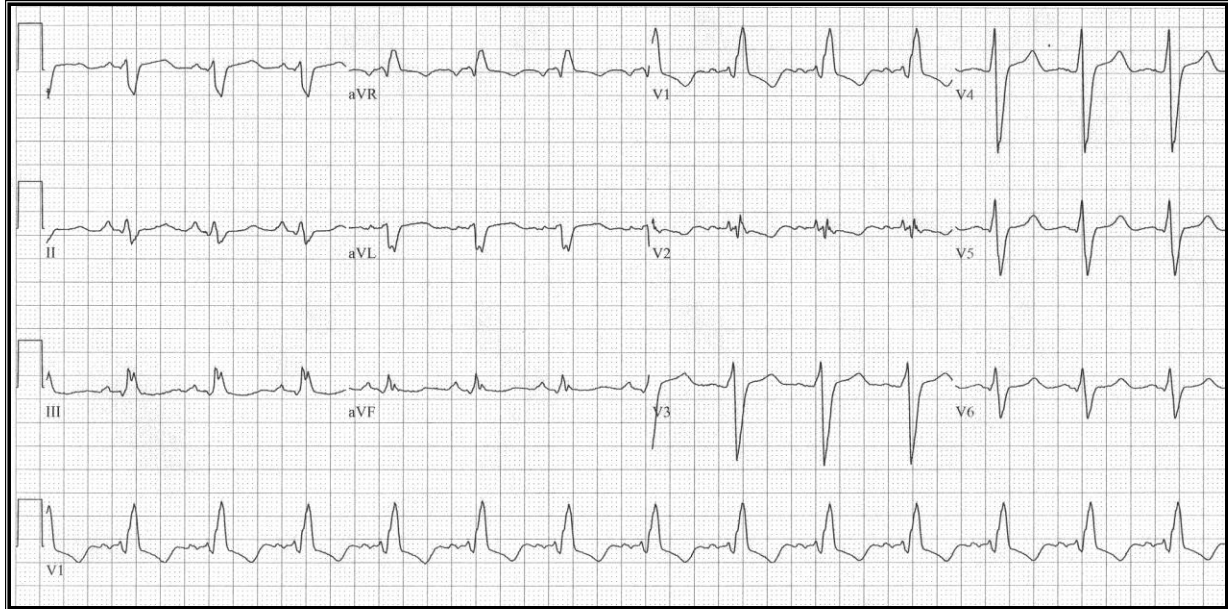
New onset **LSFB** immediately following CABG (severe L-main and LAD disease). The prominent anterior forces (PAF) were not present in prior ECGs from this patient.

- Differential diagnosis of prominent anterior forces (PAF) in right precordial leads
 - Normal variant
 - Misplaced precordial leads
 - Left septal fascicular block (see above example)
 - RVH
 - RBBB and incomplete RBBB
 - Lateral (dorsal) myocardial infarction (formally called 'true-posterior' MI)
 - WPW preexcitation (Type 'A')
- **Bifascicular Blocks**
 - RBBB plus either LAFB (common) *or* LPFB (uncommon) *or* LSFB (very uncommon)
 - Features of RBBB plus frontal plane features of the fascicular block (frontal plane axis deviation, prominent anterior forces, etc.)
 - The ECG below shows classic RBBB (note rsR' in V1) *plus* LAFB (QRS axis = - 60°, rS in II, aVF; and small q in I and aVL).
 - Bifascicular blocks are clinically important precursors of complete (3rd degree) AV block. Before 3rd degree block occurs there may be episodes of type II 2nd degree AV block (**Mobitz**) indicating intermittent block in the remaining fascicle. These episodes often cause symptoms of syncope or presyncope and indicate need for a pacemaker.



RBBB + LAFB (bifascicular Block)

- The ECG shown next is classic RBBB and LPFB (bifascicular block) in a patient with chronic heart failure. Note the unusual frontal plane QRS axis of +150° (isoelectric lead II), the rS complex in lead I, and the small q-waves in II, III, aVF. There is rsR' in V1 indicative of RBBB.



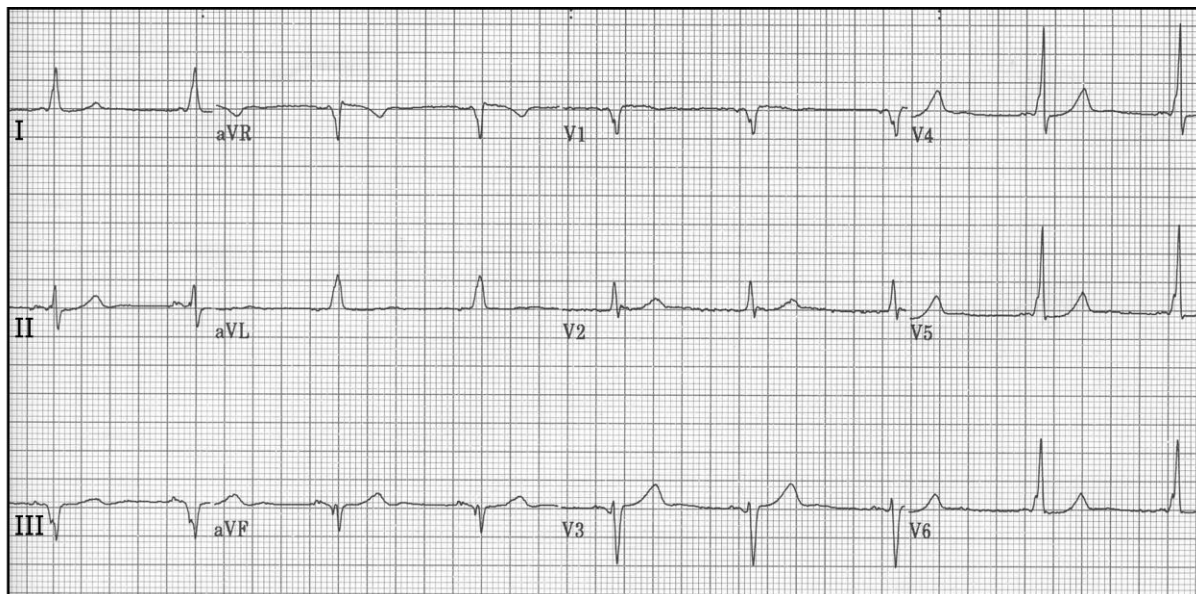
RBBB + LPFB (bifascicular block)

- **Nonspecific Intraventricular Conduction Defects (IVCD)**
 - QRS duration >0.10s indicating slowed conduction in the ventricles
 - Criteria for specific bundle branch or fascicular blocks are not present
 - Causes of nonspecific IVCD's include:
 - Ventricular hypertrophy (especially LVH)
 - Myocardial infarction (so called *peri-infarction blocks*)
 - Drugs, especially class IA and IC antiarrhythmics (e.g., quinidine, flecainide)
 - Severe hyperkalemia
- **Incomplete Bundle Branch Blocks**
 - Incomplete RBBB and LBBB are comparable to 1st degree blocks elsewhere in the conduction system, namely slowed conduction rather than interrupted conduction. Incomplete RBBB looks like complete RBBB but with QRS duration 100-120 ms. Similarly incomplete LBBB looks like complete LBBB with QRS durations 100-130 ms with monophasic R waves in at least two of three leads (I, aVL, V6). This is often seen in severe LVH.

Wolff-Parkinson-White (WPW) Preexcitation

- Although not a true IVCD, this entity is associated with wider QRS complexes and, therefore, deserves to be considered here.
 - The wider QRS complex represents a *fusion* between *two* ventricular activation fronts:
 - Early ventricular activation in the region of the accessory AV pathway (***Bundle of Kent***). This is illustrated in the diagram on p14.
 - Ventricular activation through the normal AV junction, bundle branch system
 - ECG criteria include all of the following:
 - Short PR interval (<120 ms) due to early ventricular activation the accessory pathway
 - Initial slurring of QRS complex (***delta wave***) representing early ventricular activation into ventricular muscle in the region of the accessory pathway
 - Delta waves, if negative in polarity (see lead III, aVF, and V1 below), may mimic infarct Q waves and result in a false positive diagnosis of myocardial infarction.

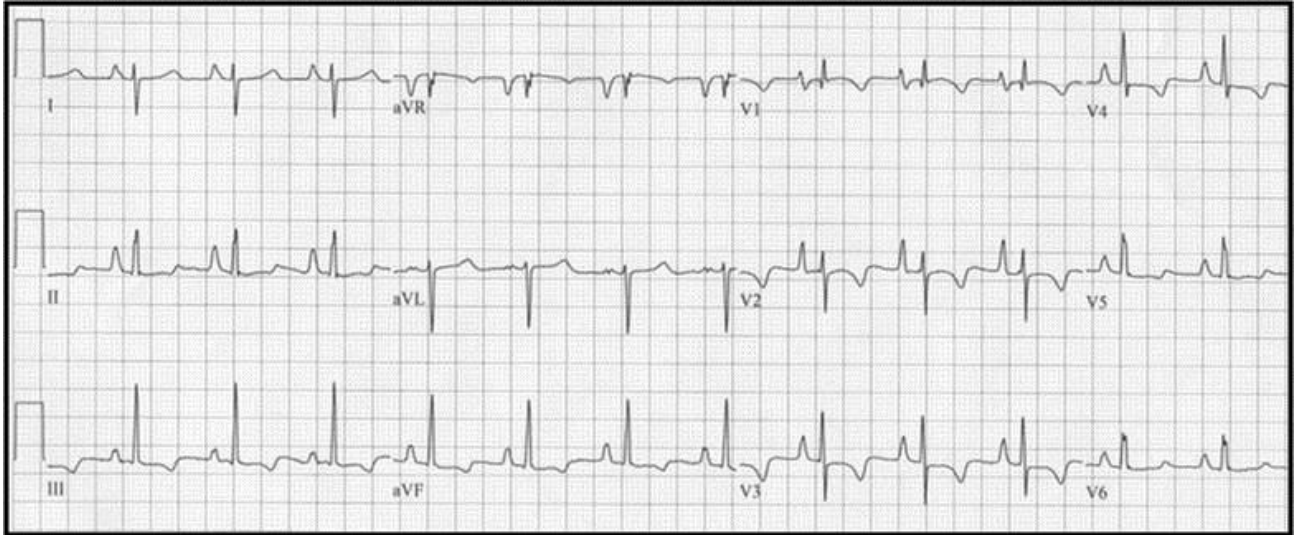
- Prolonged QRS duration (usually >100 ms)
- Secondary ST-T changes due to the altered ventricular activation sequence
- QRS morphology, including polarity of delta wave depends on the particular location of the accessory pathway as well as on the relative proportion of the QRS complex that is due to early ventricular activation (i.e., degree of fusion).
- The accessory pathway enables episodes of **PSVT** to occur (reentrant supraventricular tachycardias, AVRT).



WPW Preexcitation (note short PR and delta waves best seen in I, V5-6)

7. ATRIAL ABNORMALITIES

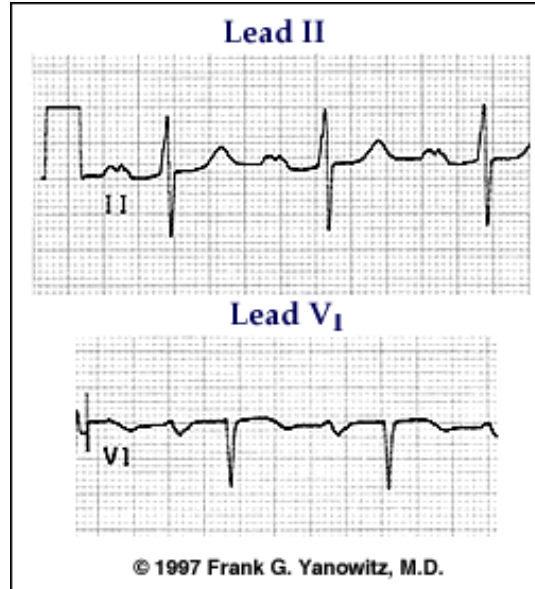
- **Right Atrial Enlargement (RAE, P-pulmonale, "Viagra P-waves")**
 - P wave amplitude >2.5 mm in II and/or >1.5 mm in V1 (these criteria are not very specific or sensitive)
 - Frontal plane P-wave axis $\geq 90^\circ$ (isoelectric in lead I)
 - Better criteria can be derived from the QRS complex; these QRS changes are due to both the high incidence of RVH when RAE is present, and the RV displacement by an enlarged right atrium.
 - QR, Qr, qR, or qRs morphology in lead V1 (in absence of coronary heart disease)
 - QRS voltage in V1 <5 mm and V2/V1 voltage ratio is >6 (Sensitivity = 50%; Specificity = 90%)
 - Why are these P waves (see lead II below) sometimes called "Viagra P-waves"?



RAE: note also RAD ($+110^\circ$) and qR complex in V1 indicative of RVH (36 year old man with primary pulmonary hypertension)

- **Left Atrial Enlargement (LAE. P-mitrale)**

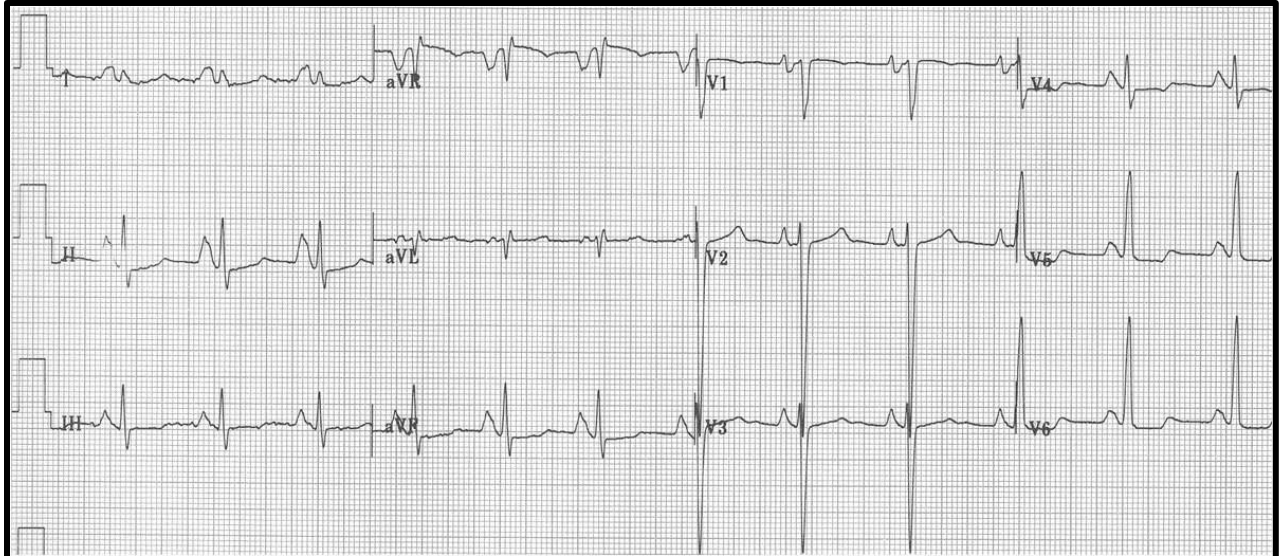
- P wave duration ≥ 120 ms in frontal plane (usually lead II)
- Notched P wave in limb leads with interpeak duration ≥ 40 ms.
- Terminal P negativity in lead V1 (i.e., "P-terminal force") duration ≥ 40 ms, depth ≥ 1 mm (i.e., area ≥ 1 small box)
- Sensitivity = 50%; Specificity = 90%



Classic LAE in lead II and V1 (with 1st degree AV block)

- **Bi-Atrial Enlargement (BAE)**

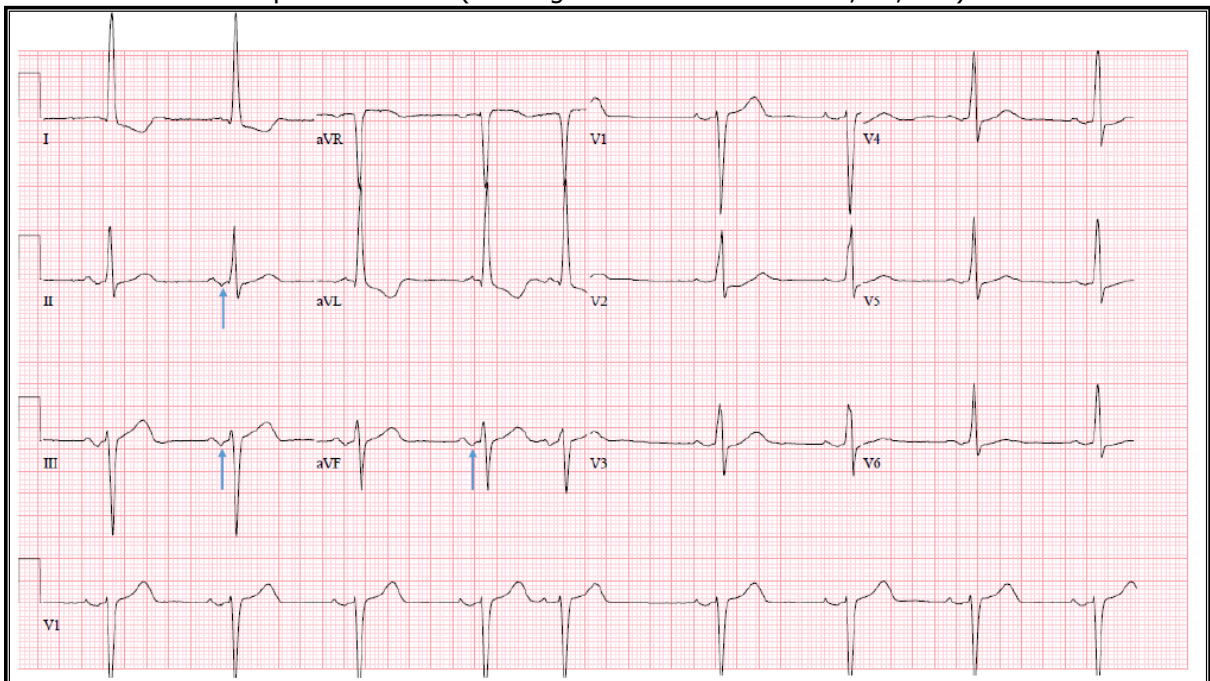
- Features of both RAE and LAE in same ECG
- P wave in lead II > 2.5 mm tall and > 120 ms in duration
- Initial positive component of P wave in V1 > 1.5 mm tall and prominent P-terminal force



Bi-Atrial Enlargement with LVH

Interatrial block

- When the P wave duration is >0.12 ms, one should consider slowed or blocked conduction through the right and/or left atrium. An unusual manifestation of advanced interatrial block resulting from block in Bachman's bundle (connecting right and left atrium) has been described, called '*Bayes' Syndrome*'. These patients have increased risk for atrial fibrillation. The ECG below illustrates this block. (Note arrows pointing to late left atrial activation in a superior direction (late negative P wave forces in II, III, aVF).



Advanced interatrial block. Note the prolonged, biphasic (+/-) P wave in the inferior leads indicating late superior direction of atrial direction into the left atrium. LVH is also present.

8. VENTRICULAR HYPERTROPHY

Introduction:

- The ECG criteria for diagnosing right or left ventricular hypertrophy are very insensitive (i.e., sensitivity ~50%, which means that ~50% of patients who have ventricular hypertrophy cannot be diagnosed by ECG criteria). When in doubt....**Get an ECHO!** However, the criteria are very specific (i.e., specificity >90%, which means if the ECG criteria are met, it is very likely that ventricular hypertrophy is present).

I. Left Ventricular Hypertrophy (LVH)

- General ECG features include:
 - QRS amplitude: voltage criteria; i.e., tall R-waves in left leads (I, aVL, V5-6), deep S-waves in right precordial leads (V1-3).
 - Delayed **intrinsicoid deflection** in V5 or V6 (i.e., the time from QRS onset to peak R is ≥ 50 ms)
 - Widened QRS/T angle (i.e., *left ventricular strain pattern* or ST-T waves oriented opposite to QRS direction). This pattern is more common with LVH due to pressure overload (e.g., aortic stenosis, systemic hypertension) rather than volume overload.
 - Leftward shift in frontal plane QRS axis (not necessarily in LAD territory)
 - Evidence for left atrial enlargement (LAE)

Specific criteria for LVH:

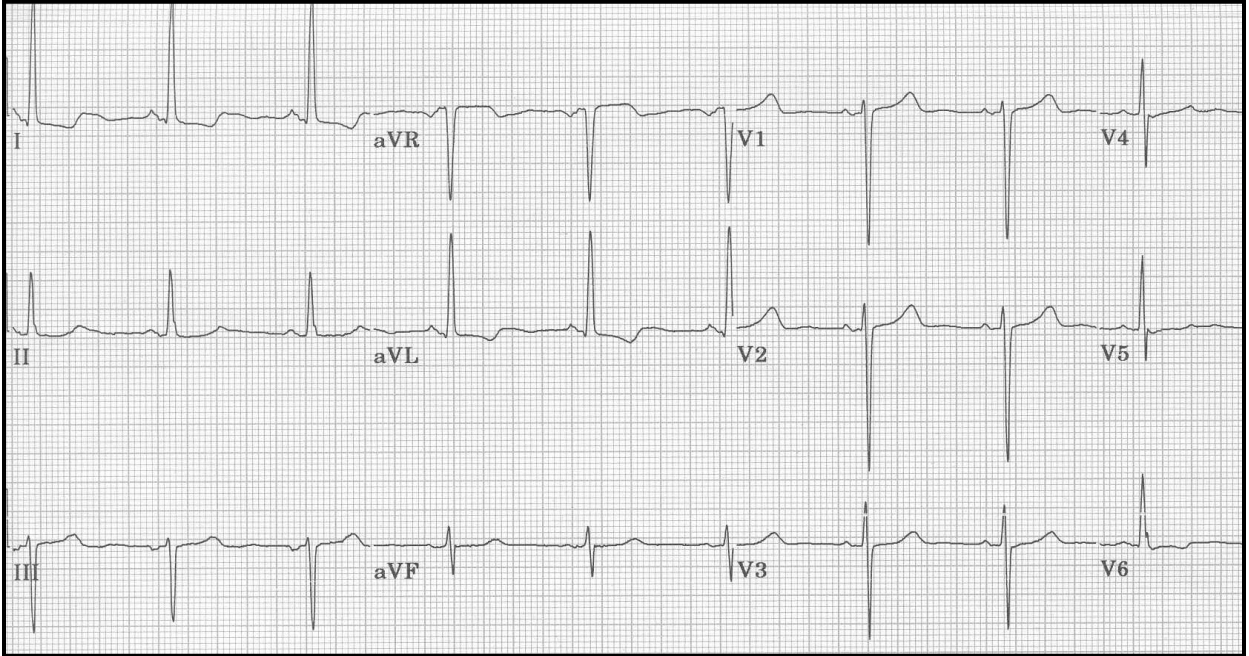
ROMHILT-ESTES Criteria for LVH ("definite" ≥ 5 points; "probable" 4 points)

ECG Criteria	Points
<u>Voltage Criteria (any of):</u> a. R or S in limb leads ≥ 20 mm b. S in V1 or V2 ≥ 30 mm c. R in V5 or V6 ≥ 30 mm	3 points
<u>ST-T Abnormalities:</u> On digitalis Rx Not on digitalis Rx	1 point 3 points
Left Atrial Enlargement in V1	3 points
Left axis deviation $\geq -30^\circ$	2 points
QRS duration ≥ 90 ms	1 point
Delayed intrinsicoid deflection in V5 or V6 (≥ 50 ms)	1 point

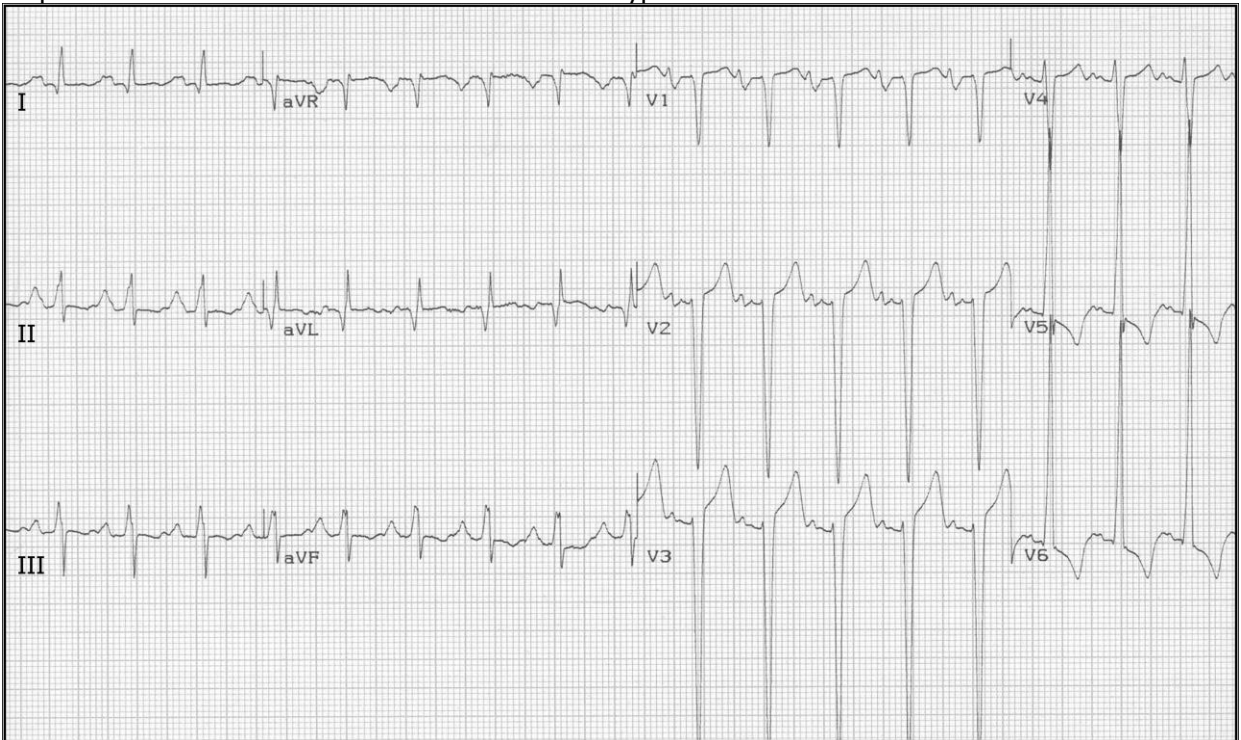- CORNELL** Voltage Criteria for LVH, assuming correct precordial lead placement (sensitivity = 42%, specificity = 95%)
 - S in V3 + R in aVL > 28 mm (men)
 - S in V3 + R in aVL > 20 mm (women)
- Other Voltage Criteria for LVH (note that voltage criteria alone can't make a "definite" ECG diagnosis of LVH)
 - Limb-lead voltage criteria:
 - R in aVL ≥ 11 mm or, if left axis deviation, R in aVL ≥ 18 mm
 - R in I + S in III > 25 mm
 - R in aVF > 20 mm
 - S in aVR > 14 mm
 - Chest-lead voltage criteria:
 - S in V1 + R in V5 or V6 ≥ 35 mm
 - R + S in any leads > 45 mm

- **New** (Peguero-Lo Presti criteria): Largest S (S_D) + S_{V4} >22 mm (women) or >27 (men) *JACC* 2017; 69:1694 (sensitivity 62%; specificity >90%)

Example 1: (Limb-lead Voltage Criteria; e.g., R in aVL >11 mm, or R in I + S in III > 25 mm; note downsloping ST segment depression in leads I and aVL). Note also: $S_D + S_{V4} = 33$ mm



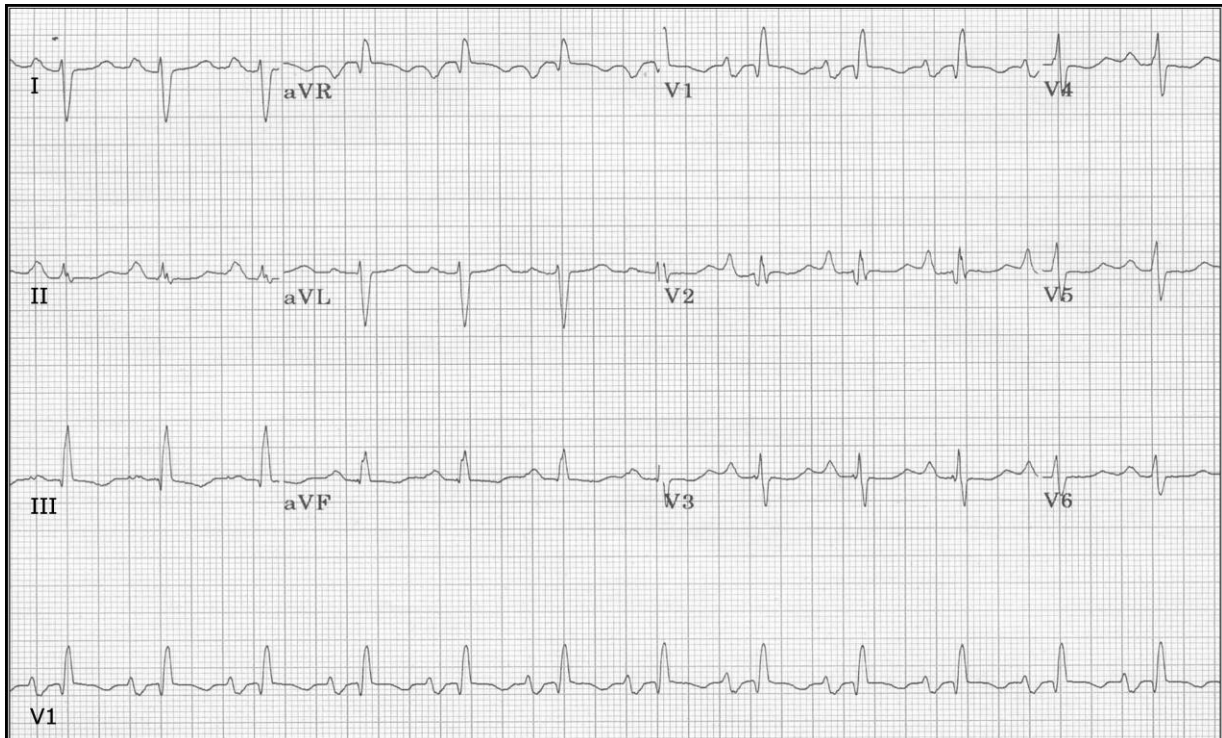
Example 2: (ROMHILT-ESTES Criteria: 3 points for precordial lead voltage, 3 points for ST-T changes; also LAE (possibly bi-atrial enlargement)). This pattern is classic for LVH due to severe LV pressure overload as seen in aortic stenosis and hypertensive heart disease.



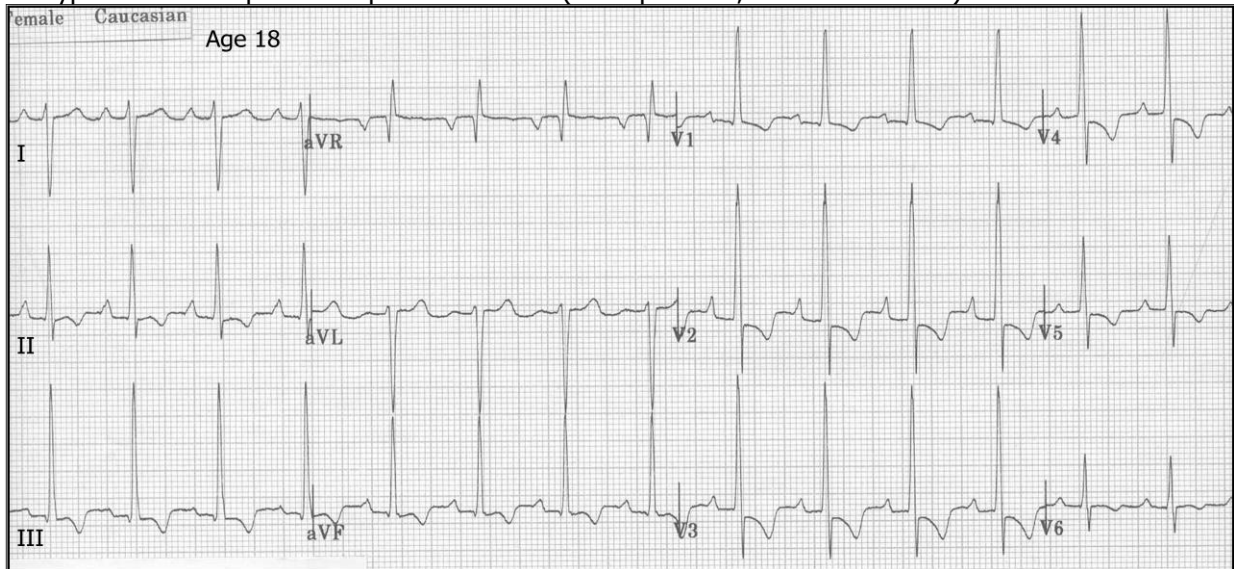
II. Right Ventricular Hypertrophy

- General ECG features include:
 - Right axis deviation ($>90^\circ$) in frontal plane
 - Tall R-waves in RV leads (V1-2); deep S-waves in LV leads (V5-6)
 - Slight increase in QRS duration
 - ST-T changes directed opposite to QRS direction (i.e., wide QRS/T angle)
 - May see incomplete RBBB pattern or qR pattern in V1
 - Evidence of right atrial enlargement (RAE)
- Specific ECG features (assumes normal calibration of 1 mV = 10 mm):
 - Any one or more of the following (if QRS duration <120 ms):
 - Right axis deviation (>90 degrees) in presence of disease capable of causing RVH
 - R in aVR > 5 mm, or
 - R in aVR $> Q$ in aVR
 - $(RI+SIII) - (SI+RIII) <15$ mm (Lewis Index)
 - Any one of the following in lead V1:
 - R/S ratio > 1 and negative T wave
 - qR pattern (see Example #1 below)
 - R >7 mm, or S <2 mm, or rSR' with R' >10 mm
 - Other chest lead criteria:
 - R in V1 + S in V5 (or V6) 10 mm
 - R/S ratio in V1 >1 or S/R ratio in V6 >1
 - R in V5 or V6 <5 mm
 - S in V5 or V6 >7 mm
 - ST segment depression and T wave inversion in right precordial leads are usually seen in severe RVH such as in pulmonary stenosis and pulmonary hypertension.

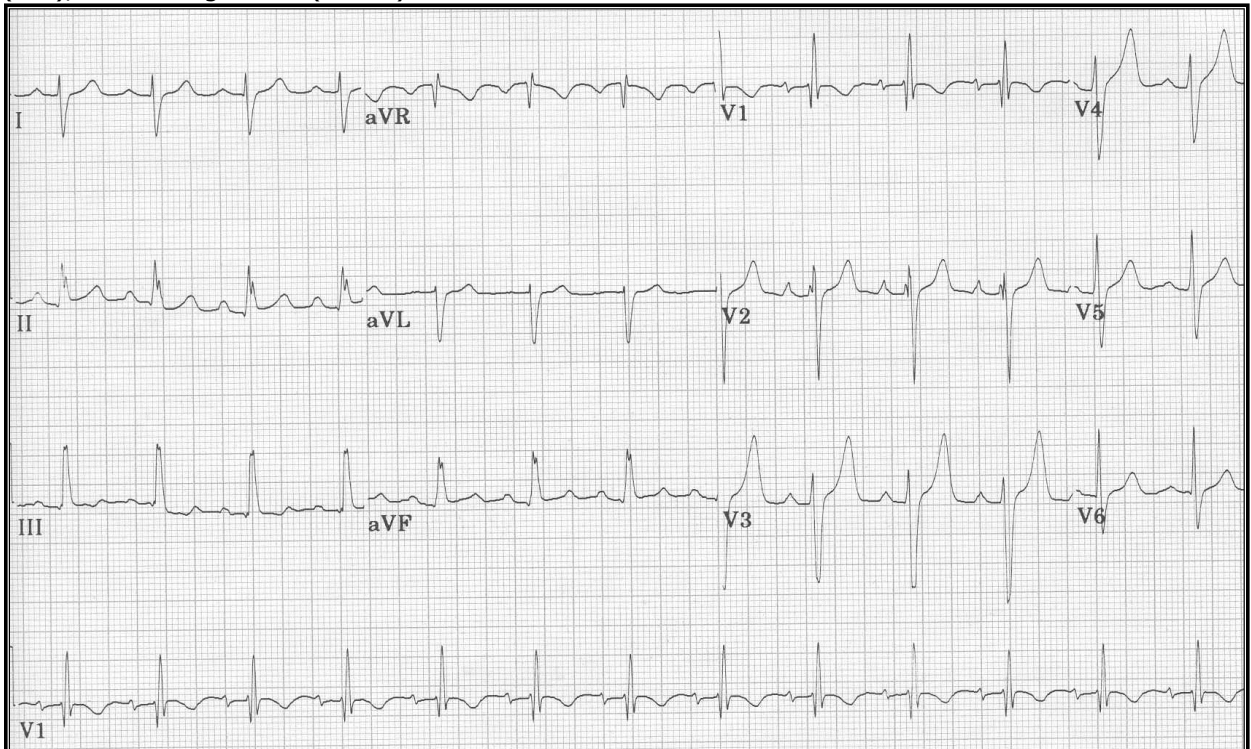
Example #1: RVH in patient with mitral stenosis. Note qR pattern in V1, marked RAD ($+140^\circ$), large P-terminal force in V1 (LAE), slight increased QRS duration (incomplete RBBB), deep S wave in V5-6.



Example #2: 18 yr. old patient with primary pulmonary hypertension. Note: marked RAD (+140°), R in V1 >7mm, prominent anterior forces in V1-3, increased P amplitude of RAE, and the typical RV strain pattern in precordial leads (ST depression, T wave inversion)



Example #3: RVH in patient with an atrial septal defect. Note the incomplete RBBB pattern in V1 (rsR'), and the slight RAD (+105°).



III. Biventricular Hypertrophy (difficult ECG diagnosis to make)

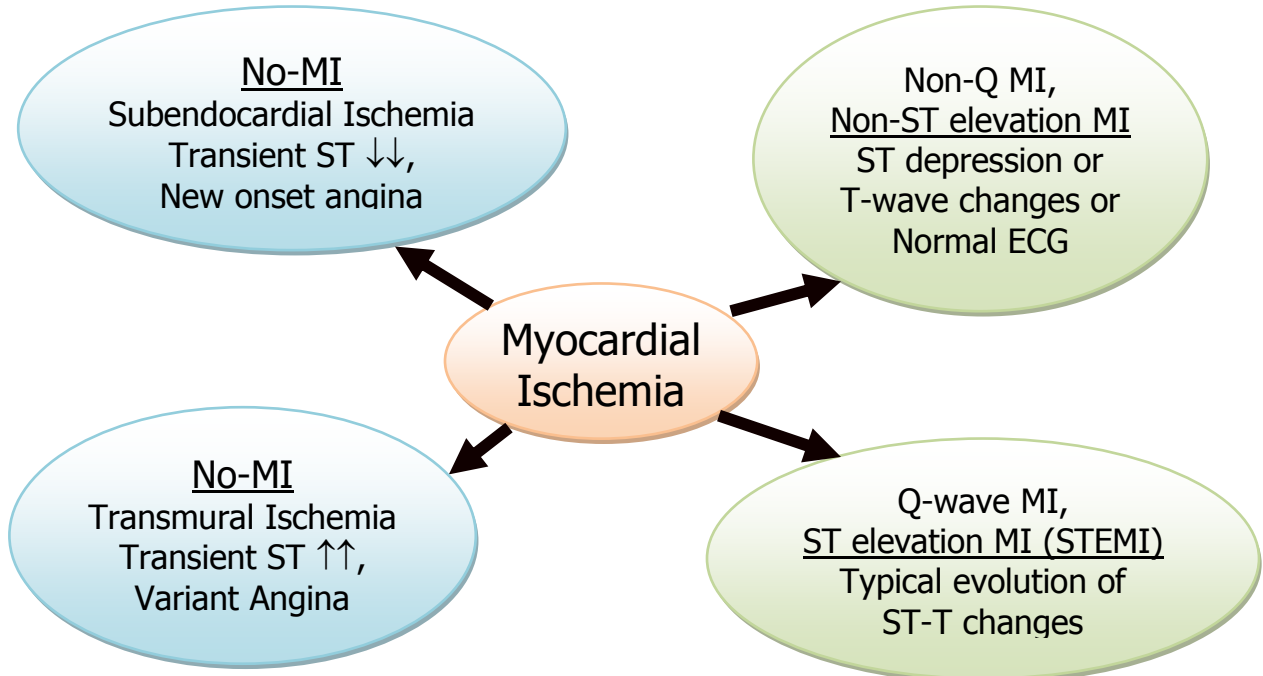
- In the presence of LAE any one of the following suggests this diagnosis:
 - R/S ratio in V5 or V6 < 1
 - S in V5 or V6 > 6 mm

- RAD (>90°)
- Other suggestive ECG findings:
 - Criteria for LVH and RVH both met or LVH criteria met and RAD or RAE present

9. MYOCARDIAL INFARCTION

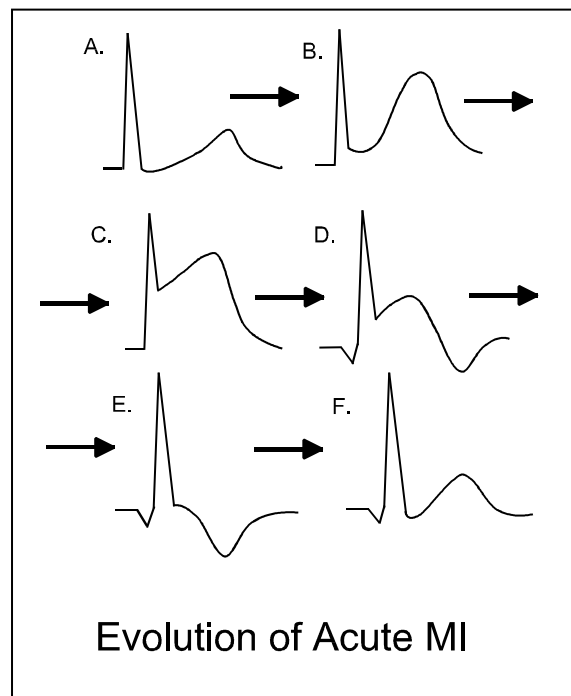
Introduction to ECG Recognition of Acute Coronary Syndrome (ACS)

- The ECG changes of ACS are the result of a sudden reduction of coronary blood flow to regions of ventricular myocardium supplied by a coronary artery with a ruptured or eroded atherosclerotic plaque and intracoronary thrombus formation. Depending on how quickly the patient gets to the hospital for definitive treatment (usually percutaneous revascularization or thrombolytic Rx) myocardial necrosis (infarction) may or may not occur. The diagram below shows four possible ECG outcomes of myocardial ischemia in the setting of new onset coronary ischemia. On the left side no myocardial necrosis (or infarction) occurs (negative troponins) but there is either **subendocardial** ischemia manifested by transient ST segment **depression** or **transmural** ischemia manifested by transient ST segment **elevation**. On the right are the two types of myocardial infarction (with elevated troponins indicative of cellular death), one manifested by ST segment elevation (**STEMI**) and one without ST segment elevation (**NonSTEMI**). Either of these can evolve into Q-wave or non-Q-wave MI's. Because Q waves may not appear initially, early treatment decisions are based on the presence or absence of ST segment elevation, and if revascularization is accomplished quickly Q-waves may never appear as the residual damage or scar is small (therefore, "**time is muscle**" says the interventional cardiologist).



The following discussion will focus on ECG changes during the evolution of a STEMI

- All MI's involve the **left ventricular myocardium**. In the setting of a proximal right coronary artery occlusion, however, there may also be a component of **right ventricular** infarction as well. ST segment elevation in right sided chest leads or just the V4R right precordial lead are usually needed to recognize RV MI.
- In general, the more leads of the 12-lead ECG with MI changes (Q waves and/or ST elevation), the larger the infarct size and the worse the prognosis (i.e., more damage).
- The left anterior descending coronary artery (LAD) and its branches supply the anterior and anterolateral walls of the left ventricle and the anterior two-thirds of the septum. The left circumflex coronary artery (LCx) and its branches supply the posterolateral wall of the left ventricle. The right coronary artery (RCA) supplies the right ventricle, as well as the inferior (diaphragmatic) and posterior-lateral walls of the left ventricle, and the posterior third of the septum. The RCA also gives off the AV nodal coronary artery in 85-90% of individuals; in the remaining 10-15%, this artery is a branch of the LCX.
- The usual ECG evolution of a STEMI with new Q-waves is illustrated in the diagram below. Not all of the 6 patterns are seen in every patient; the time from onset of MI to the final pattern is quite variable and is related to the size of MI, the rapidity of reperfusion (if any), and the location of the MI. (The example in the diagram might be seen in lead II during an acute inferior STEMI)
 - A. Normal ECG waveform prior to the onset of plaque rupture
 - B. Hyperacute T wave changes - increased T wave amplitude and width; QT may prolong; may also see early ST segment elevation
 - C. Marked ST elevation with hyperacute T waves ("tombstone" pattern)
 - D. Pathologic Q waves appear (cell necrosis), ST elevation decreases, T waves begin to invert (this is also called the "fully evolved" phase)
 - E. Pathologic Q waves, T wave inversion (necrosis and fibrosis)
 - F. Pathologic Q waves, upright T waves (fibrosis)
 - (G). Q waves may get smaller or disappear with time

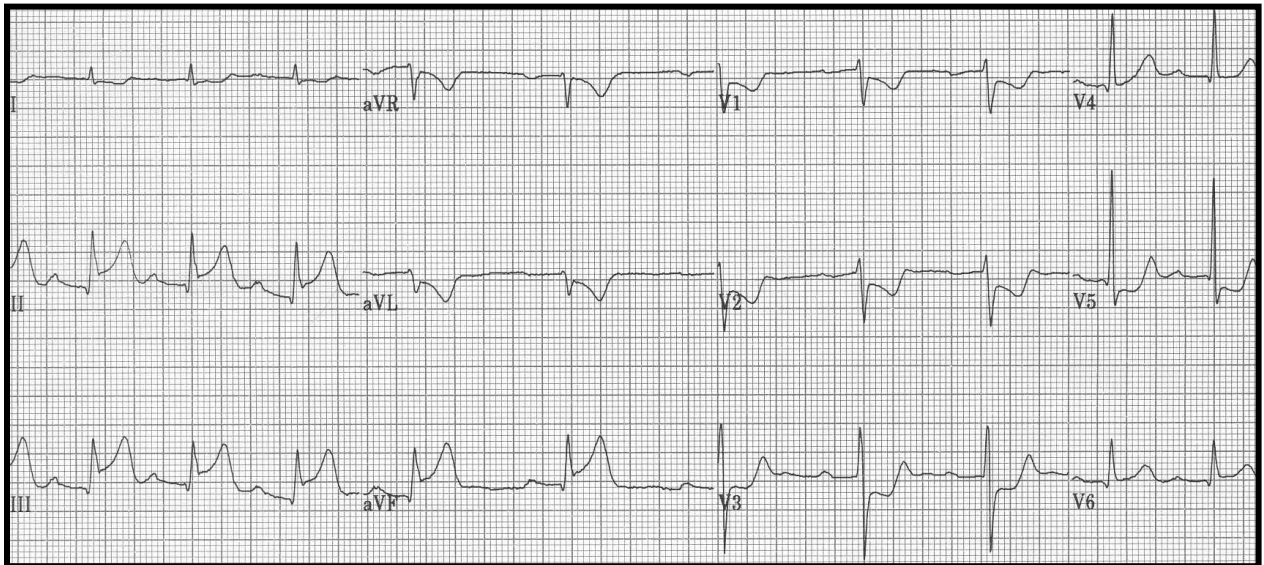


I. Inferior MI Family of STEMI's (\pm Q-wave MI's); includes inferior, 'true posterior', and right ventricular MI's

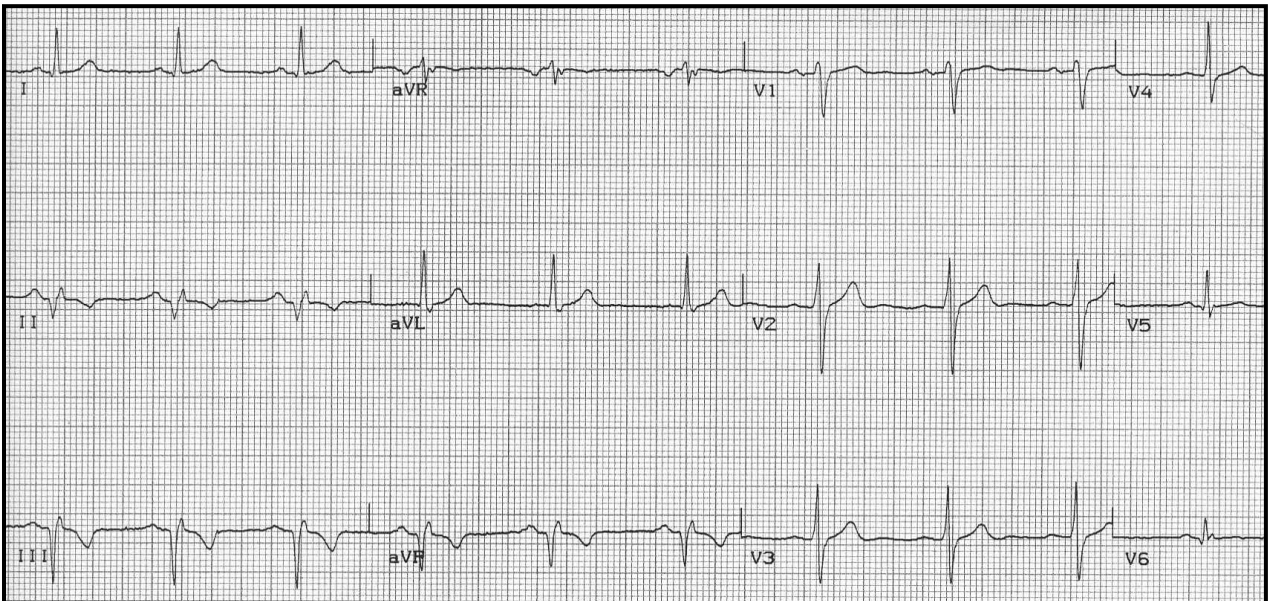
- **Inferior MI**

- Evolving ST-T changes in leads II, III, aVF (see above diagram)
- Q waves (if they appear) are usually largest in lead III, next largest in lead aVF, and smallest in lead II. Q wave ≥ 30 ms in aVF is diagnostic.

Example #1: Acute inferior MI injury pattern. Note tall hyperacute T waves with ST elevation in II, III, aVF (ST \uparrow in III > ST \uparrow in II suggests RCA occlusion); *reciprocal* ST depression is seen in I, and aVL. ST depression in V1-3 represents posterior or lateral injury pattern and is not a *reciprocal* change (see 'posterior' MI patterns below). Note the V4 and V5 electrode sites in this ECG are interchanged (this is an ECG technician error; it doesn't alter the diagnosis however).

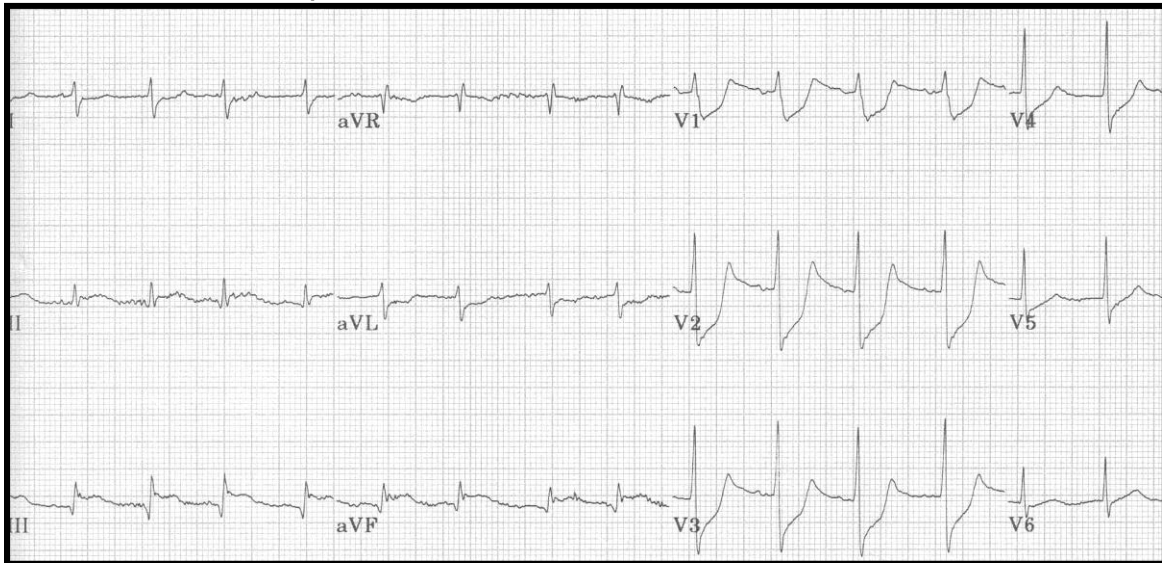


Example #2: Old inferior MI (note largest Q in lead III, next largest in aVF, and smallest in lead II). QRS Axis is -50° (LAD); T wave inversion is also present in leads II, III, and aVF.

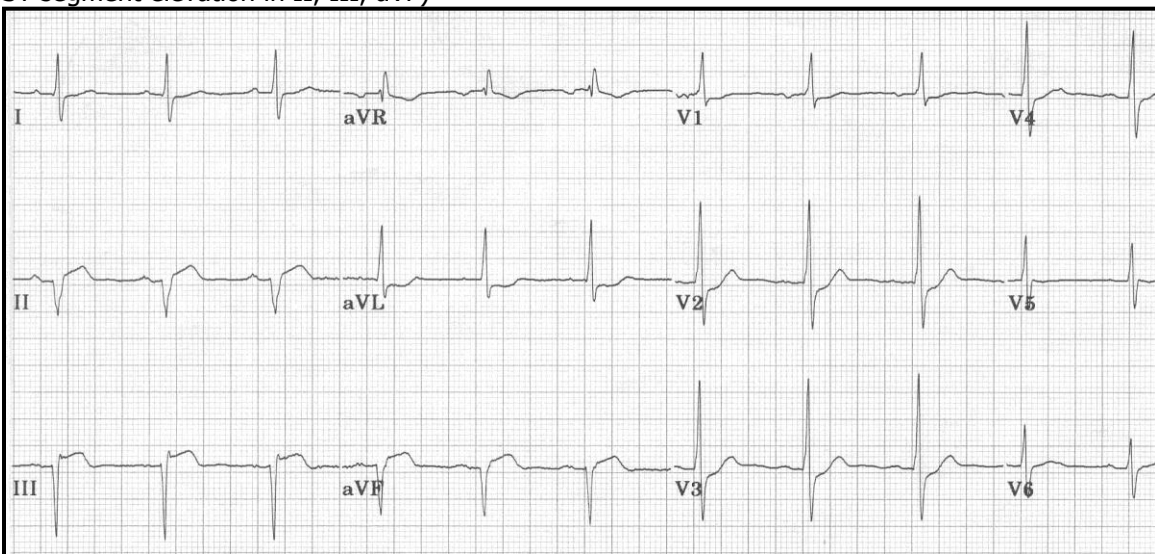


- **True posterior MI: (note, 'new' terminology renames this location as 'lateral')**
ECG changes are seen in precordial leads V1-3, but are the mirror image of an anteroseptal MI (because the posterior or lateral LV wall is *behind* the anterior wall)
- Increased R wave amplitude and/or duration ≥ 40 ms in V1-2 (i.e., a "pathologic R wave" is the mirror image of a pathologic Q on the posterior wall, possibly seen in V8 and V9)
- PAF: R/S ratio in V1 or V2 > 1 (i.e., prominent anterior forces; need to R/O RVH, LSF, etc.)
- Hyperacute ST-T wave changes: i.e., ST depression and large, inverted T waves in V1-3
- Late normalization of ST-T with symmetrical upright T waves in V1 to V3
- Often seen with an inferior wall MI (i.e., "infero-posterior MI")

Example #3: Acute infero-posterior MI (note tall R waves V1-3, marked ST depression V1-4, and ST elevation in II, III, aVF)



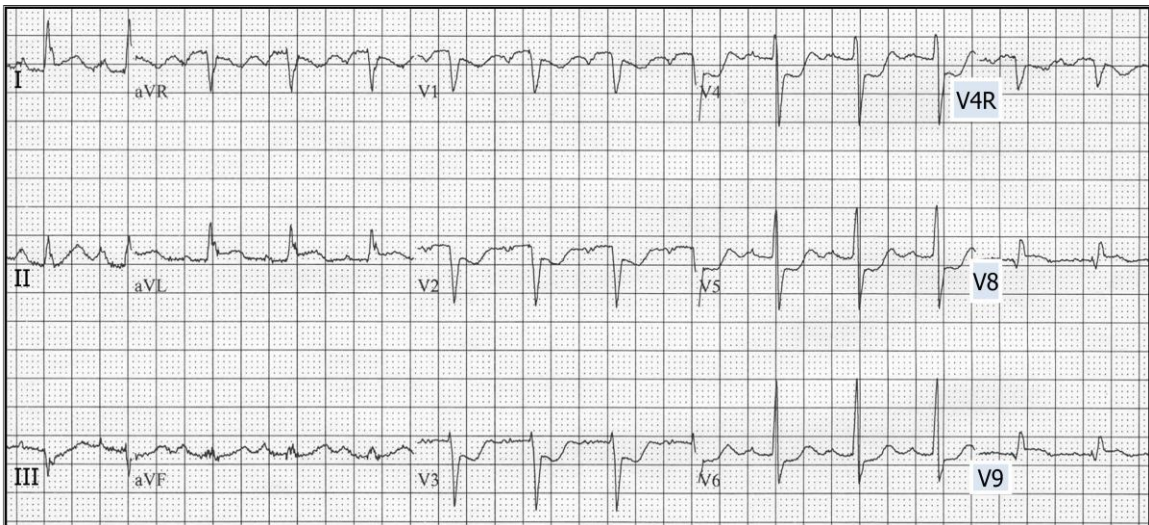
Example #4: Old infero-posterior (now called **infero-lateral**) MI: Note tall, wide 'pathologic' R wave in V1-3 (this is a Q wave equivalent), upright T waves, and inferior Q waves with residual ST segment elevation in II, III, aVF)



Differential Diagnosis of PAF (Tall R waves in V1 or V2) (with narrow QRS complexes):

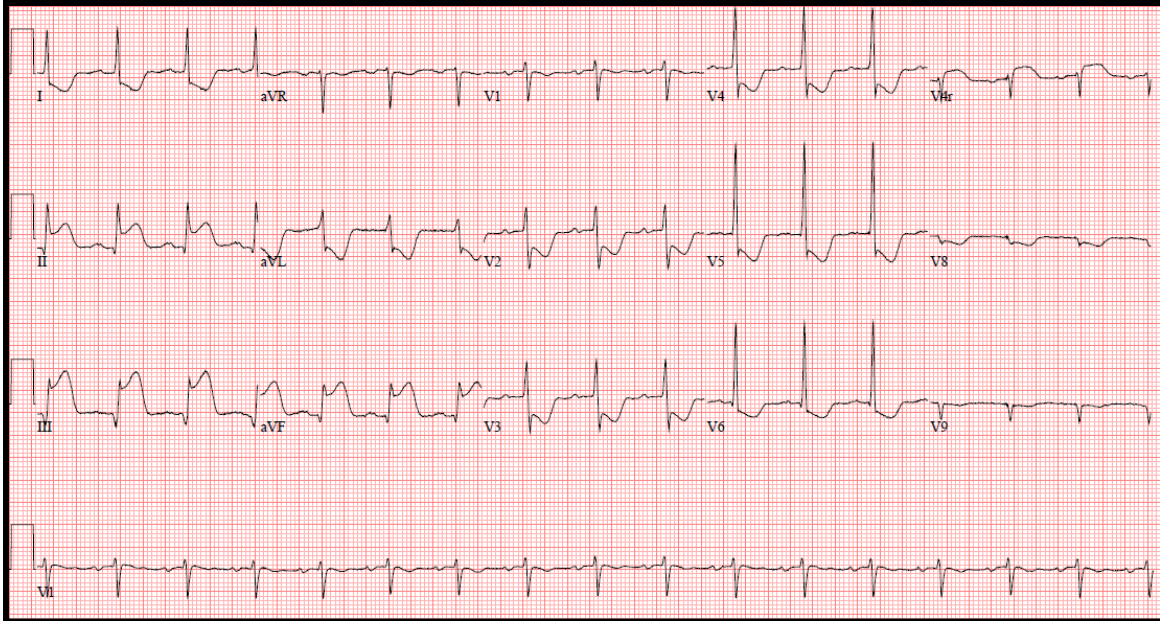
- True 'posterior' (lateral) myocardial infarction (see above)
- Right ventricular hypertrophy (p64-65)
- Left septal fascicular block (p56)
- Normal variant (early transition)
- Misplaced precordial leads
- Atypical RBBB, incomplete RBBB
- Some cases of WPW (the tall 'R' looking wave is actually an upright delta wave)

Example #5: Acute "posterior" (or lateral) MI due to LCx occlusion. This is a 15-lead ECG with the addition of right precordial **V4R** (to rule out RV MI), and posterior leads **V8** and **V9** placed on the back horizontal to leads V4-6. In this ECG one can see ST elevation in V8-9, and slightly elevated ST segments in leads I and aVL. Note also the ST depression V1-6 indicative of 'lateral' or dorsal transmural injury. The absence of ST elevation in V4R rules out a right ventricular MI (see Example #6 below). The 15-lead ECG is useful in the differential diagnosis of ST depression in the right precordial leads.



- **Right Ventricular MI** (only seen with proximal right coronary occlusion; i.e., with inferior family of left ventricular MI's)
 - ECG findings usually require additional leads on right chest; Criteria: ST elevation, ≥ 1 mm, in right chest leads, especially V4r (see below).

Example #6: Acute inferior MI also involving the right ventricle; 15-lead ECG (adding V4r, V8, V9). Note ST segment elevation in V4r indicative of proximal RCA occlusion causing right ventricular infarction in addition to the acute inferior left ventricular MI. Note: ST elevation in lead III > ST elevation in lead II, also indicative of RCA occlusion.

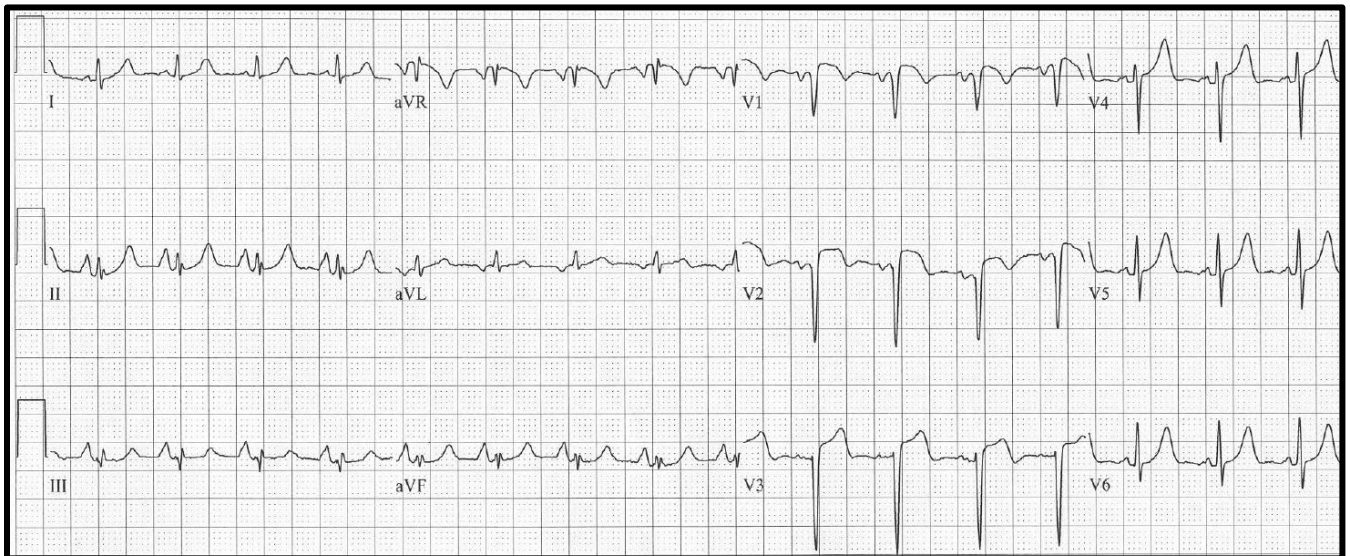


Acute Inferior STEMI (15 leads) with RV MI (note ST elevation in V4r)

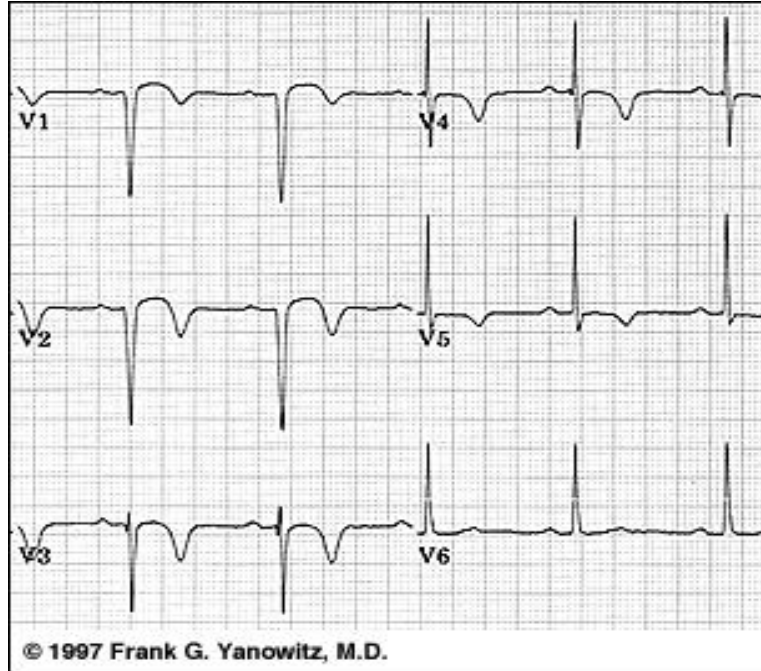
II. Anterior Family of STEMI's; includes anteroseptal, anterior, anterolateral, and high lateral

- **Anteroseptal MI**
 - Q, QS, or qrS complexes in leads V1-V3
 - Evolving ST-T changes

Example #7: Acute anteroseptal MI; marked ST elevation in V1-3 with poor R wave progression V1-4 (note convex-up ST elevation in V1-2). Note also right atrial enlargement (tall P waves, inferior leads).

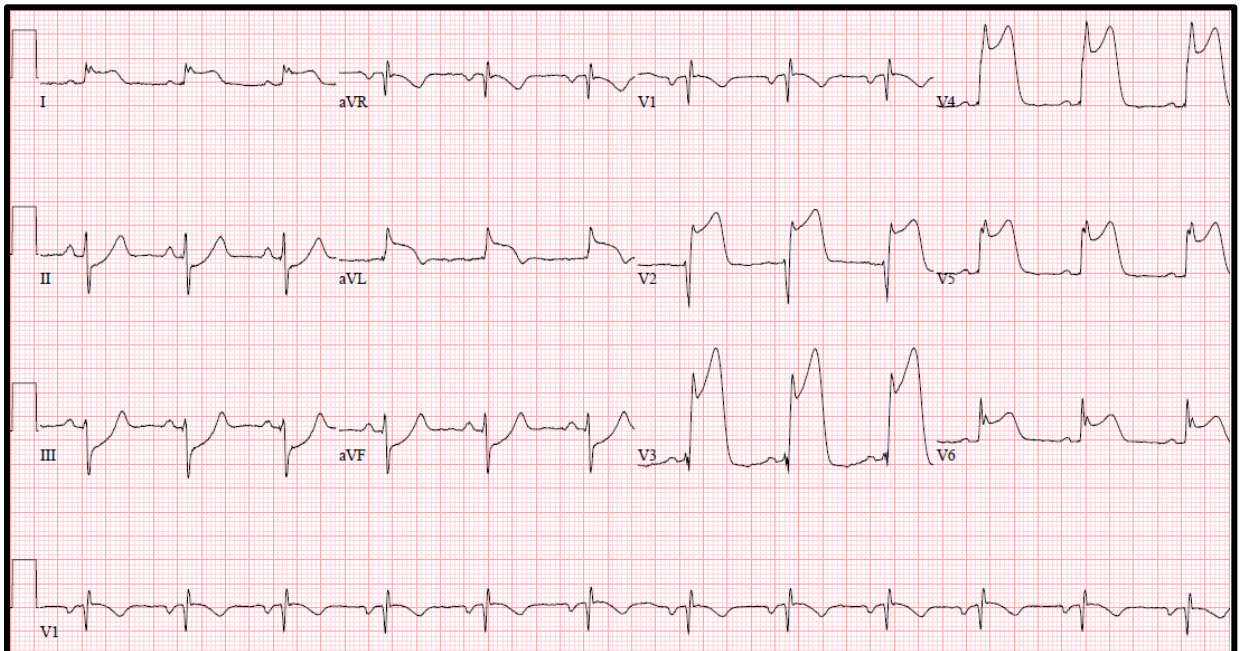


Example #8: Fully evolved anteroseptal MI (note QS waves in V1-2, qrS complex in V3, resolving ST elevation with deep inverted T waves)

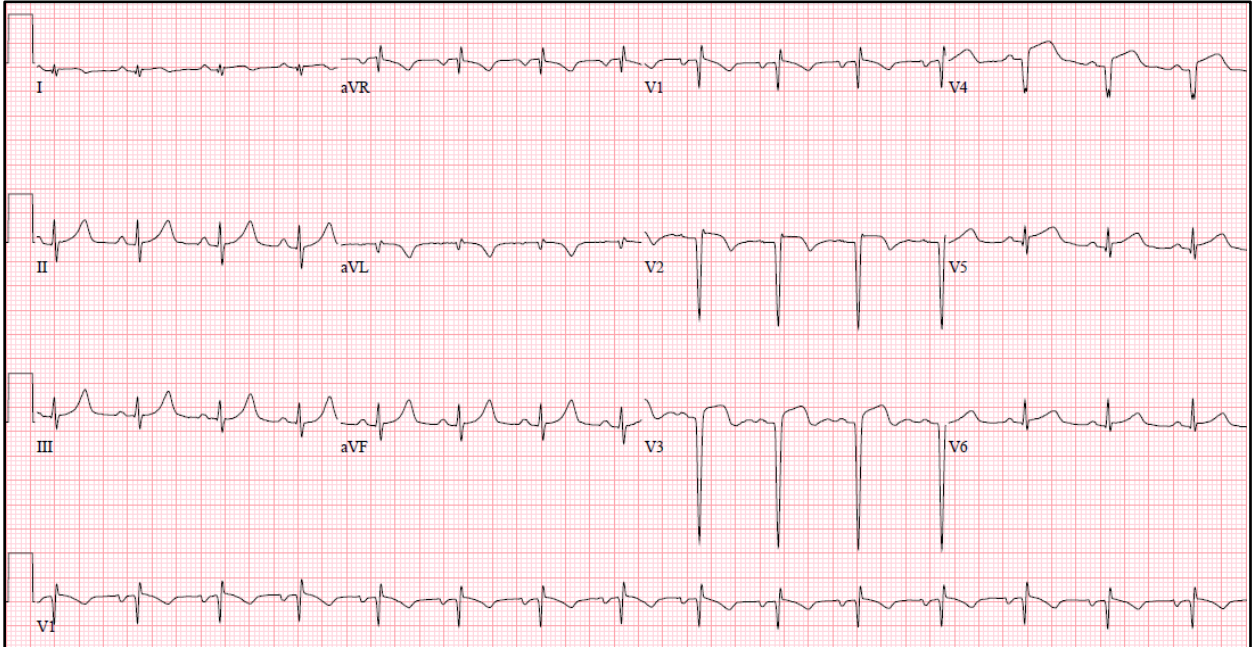


- **Anterior MI** (similar changes, but usually V1 is spared; if V4-6 involved call it "anterolateral"; if changes also in leads I and aVL it's a "high-lateral" MI).

Example #9: Acute **extensive anterior** injury; note 'tombstone' ST elevation V2-6, I, aVL; note reciprocal ST depression in II, III, aVF. This **really big** infarct occurred in a young man who dissected his LAD artery following a fall; although not a plaque rupture, his LAD was completely occluded! Fortunately, he was successfully treated with a stent to his LAD.



Example#10: Same patient as above; 16 hours later (after LAD stent)



Note: new Q waves V2-4 and resolving ST changes indicative of successful reperfusion.

Comment: The precise identification (and terminology) of MI locations on the ECG is evolving as new heart imaging (e.g., MRI) better defines the ventricular anatomy. New terminology has been suggested (see *Circulation* 2006;114:1755). While not universally accepted, the following “new” Q-wave MI patterns (scar) have been defined for left ventricular segments seen on MRI imaging:

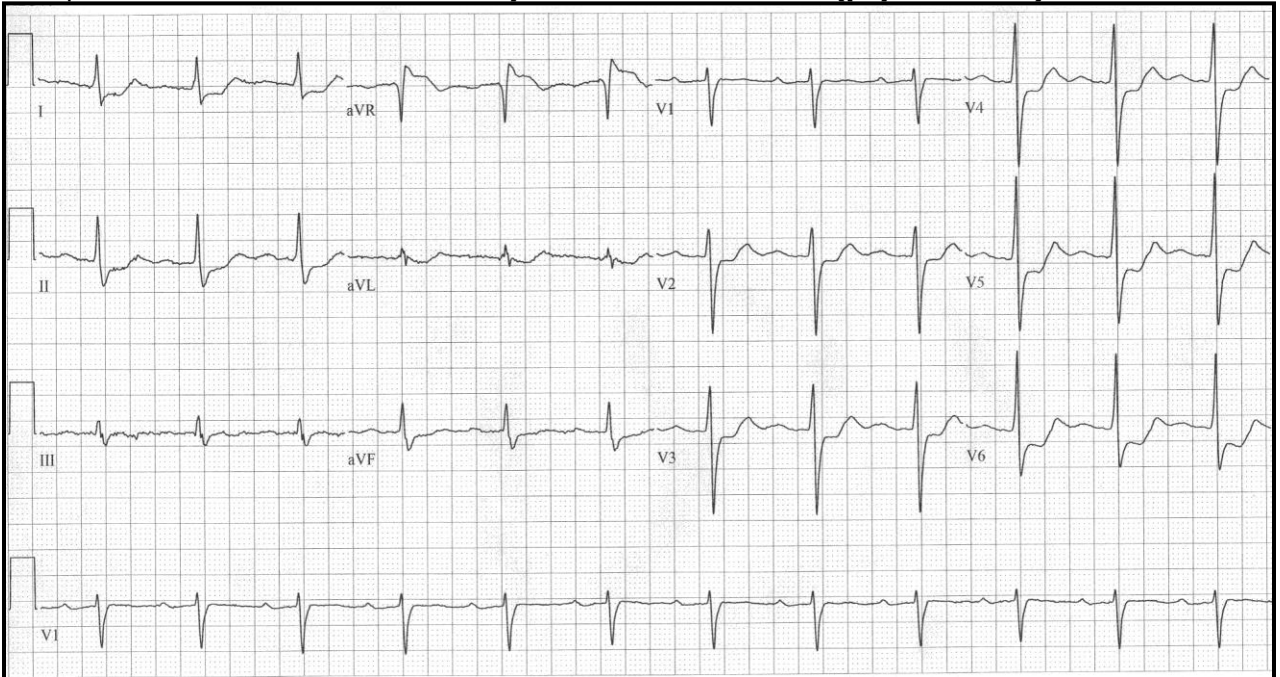
- **Septal MI:** Q (or QS) waves in V1-2
- **Mid-Anterior MI:** Q waves in aVL, sometimes in lead I, V2, V3, but not in V5-6.
- **Apical-Anterior MI:** Q waves in V3, V4, and sometimes in V5-6. No Q waves in I, aVL
- **Extensive Anterior MI:** Combination of above 3 locations.
- **Lateral MI:** Prominent R waves (PAF) in V1-2 (this replaces the true posterior MI terminology; MRI imaging of the left ventricle shows no posterior wall). Q waves may also be present in I, aVL, V5-6.
- **Inferior MI:** Q waves in II, III, aVF, but without prominent R waves in V1-2

(It remains to be seen whether or not this new terminology of infarct location will become accepted in the ECG literature of the future)

The next ECG (Example #11) illustrated below is a tragic case of a missed acute left main *sub-total* coronary occlusion. It was inappropriately diagnosed as a non-STEMI because of the absence of typical ST segment elevation in 2 or more contiguous ECG leads. Instead of proceeding to emergent coronary intervention, the patient was treated with the non-STEMI protocol in a CCU for 12 hrs. until a disastrous cardiac arrest occurred. The ECG findings of left main sub-total coronary occlusion seen in the next ECG include:

- ST segment elevation in aVR > any ST elevation in V1 and
- ST segment depression in 7 or more leads of the 12-lead ECG
- These ECG findings indicate circumferential subendocardial ischemia due to left main coronary artery occlusion or due to severe triple vessel CAD. Although technically this is a non-STEMI, the extent of ischemia is sufficient to consider this a STEMI equivalent and Rx’ed emergently.

Example #11: Acute Left Main Coronary Sub-totaled Occlusion (pay attention!):

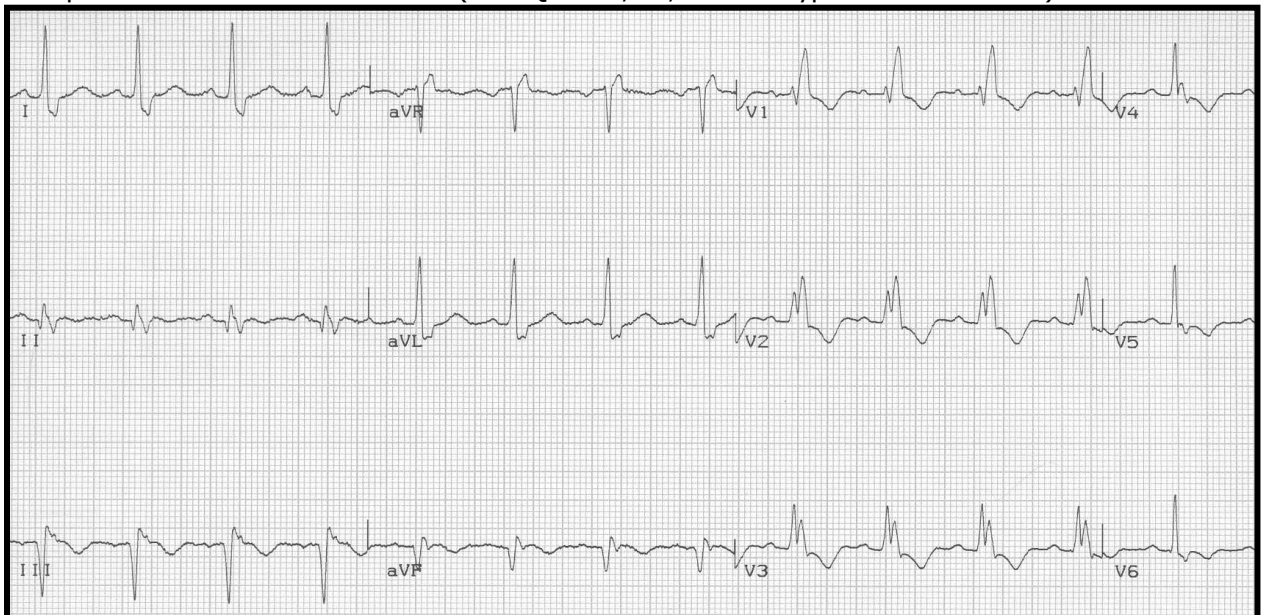


Note: ST depression in at least 7 leads; ST elevation aVR > any ST elevation in V1.

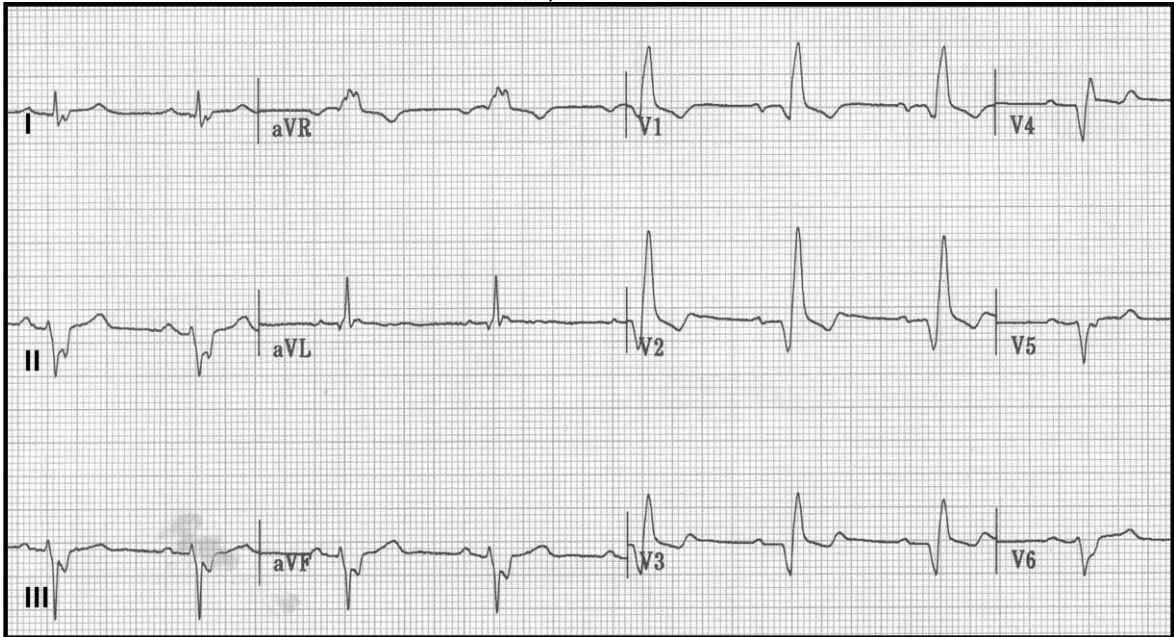
III. MI with Bundle Branch Block

- **MI + Right Bundle Branch Block**
 - Usually easy to recognize because the appearance of Q waves and ST-T changes in the appropriate leads are not altered by the presence of RBBB. Acute and chronic ischemic events in the left ventricle are not disturbed by late activation of the RV due to RBBB.

Example #12: Old Inferior MI + RBBB (note Q's in II, III, aVF and typical rSR' in lead V1)



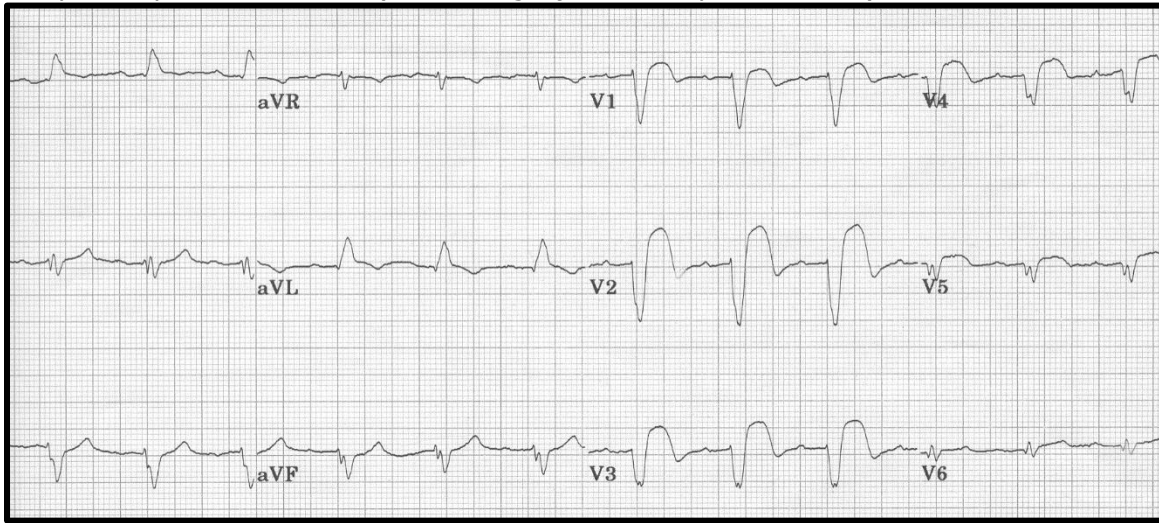
Example #13: Extensive old anterior MI with RBBB + LAFB; note pathologic Q's in leads V1-V5, terminal fat R wave in V1-4, wide S wave in V6 of RBBB). Axis = -80° (rS in II, III, and aVF: indicative of left anterior fascicular block; RBBB+LAFB indicates bifascicular block!



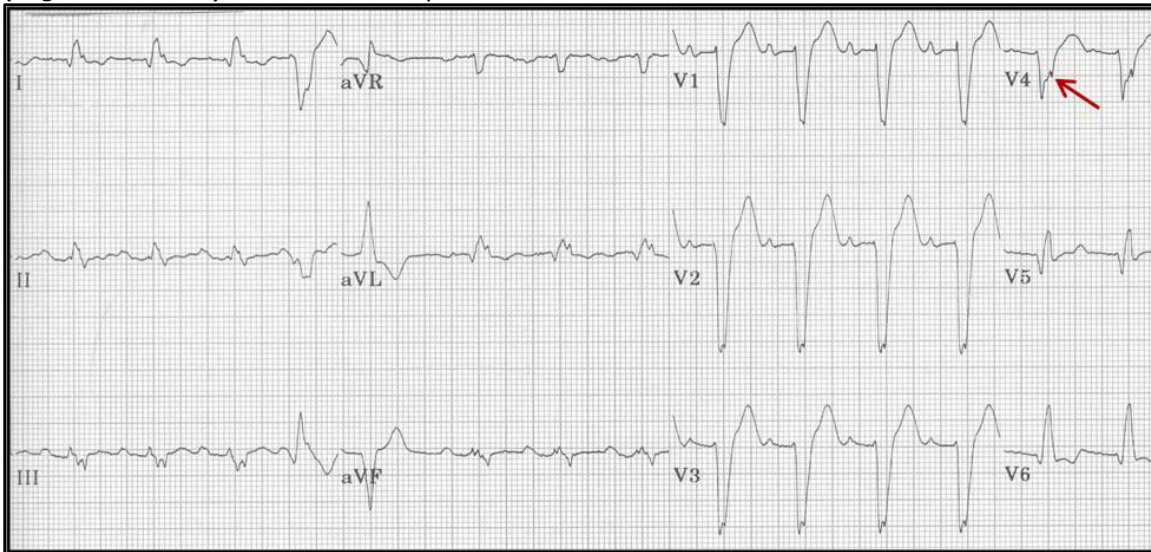
- **MI + Left Bundle Branch Block**

- This is often a difficult ECG diagnosis because in LBBB the non-infarcted right ventricle is activated first and left ventricular infarct Q waves may not appear at the beginning of the QRS complex (unless the septum is involved).
- Suggested ECG features, not all of which are specific for MI include:
 - Q waves of any size in two or more of leads I, aVL, V5, or V6 (See ECG #15 on p76: one of the most reliable signs and probably indicates *septal* infarction, because normally in LBBB the septum is activated early from the right ventricular. When the septum is infarcted, however, the electrically silent (dead) septum results in early rightward QRS forces from the free wall of the right ventricle resulting in Q waves in I, aVL, V6).
 - Reversal of the usual R wave progression in precordial leads
 - Notching of the downstroke of the S wave in precordial leads to the right of the transition zone (i.e., before QRS changes from a predominate S wave complex to a predominate R wave complex); this may be a Q-wave equivalent appearing *after* the onset of the QRS.
 - Notching of the upstroke of the S wave in precordial leads to the right of the transition zone (another Q-wave equivalent; see V4 in example #15).
 - rSR' complex in leads I, V5 or V6 (the S is a Q-wave equivalent occurring in the middle of the QRS complex).
 - RS complex in V5-6 rather than the usual monophasic R waves seen in uncomplicated LBBB; (the S is a Q-wave equivalent).
 - "Primary" ST-T wave changes (i.e., ST-T changes in the same direction as the QRS complex rather than the usual "secondary" ST-T changes seen in uncomplicated LBBB). Also, exaggerated ST deviation in same direction as the usual LBBB ST changes in LBBB (see leads V1 and V2 in Example #14). These changes may reflect an acute, evolving MI, and are considered part of Sgarbossa's criteria.

Example #14: Acute anterior and septal MI with LBBB. Note exaggerated convex-upwards ST elevation in V1-3 and unexpected "Primary" ST elevation in I, aVL; also note the small unexpected q-waves I, aVL, V6 (i.e., no longer just a monophasic R wave).



Example #15: Old MI (probable septal location) with LBBB. Remember LBBB without MI should have **monophasic** R waves in I, aVL, V6). This ECG has abnormal q waves in I, aVL, V5-6 suggesting a septal MI location. Note also the notching on the upslope of S wave (arrow) in V4 ("sign of Cabrera") and the PVC couplet.

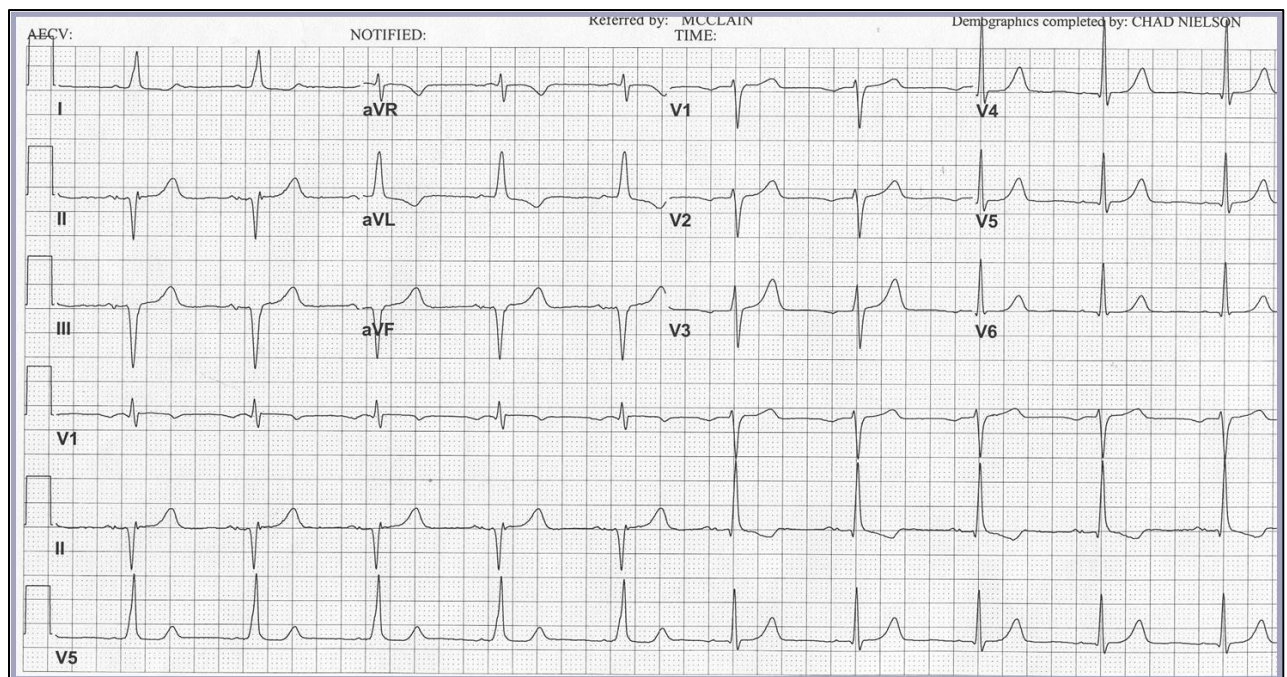


IV. Non-ST elevation MI (NSTEMI)

- ECG changes may be minimal, or may show only T wave inversion, or may show ST segment depression with or without T wave inversion.
- Although it is tempting to localize the non-Q MI by the particular leads showing ST-T changes, this is probably only valid for the ST segment elevation MI's (STEMI)
- Evolving ST-T changes may include any of the following patterns:
 - ST segment depression in 2 or more leads (this carries the worse prognosis)
 - Symmetrical T wave inversion only (this carries a better prognosis)
 - Combinations of above changes
 - **OR** the ECG may remain normal or only show minimal change; this is usually associated with a good prognosis due to small amount of myocardial damage.

V. The Pseudoinfarcts

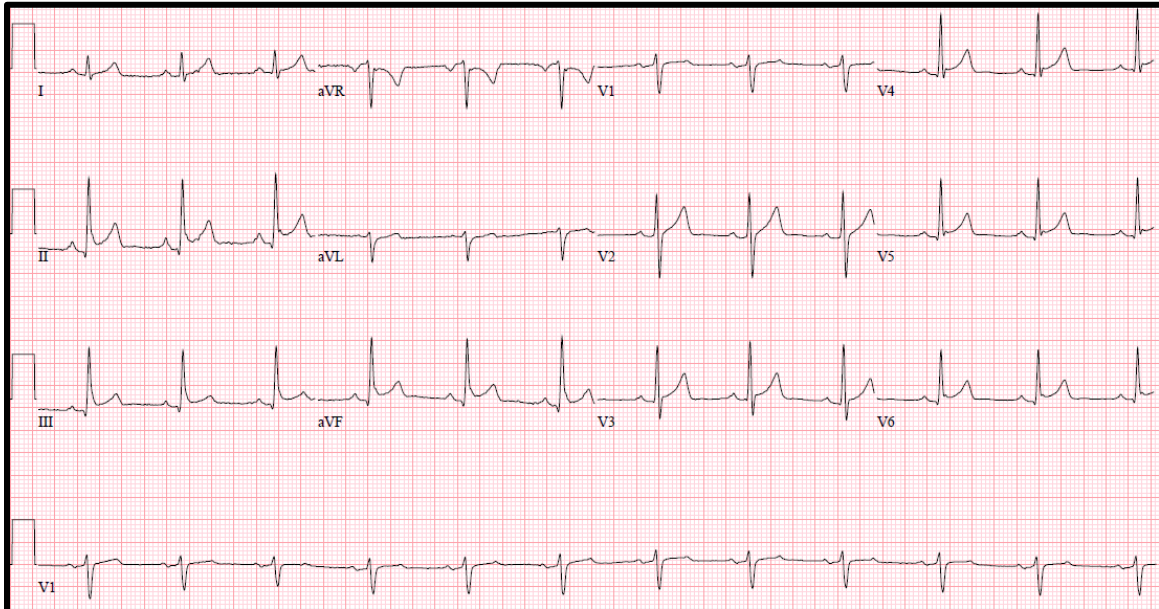
- These are ECG cases that mimic myocardial infarction either by simulating pathologic Q or QS waves or mimicking the typical ST-T changes of acute MI.
- **WPW preexcitation:** ECG leads with *negative* delta wave may mimic pathologic Q waves; see the next ECG. This interesting ECG has only *intermittent* WPW preexcitation. The WPW pattern is seen during the first half of the ECG, but disappeared when the precordial leads V1-6 were recorded. Note the deep Q and QS waves in leads II, III, and aVF. These are **not** really infarct Q waves but negative (down-going) delta waves. Note also the slurred upstroke of the QRS complex in leads I, and the first half of the V5 rhythm strip (bottom channel). In the 2nd half of the ECG tracing the "pseudo" Q waves in the lead II rhythm strip disappear and a qR wave QRS complex appears indicating the return of normal conduction through the ventricles. Also the delta wave in lead V5 goes disappears on the V5 rhythm strip during the 2nd half of the ECG. Finally, the PR interval is shorter during the 1st half of the ECG when preexcitation is occurring.



Intermittent WPW Preexcitation (1st half of ECG) with pseudo Q-waves II, III, aVF

- Hypertrophic cardiomyopathy (septal hypertrophy may make normal septal Q waves "fatter" thereby mimicking pathologic Q waves)
- LVH (may have QS pattern or poor R wave progression in leads V1-3 (pseudo anterior MI))
- RVH (tall R waves in V1 or V2 may mimic 'true posterior' or lateral wall MI)
- Complete or incomplete LBBB (QS waves or poor R wave progression in leads V1-3)
- Pneumothorax (loss of right precordial R waves)
- Pulmonary emphysema and cor pulmonale (loss of R waves V1-3 and/or inferior Q waves with right axis deviation)
- Left anterior fascicular block (may see small q-waves in anterior chest leads)
- Acute pericarditis (the ST segment elevation may mimic acute transmural injury)
- Central nervous system disease (may mimic non-Q wave MI by causing diffuse ST-T wave changes and QT interval prolongation)

- Gender: in some healthy women with poor R-wave progression in the precordial leads, the computer (and some ECG readers) may suggest anterior wall myocardial infarction (loss of anterior forces). This is often due to misplaced precordial lead location in a lower interspace due to large breasts.
- Benign early repolarization ST segment elevation may mimic acute STEMI in some in some people. The next ECG was interpreted by the computer as "acute inferolateral STEMI" emphasizing the need for *real people* (not computers) to interpret the ECG knowing the specific clinical context for the test.



Early Repolarization in a healthy 62 year old man during a routine preventive exam

VI. Miscellaneous Abnormalities of the QRS Complex in the differential diagnosis of Myocardial Infarction:

- **Poor R Wave Progression** – arbitrarily defined as small, or absent r-waves in leads V1-3 ($R < 2\text{mm}$, *plus* R/S ratio $V4 < 1$). Differential diagnosis includes:
 - Normal variant (if the rest of the ECG looks normal; frequently seen in women due to inaccurate precordial lead placement (under the breast – interspace lower))
 - LVH (look for voltage criteria and ST-T changes of LV "strain")
 - Complete or incomplete LBBB (also note the increased QRS duration)
 - Left anterior fascicular block (should see $LAD \geq -45^\circ$ in frontal plane)
 - Anterior or anteroseptal MI (look for evolving ST-T changes, and medical history)
 - Emphysema and COPD (look for R/S ratio in $V5-6 < 1$)
 - Diffuse infiltrative or myopathic processes
 - WPW preexcitation (look for *delta waves* and short PR)
- **Prominent Anterior Forces (PAF)** - defined as R/S ratio > 1 in V1 or V2. Differential diagnosis includes:
 - Normal variant (if the ECG is otherwise normal)
 - True posterior MI (look for additional evidence of inferior MI; see Example 4, p69)
 - RVH (should see RAD in frontal plane and/or P-pulmonale; see Example 2, p65)
 - Complete or incomplete RBBB (look for rSR' in V1)
 - WPW preexcitation (look for *delta waves*, short PR)
 - Left septal fascicular block (see p56)

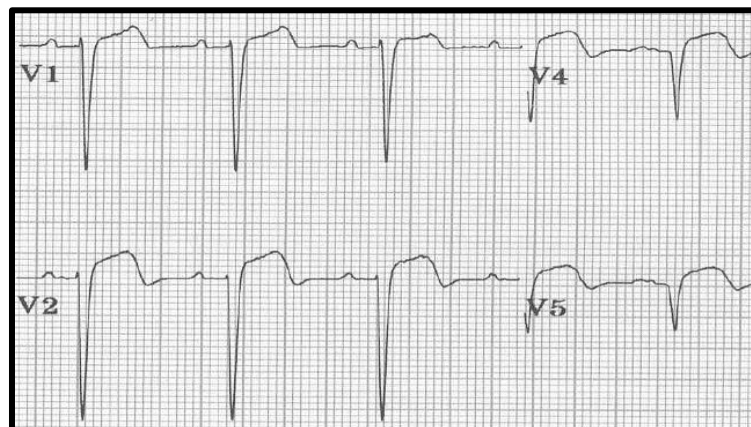
10. ST Segment Abnormalities

General Introduction to ST, T, and U wave abnormalities

- **Basic Concept:** the *specificity* of ST-T and U wave abnormalities is determined more by the clinical circumstances in which the ECG changes are found than by the particular changes themselves. Thus the term, **nonspecific ST-T wave abnormalities**, is frequently used for ST segment depression and T wave abnormalities when clinical data are not available to correlate with the ECG findings. This does not mean that the ECG changes are unimportant! **It is the responsibility of the clinician providing care for the patient to ascertain the importance of the ECG findings.**
- Factors affecting the ST-T and U wave configuration include:
 - Intrinsic myocardial disease (e.g., myocarditis, ischemia, infarction, infiltrative or myopathic processes)
 - Drugs (e.g., digoxin, antiarrhythmics, tricyclics, and many others)
 - Electrolyte abnormalities of potassium, magnesium, and calcium
 - Neurogenic factors (e.g., stroke, CNS hemorrhage, head trauma, brain tumor, etc.)
 - Metabolic factors (e.g., hypoglycemia, hyperventilation)
 - Atrial repolarization (e.g., at fast heart rates the end of the atrial T wave may pull down the beginning of the ST segment; this is not a true ST segment change)
 - Genetic abnormalities of channel membrane proteins, called **channelopathies**. Examples include *hereditary long QT syndromes*, and *Brugada Syndrome*.
- **Secondary** ST-T wave *changes* are the result of alterations in the sequence of ventricular depolarization (e.g., bundle branch blocks, WPW preexcitation and ventricular ectopic beats or paced beats). These *changes* are **not** abnormalities; they are appropriate in the setting of altered ventricular conduction. ST-T wave changes are called **primary** if they are independent of the sequence of ventricular depolarization (e.g., ischemic ST changes, electrolyte abnormalities, drug effects, etc.). These changes are repolarization *abnormalities*.

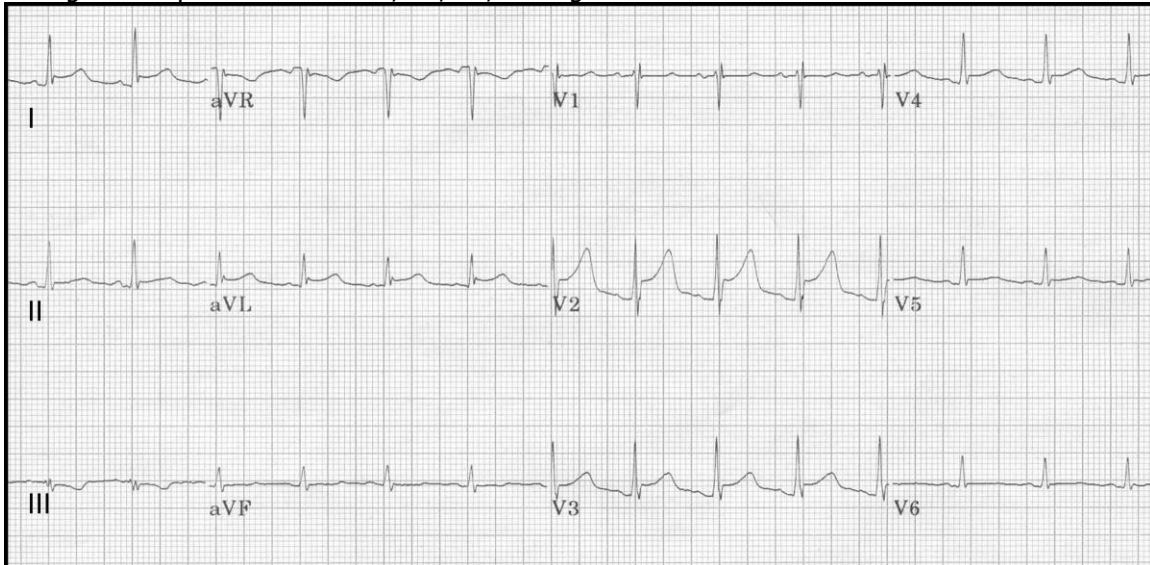
I. Differential Diagnosis of ST Segment Elevation

- Normal Variant "Early Repolarization Pattern": Traditionally this "pattern" consisted of concave upwards ST segment elevation ending with symmetrical, large, upright T waves in the lateral precordial leads (see ECG on p78). Recently, however, this "pattern" has been redefined to include end-QRS notching or slurring with or without ST segment elevation (*JACC* 2015; 66:470).
- **Ischemic Heart Disease** (usually ≥ 1 -2 mm convex upwards, or straightened ST segments in 2 or more contiguous ECG leads); this is a manifestation of **transmural** myocardial ischemia resulting from an acute total coronary occlusion.
Example: Acute anterior transmural injury – anterior MI (see selected leads below)



- **Note:** Persistent ST elevation *long after* an acute MI suggests failure of reperfusion, a ventricular aneurysm, or an akinetic scar resulting from a healed MI.
- Transient ST elevation may also be seen as a manifestation of Prinzmetal's (or "variant") angina caused by reversible coronary artery spasm. Coronary spasm can also occur from other precipitants including cocaine overdose.
- ST elevation during exercise ECG testing suggests high grade coronary artery stenosis or transient spasm and is indicative of transmural ischemia.
- Exercise induced ST segment elevation in lead aVR plus ST depression in 7 or more ECG leads suggests left main coronary artery disease (circumferential subendocardial ischemia).
- **Acute Pericarditis**
 - Concave upwards ST elevation in most leads except aVR
 - **Important:** No reciprocal ST segment depression (*except* in lead aVR)
 - Unlike "early repolarization", T waves in leads with ST elevation are usually lower in amplitude, and heart rate is usually increased.
 - May see PR segment depression which is a manifestation of atrial injury.

Example: Post-op acute pericarditis; note diffuse, concave-upwards ST elevation, HR 100 bpm, PR segment depression in leads I, V2, V3; PR segment elevation is seen in aVR.

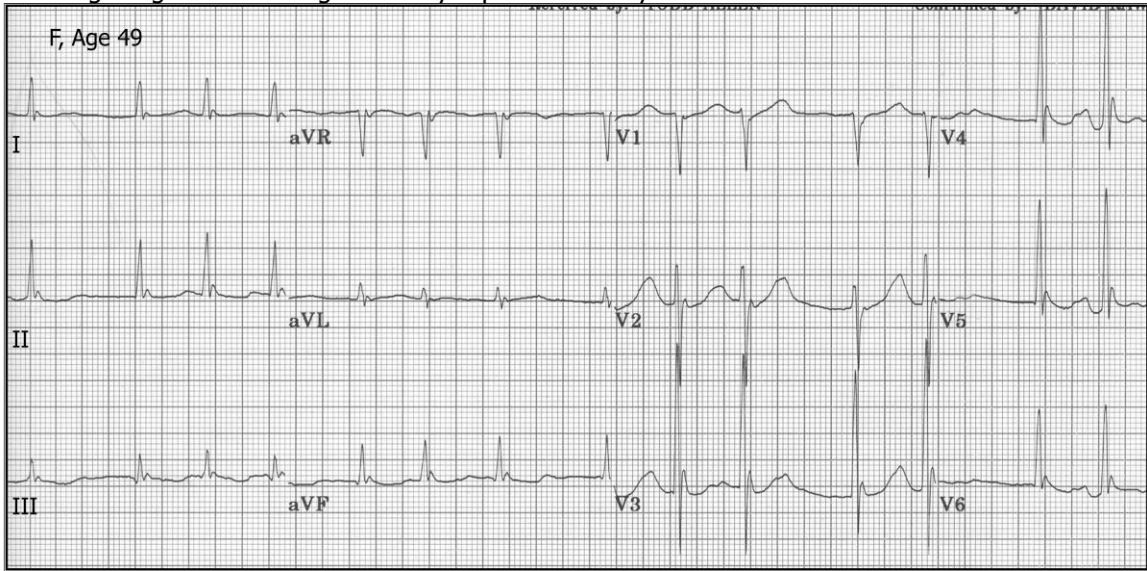


Acute Pericarditis

The ECG changes of acute pericarditis evolve over time through the following stages (not all stages are seen in every patient):

- Stage I: concave upwards ST segment elevation in most leads with reciprocal ST segment depression only in aVR. During this stage there may also be atrial injury represented by PR segment depression in many leads and PR segment elevation in aVR (see above example).
- Stage II: resolution of ST segment elevation and PR segment changes
- Stage III: diffuse T wave inversion in many leads
- Stage IV: resolution of the T wave changes or persistent T wave inversion (chronic pericarditis)
- **Hypothermia:** In this interesting condition the onset of the ST segment (called the J-point) turns into a wider J-wave as a result of increased transmural dispersion of ventricular repolarization (due to the cooler epicardial surface). The next ECG from an unconscious homeless woman illustrates prominent "J-Waves" in most leads (also called 'Osborn' waves).

J-waves are not specific to hypothermia and can be seen in other arrhythmogenic conditions including Brugada and malignant early repolarization syndromes.

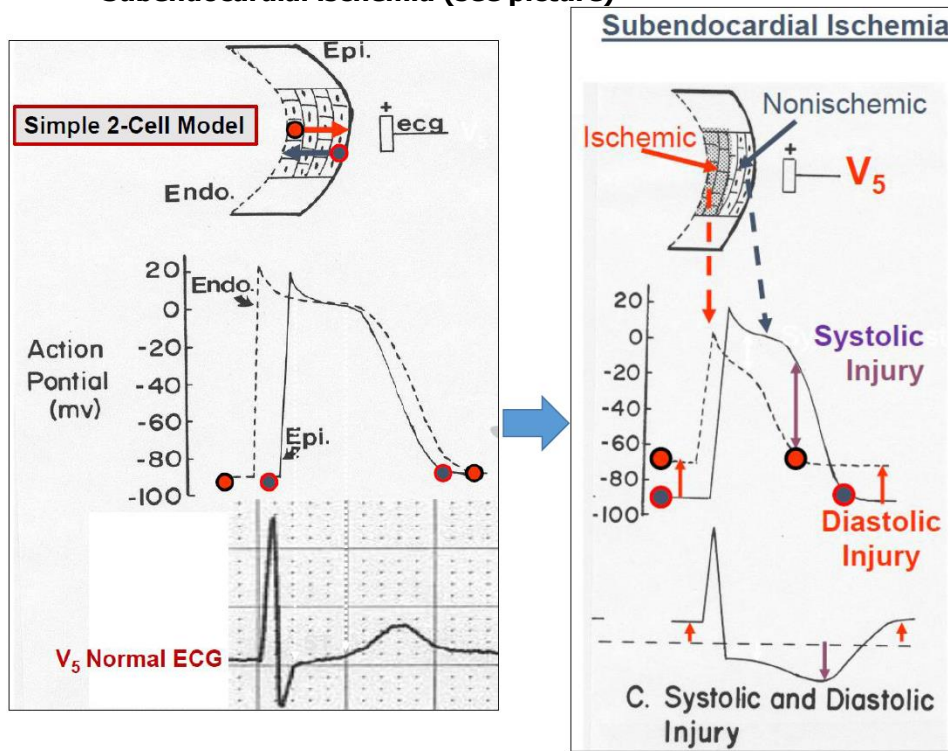


Hypothermia: note J waves in most leads (note also atrial fibrillation)

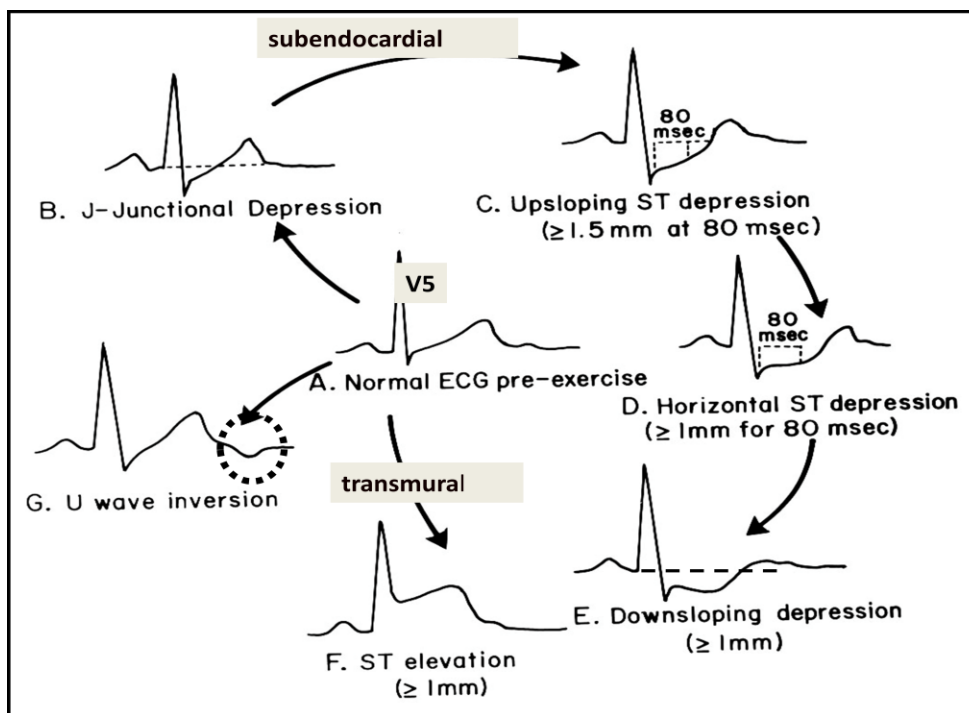
- Other Causes of ST segment elevation:
 - Left ventricular hypertrophy (seen in right precordial leads with large S-waves)
 - Left bundle branch block (seen in right precordial leads with large S-waves)
 - Advanced hyperkalemia (seen in multiple ECG leads with or without wide QRS complexes)

II. Differential Diagnosis of ST Segment Depression

- **Subendocardial ischemia (see picture)**

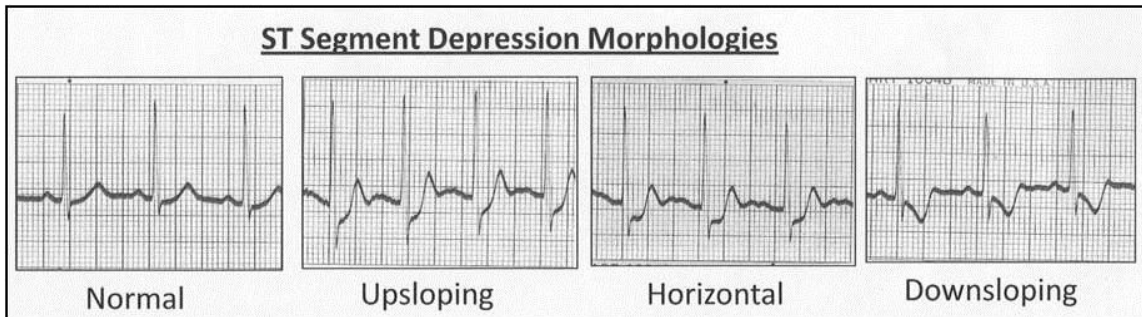


- As illustrated in the simple 2-cell model of cardiac depolarization (from endocardium-to-epicardium) and repolarization (from epicardium-to-endocardium) the relatively flat ST segment represents the plateau phase of the two action potentials when there is no potential difference between them. During subendocardial ischemia the action potentials from ischemic cells are altered in two ways: 1) loss of resting membrane potential (diastolic injury) which affects the TQ segment of the ECG, and 2) altered depolarization and repolarization which results in ST segment depression and T wave inversion (systolic injury) as seen in an ECG lead facing the myocardial wall segment. Modern ECG recording systems interpret TQ segment shifts as baseline artifact and returns the elevated TQ segment back to the original baseline further depressing the ST segment.
- ECG changes during exercise testing**



The above diagram illustrates possible ischemic ECG changes during treadmill exercise testing as seen in lead V5; this is the best lead for identifying subendocardial ischemia as demonstrated by the sequence C-D-E.

- Normal V5 ECG at rest before exercise (note normal ST-T and U waves)
- J-junctional ST depression due to increased HR (this is **not an ischemic change**, but represents atrial repolarization extending through the QRS into the ST segment)
- Early subendocardial ischemia (increased J-junctional depression, slowly upsloping ST)
- Horizontal ST segment depression (≥1mm, horizontal, lasting ≥80 ms)
- Downsloping ST depression with T wave inversion; this is usually seen post-exercise when the HR slows.
- ST segment elevation (this is a manifestation of **transmural ischemia**)
- U-wave inversion (a very unusual manifestation of ischemia suggesting LAD or L-main disease). When seen, it occurs during recovery when HR slows down.



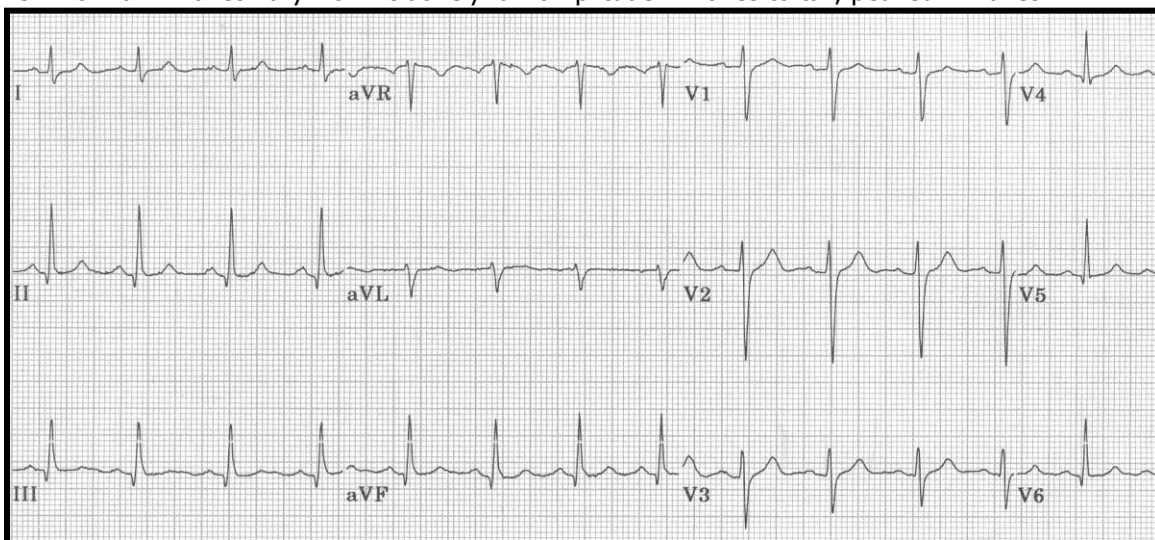
ST segment changes of subendocardial ischemia during exercise and recovery (V5)

Other causes of ST segment depression:

- Pseudo-ST-depression (wandering baseline artifact due to poor skin-electrode contact)
- Physiologic J-junctional depression with sinus tachycardia (resulting from atrial repolarization; not true ST change as seen in the above figure)
- Hyperventilation-induced ST segment depression (seen with anxiety)
- Non ST segment elevation myocardial infarction (Non-STEMI)
- Reciprocal ST depression in patients with STEMI (e.g., ST depression in I, aVL during an acute inferior STEMI)
- 'True posterior' MI (ST depression in V1-3 is reciprocal of ST elevation in leads V8-9)
- "Strain" pattern of RVH (right precordial leads V1-3) and LVH (left precordial leads V5-6)
- Drugs (e.g., digoxin)
- Electrolyte abnormalities (e.g., hypokalemia)
- Neurogenic effects (in CNS disease)

11. T Wave Abnormalities

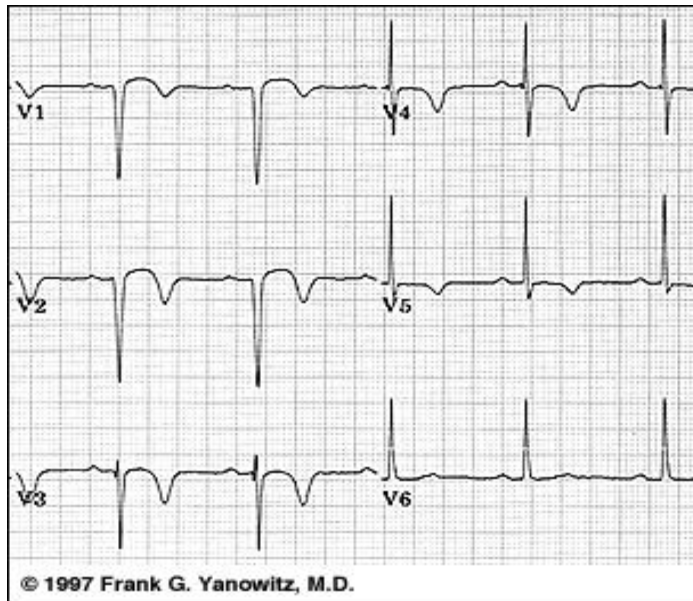
INTRODUCTION: The T wave is the most labile wave in the ECG. Abnormal T waves including low-amplitude and inverted T waves may be the result of many cardiac and non-cardiac conditions. The normal T wave is usually in the same direction as the QRS except in the right precordial leads (see V1-3 below). T waves in V1 may also be inverted, but are usually upright in V2-6 in adults. Also, the normal T wave is *asymmetric* with the ascending half moving more slowly than the descending half. In 'normal' ECGs the T waves are always upright in leads I, II, V3-6, and always inverted in lead aVR. T waves in other leads are variable depending on the QRS axis and the age of the patient. Children and adolescents may have inverted T waves from V1 to V3. Normal T waves vary from relatively low amplitude T waves to tall, peaked T waves.



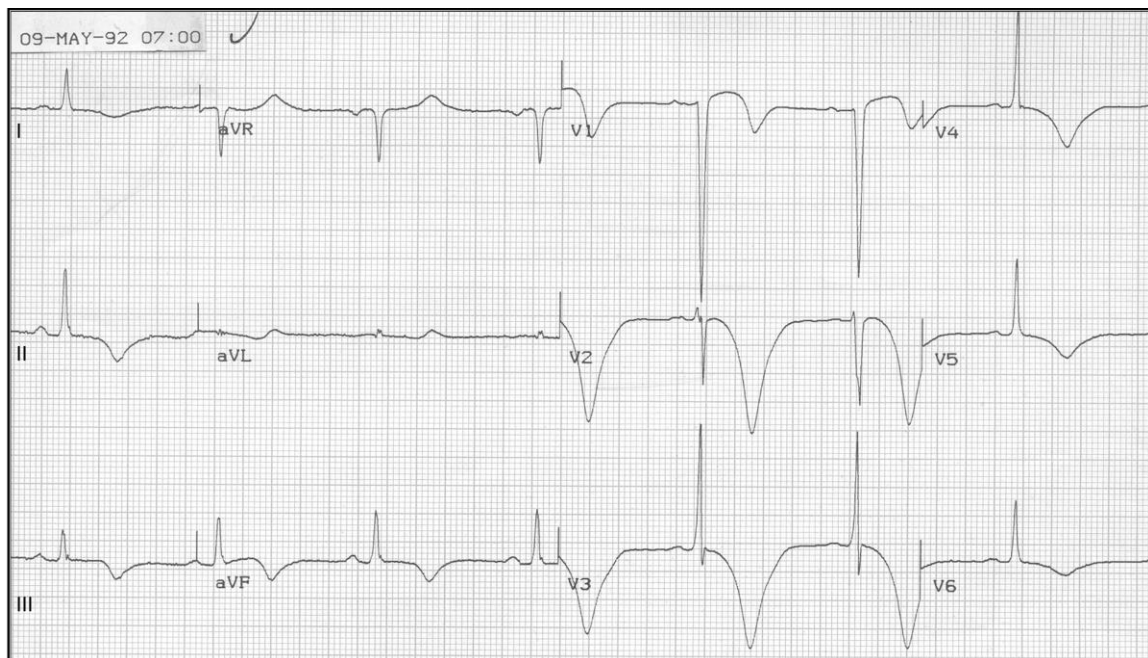Normal ECG

I. Differential Diagnosis of abnormal T Wave Inversion

- During the evolution of STEMI and non-STEMI MI's. The precordial leads shown below illustrate the evolved stage of an anterior MI after resolution of ST segment elevation:



- Subendocardial myocardial ischemia (e.g., during recovery from exercise testing)
- Subacute or healed pericarditis (see stages of pericarditis, p80)
- Myocarditis
- Myocardial contusion (from trauma; e.g., steering wheel accident)
- CNS disease (neurogenic T wave changes) with long QT intervals (especially after a subarachnoid hemorrhage; see ECG below with giant negative T waves and QT prolongation)

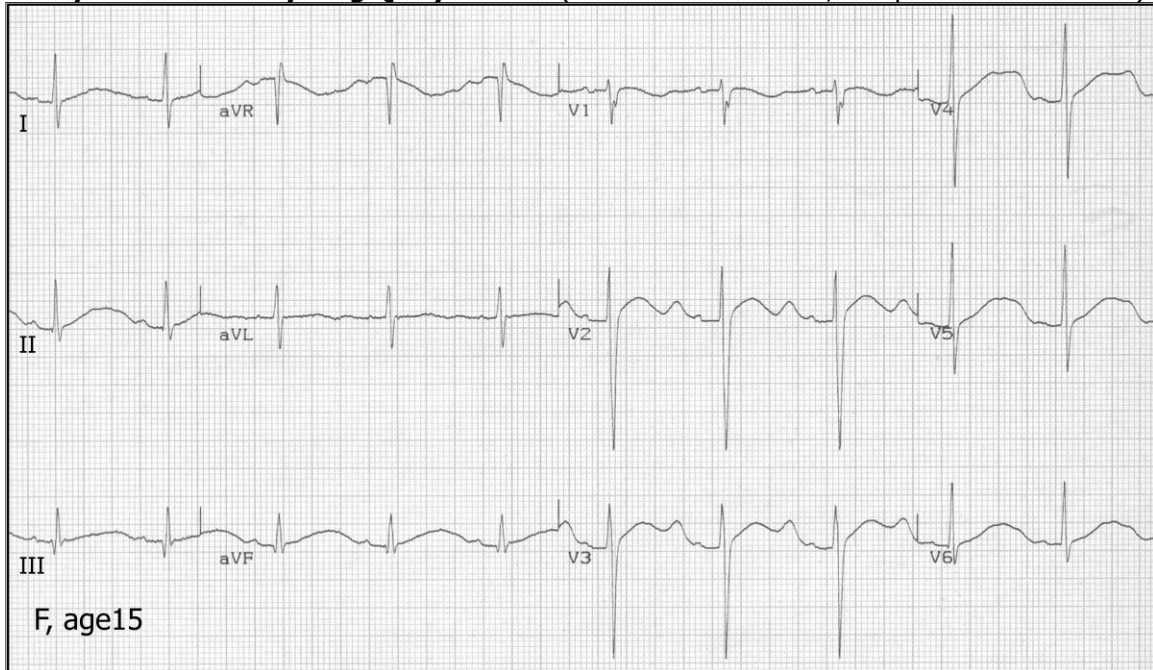


Giant Negative T waves and prolonged QT interval

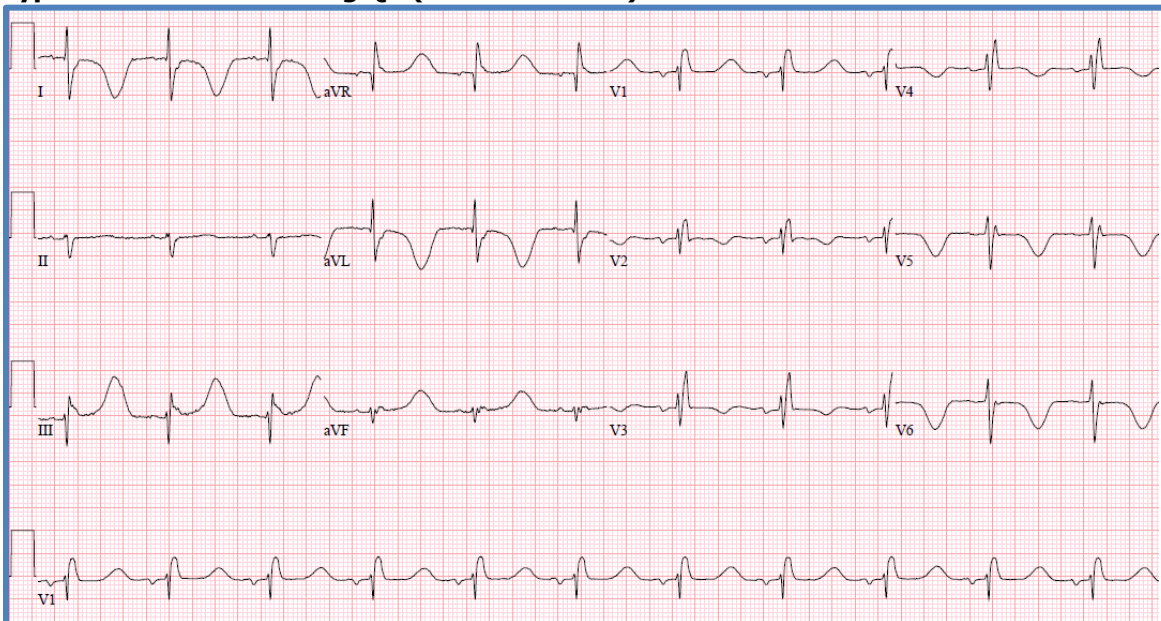
- Idiopathic apical hypertrophy (a rare form of hypertrophic cardiomyopathy with giant negative T waves)
- Mitral valve prolapse (some cases)

II. QT Interval Prolongation (increased probability of sudden cardiac death; see p16 for differential diagnosis of long QT):

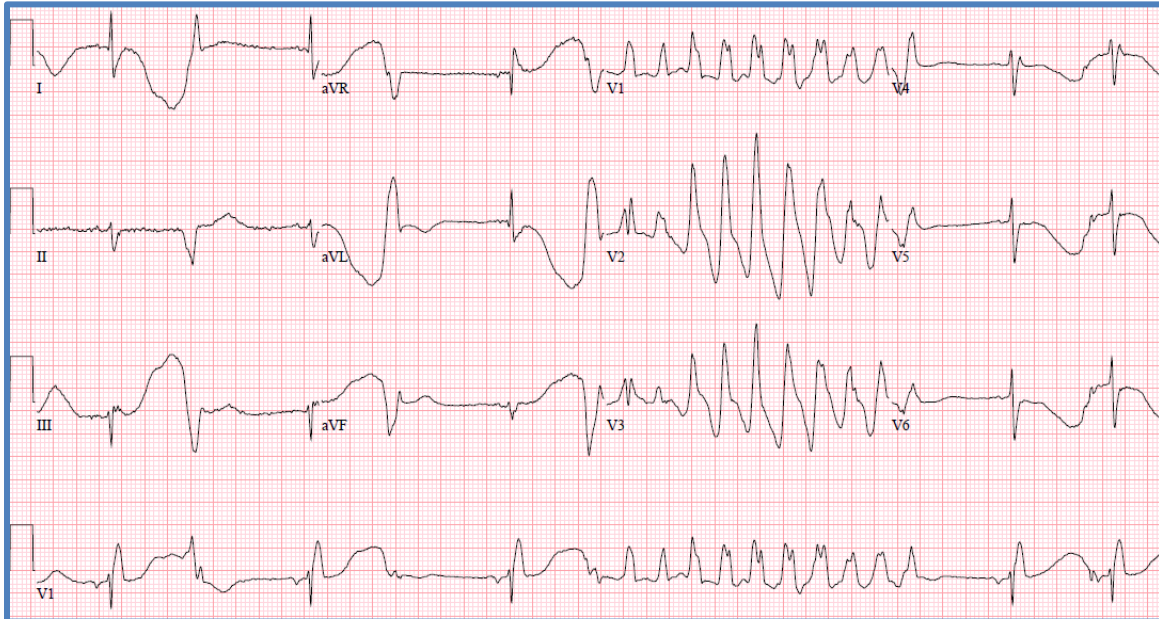
Example 1: Hereditary long QT syndrome (note the unusual bifid, humped T waves in V2-3)



Example 2: ECG changes in a patient on azithromycin and levofloxacin who also has hypokalemia induced Long QT (note also RBBB)

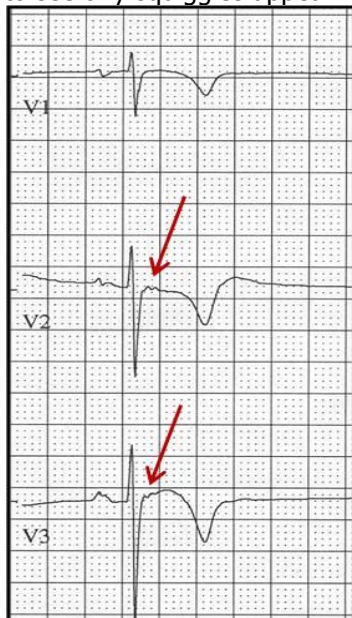


Same patient as above with PVCs (R-on-T) and polymorphic VT



III. Miscellaneous ST-T Wave Change

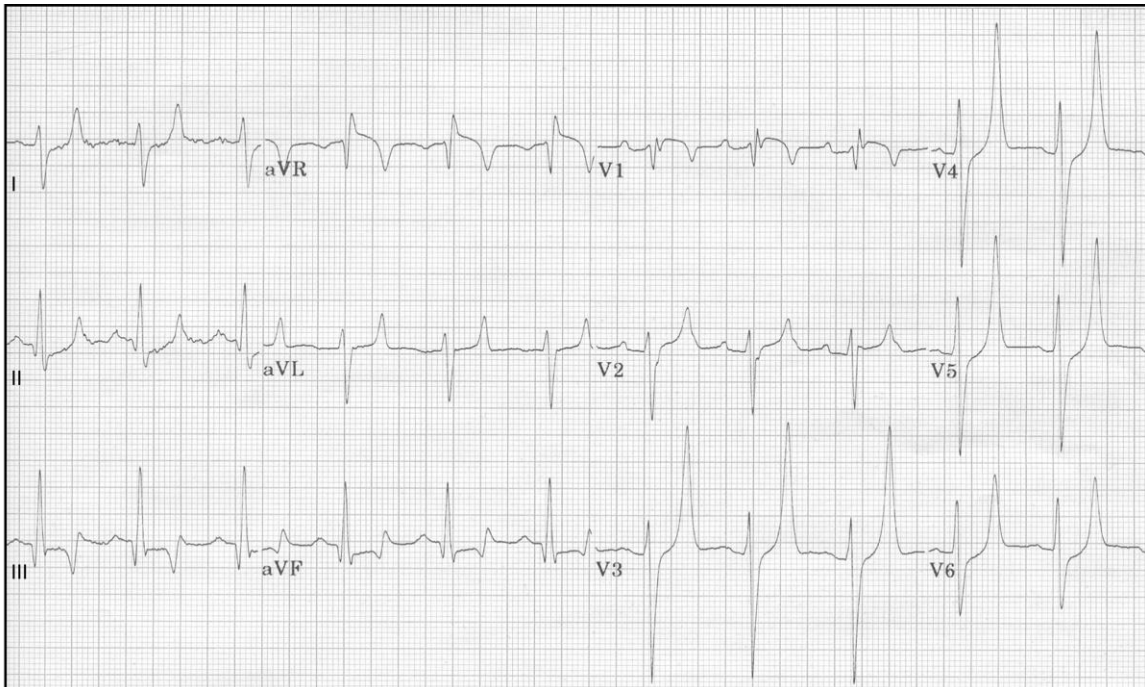
- Epsilon waves in *Arrhythmogenic Right Ventricular Cardiomyopathy* (ARVC); these hard to see tiny squiggles appear in the right precordial leads (see arrows in next ECG strip)



ARVC is a rare cause of sudden cardiac death in athletes. The disease usually involves the right ventricular outflow tract; normal myocardium is replaced by fatty infiltration and fibrosis. ECG manifestations include the very difficult to recognize *epsilon wave* as well as right precordial T wave inversions as seen above V1-3.

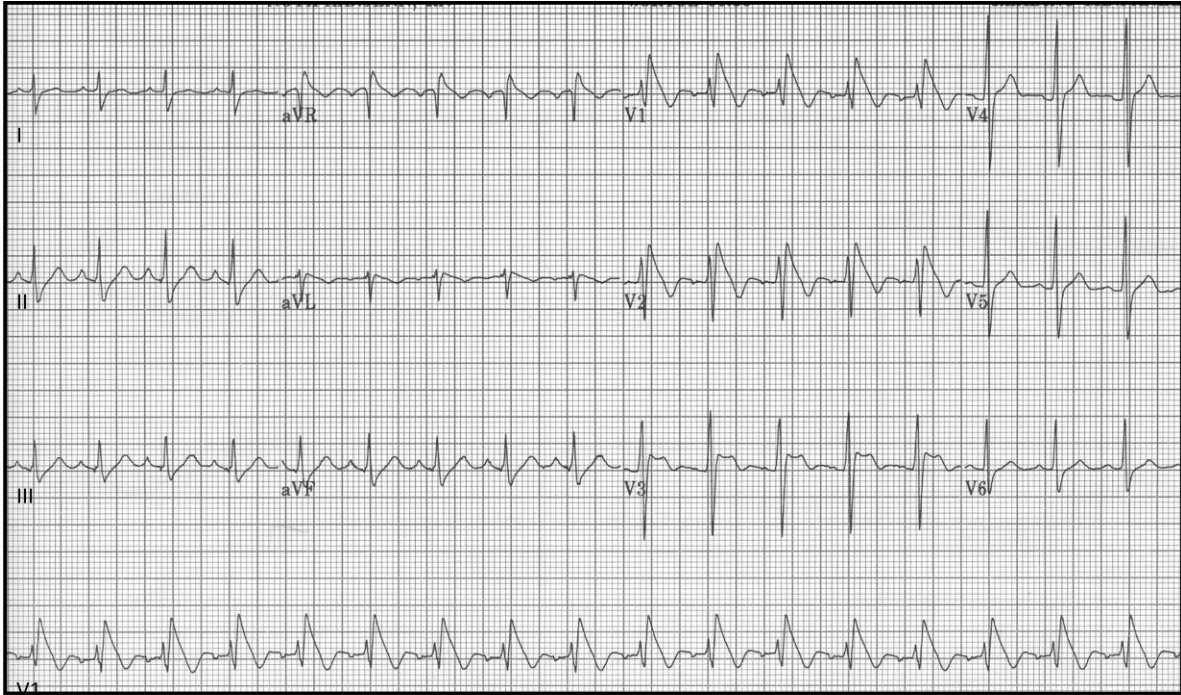
- Other causes of sudden cardiac death in young athletes include:
 - Hypertrophic cardiomyopathy (the most common cause in the U.S.). ECG findings in this disease include diffuse T wave inversions, prolonged QT intervals, and left ventricular hypertrophy.

- Congenital coronary artery anomalies (e.g., anomalous origin of the left coronary artery from the right coronary cusp). Sudden death is due to arrhythmias related to acute ischemic events.
- Coronary artery disease
- Myocarditis
- Hereditary channelopathies (long QT, short QT, Brugada syndrome, et al)
- ST-T wave changes related to electrolyte abnormalities
 - Hypercalcemia (abbreviated ST segment with short QT intervals)
 - Hypocalcemia and hypomagnesaemia (long ST segments with prolonged QT intervals)
 - Hyperkalemia (peaked T waves, prolonged QRS duration; see next ECG)
 - Hypokalemia (usual triad of: ST depression, low T waves, and large U waves)
 - Digoxin effect: scooped ST depression, low amplitude T waves, short QT intervals.



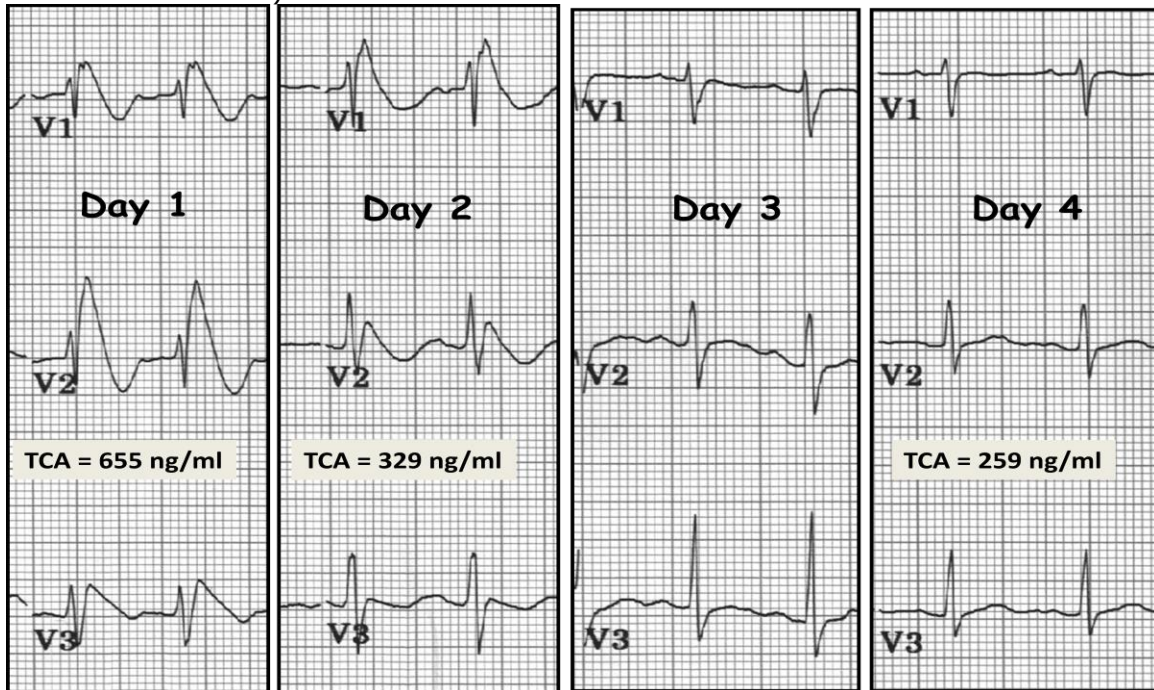
Hyperkalemia: tall, pointed, narrow T waves (don't try to sit on these!)

- **Brugada** type ECG is seen in the *hereditary* and *acquired* Brugada syndromes. This pattern can be induced with Class 1A antiarrhythmic drugs such as flecainide and ajmaline as well as other Na⁺ channel blockers. The pattern is best seen in the right precordial leads as an unusual, convex upwards ST segment elevation with or without T wave inversion. An example of a typical 'Type 1' Brugada pattern is seen in the next ECG. Note that leads V1 and V2 might be misinterpreted as RBBB, but the QRS duration is not prolonged in other leads. Similar to long QT syndromes, there is an increased incidence of malignant ventricular arrhythmias and sudden cardiac death in this condition.



Brugada type 1 ECG pattern (note high ST takeoff V1-3 with convex-upward ST)

The ECG V1-3 strips shown below illustrate resolution of the **acquired Brugada pattern** in a patient who overdosed a tricyclic antidepressant, a Na⁺ channel blocking drug (by Day 4 the ECG has returned to normal).



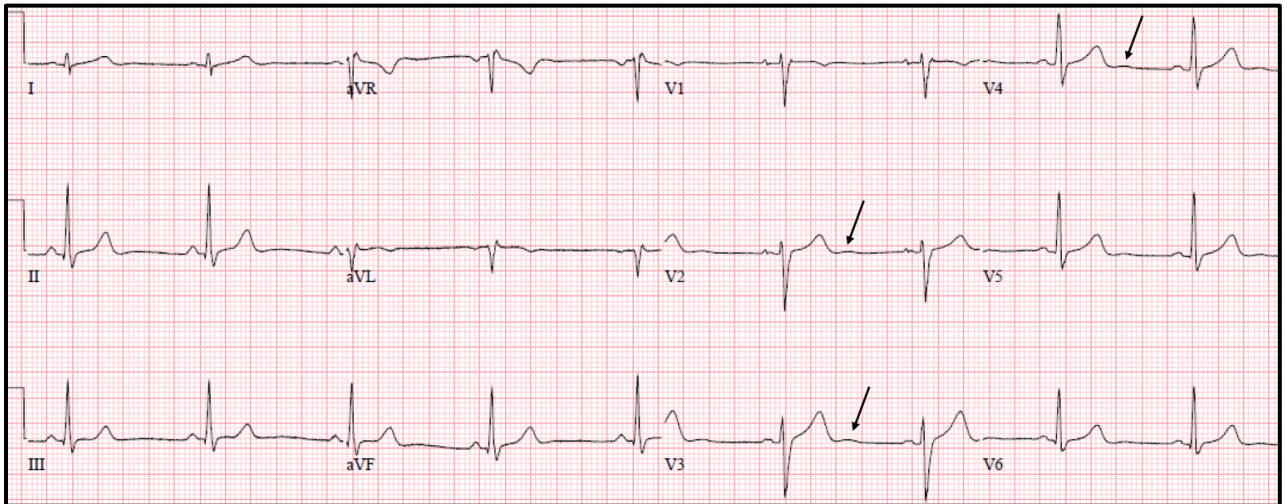
Day 1 illustrates the 'type 1' Brugada pattern in V1-3 with high take-off ST segments with downsloping convex ST; Day 2 shows the 'type 2' pattern in V2 (high ST take-off with 'saddle-back' ST-T morphology); Days 3 and 4 show resolving ST-T changes.

- **Brugada phenocopies are ECG's that look like Brugada but resolve when the specific causes are eliminated.** (see: www.brugadaphenocopy.com)
 - Myocardial ischemia
 - Pericardial and myocardial diseases
 - Metabolic abnormalities (e.g., hypokalemia)
 - External cardiac compression (e.g., tumors, pectus excavatum)

12. U Wave Abnormalities

INTRODUCTION: The U wave is the most neglected wave on the ECG! The **normal U wave** is now thought to be the result of an electrical-mechanical event occurring at the very beginning of diastole when the rapid inflow of blood into the relatively 'empty' ventricles results in small depolarizations in ventricular muscle cells. Normal U waves have the same polarity as the T wave but less than one-third the amplitude of the T wave. Normal U waves are best seen in the mid-precordial leads especially V2 and V3 at slower heart rates. At faster heart rates the P wave often overlaps the U wave resulting in a "**P-on-U**" phenomenon. The normal U wave morphology is asymmetric with the ascending limb moving more rapidly than the descending limb (just the opposite of the normal T wave). When **abnormal** and exaggerated these "*afterdepolarizations*" can be a source of arrhythmias caused by "triggered automaticity"; one example is **torsade de pointes** in patients with long QT syndromes.

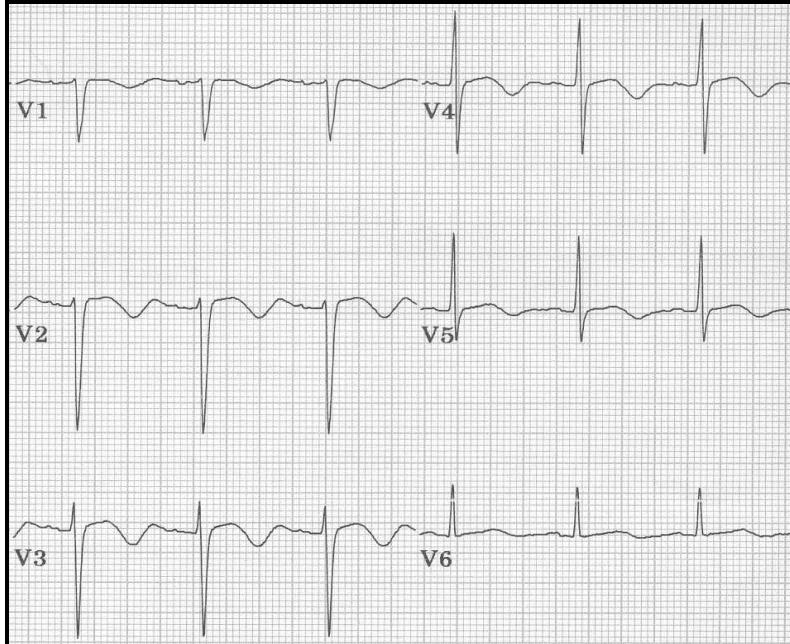
- Normal U waves are illustrated in next ECG (arrows). Look closely after the T waves in V2-4 and note the small upward deflections. That's looking at '**U**' !!



Normal U waves and normal 12-lead ECG

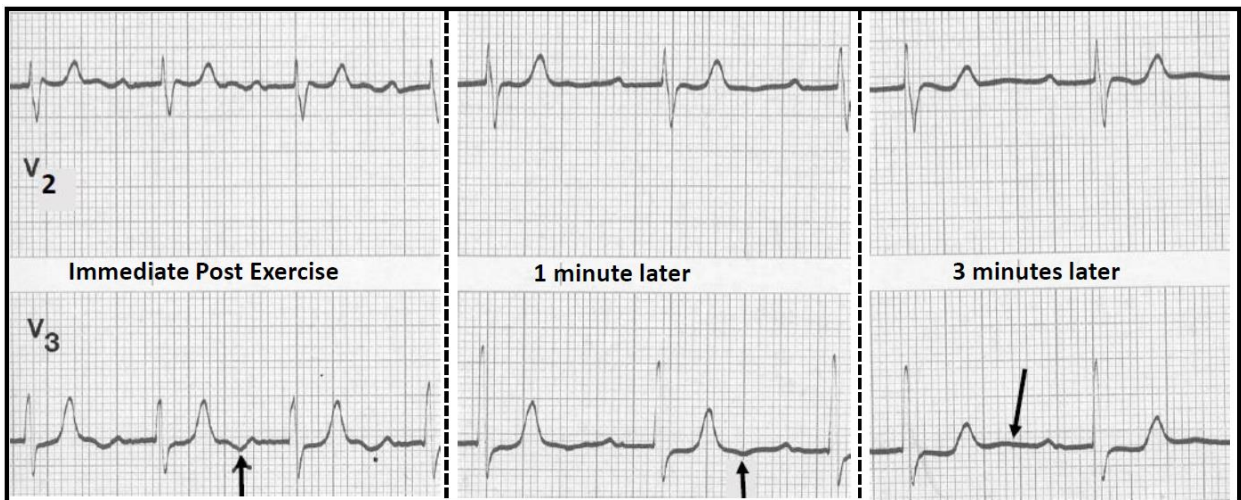
Differential Diagnosis of U Wave Abnormalities

- Prominent upright U waves
 - Sinus bradycardia accentuates the amplitude of U waves (this is a normal finding)
 - Hypokalemia (remember the triad of ST segment depression, low amplitude T waves, and prominent upright U waves)
 - Various drugs including antiarrhythmics (e.g., sotalol)
 - LVH (may see prominent upright or inverted U waves in left precordial leads)
 - CNS disease and other causes of long QT (T-U fusion waves); see ECG below.



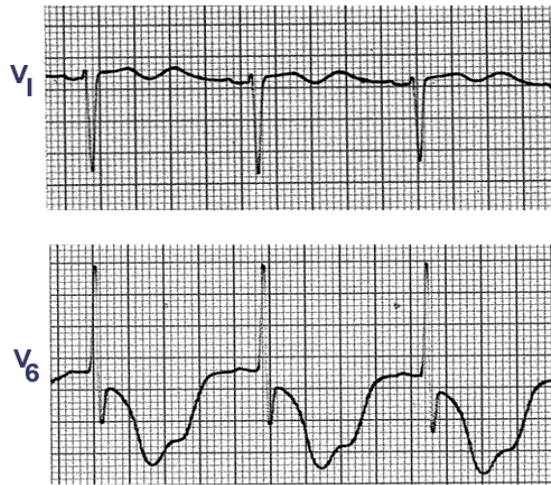
CNS disease with prominent U waves

- Negative or "inverted" U waves
 - Ischemic heart disease (often indicating left main or LAD disease)
 - Myocardial infarction (in leads with pathologic Q waves)
 - During episode of acute ischemia (angina or exercise-induced ischemia; see next ECG)
 - Post extrasystolic (i.e., after a PVC) in patients with coronary heart disease
 - During coronary artery spasm (Prinzmetal's angina)
 - Some cases of left ventricular hypertrophy



Negative U waves appear immediately after exercise and one minute later; U waves normalize at 3 minutes post exercise (arrows). This finding is highly specific for significant LAD coronary artery disease (95% specificity but only 15% sensitivity). This unlikely marker of ischemia is frequently missed because very few ECG readers look for it. ***Cherchez le 'U'!***

- Nonischemic causes: some cases of LVH or RVH (usually in leads with prominent R waves)
 - Some patients with LQTS (see below: Lead V6 shows giant negative TU fusion wave in patient with LQTS; a prominent upright U wave is seen in lead V1.



'U'-nbelievable



'Sixteen Knights' (Frank Yanowitz)