


Wrist and Hand Complaints

Charles S. Day, M.D., M.B.A.

Associate Professor in Orthopedic Surgery
Director, Orthopedic Curriculum
Harvard Medical School

Hand & Upper Extremity Surgery
Beth Israel Deaconess Medical Center

Primary Care Internal Medicine 2015

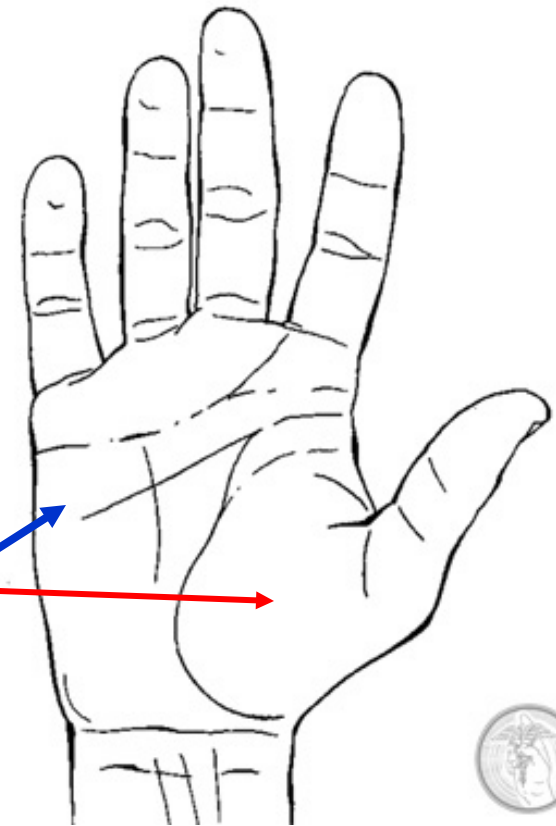


Outline

- Terminology and Axes of Motion
- Fundamental Surface Anatomical Landmarks
- Physical Examination & Diagnoses for PCP's

Terminology

- Hand
 - Dorsal surface
 - Volar or palmar surface
 - Radial and ulnar borders
- Palm
 - Thenar area
 - Mid-palm area
 - Hypothenar area



Palmar view of the hand

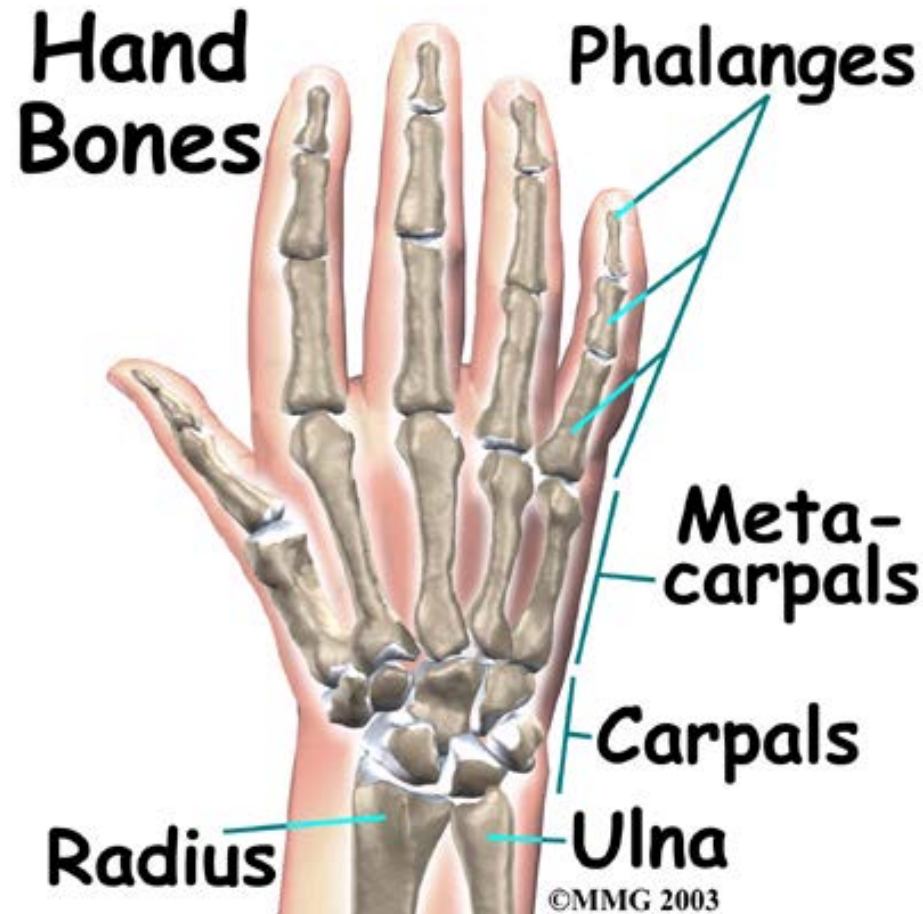Terminology

- **Fingers**

- Thumb, index, middle/ long, ring, & small (1st to 5th)

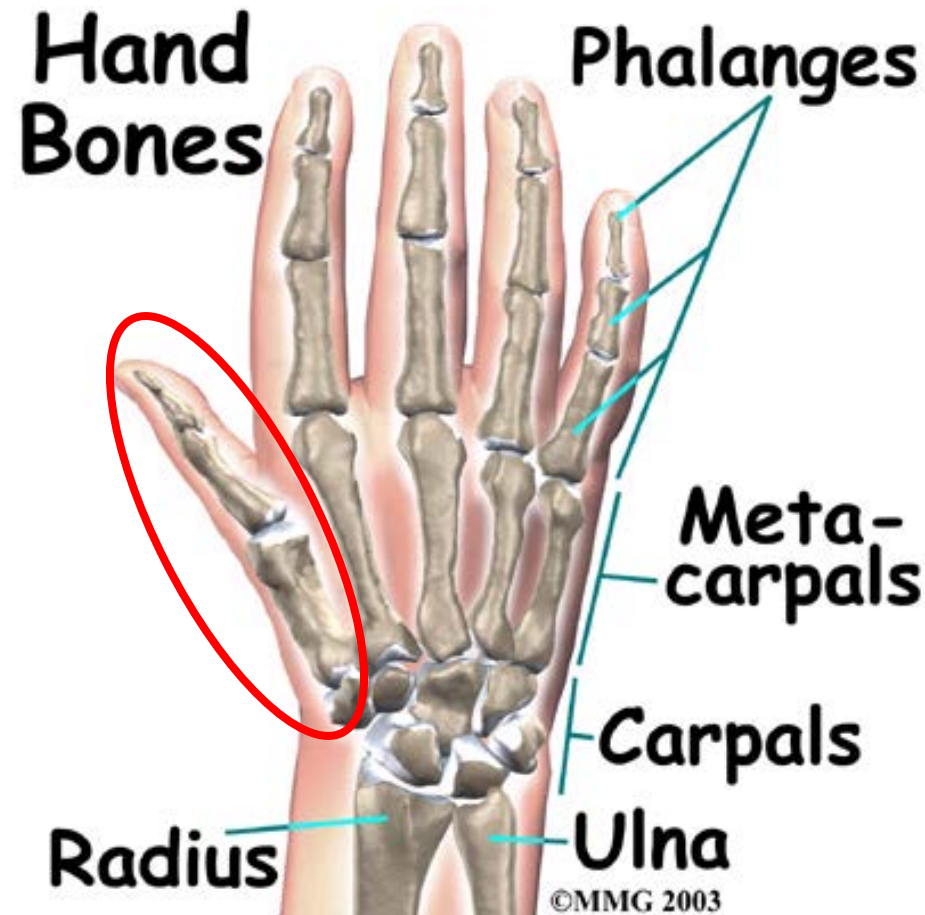
- **Each digit (except thumb)**

- 3 phalanges (prox, middle, distal)
- metacarpal



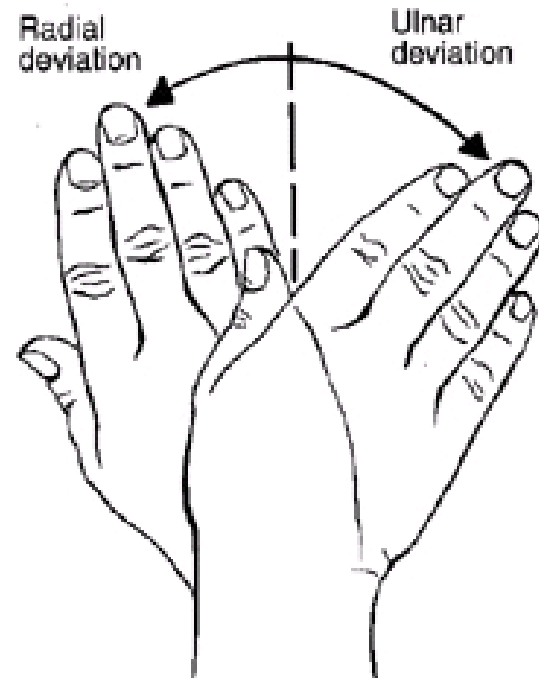
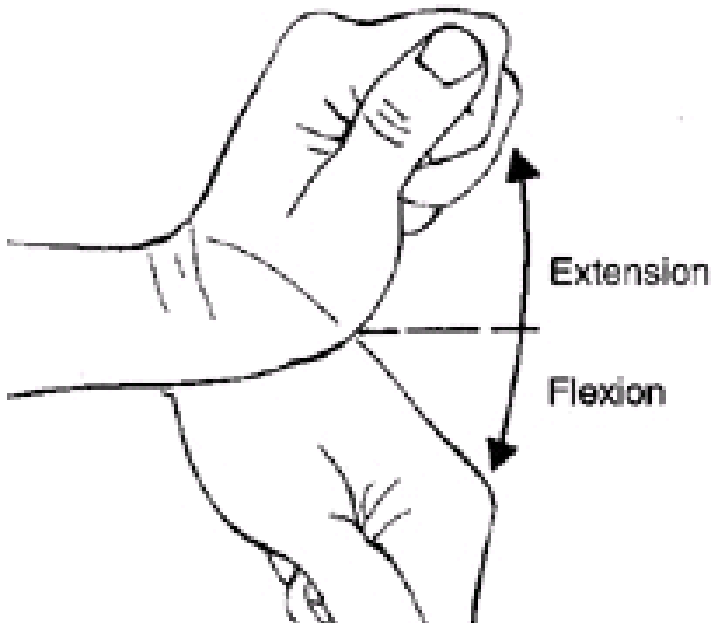
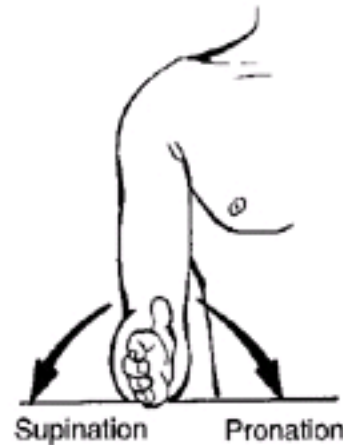
Terminology

- **Each finger has three joints:**
 - Metacarpophalangeal (MP)
 - Proximal interphalangeal (PIP)
 - Distal interphalangeal (DIP)
- **Thumb**
 - Two phalanges & two joints (MP, IP)



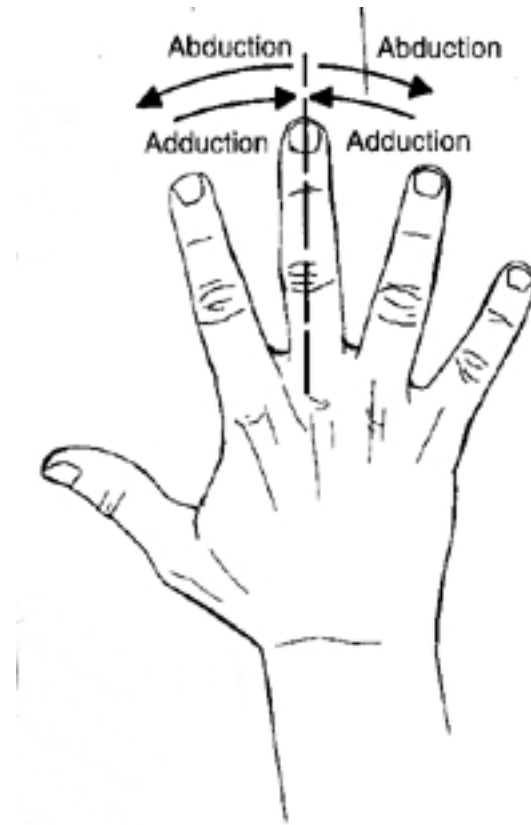
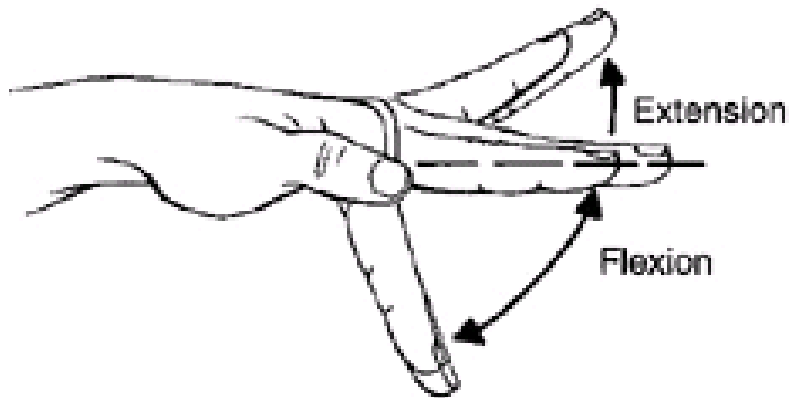
Hand Motion

- **Standardized**
 - Forearm
 - Wrist



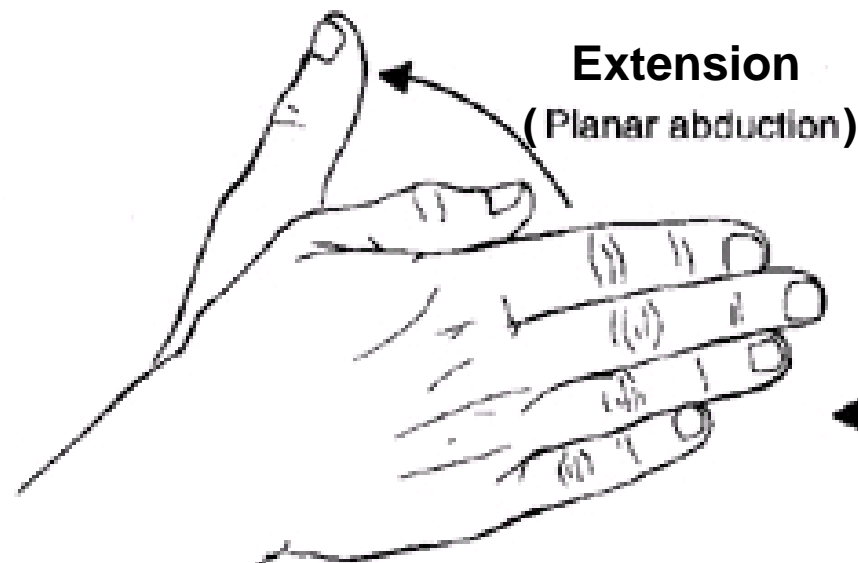
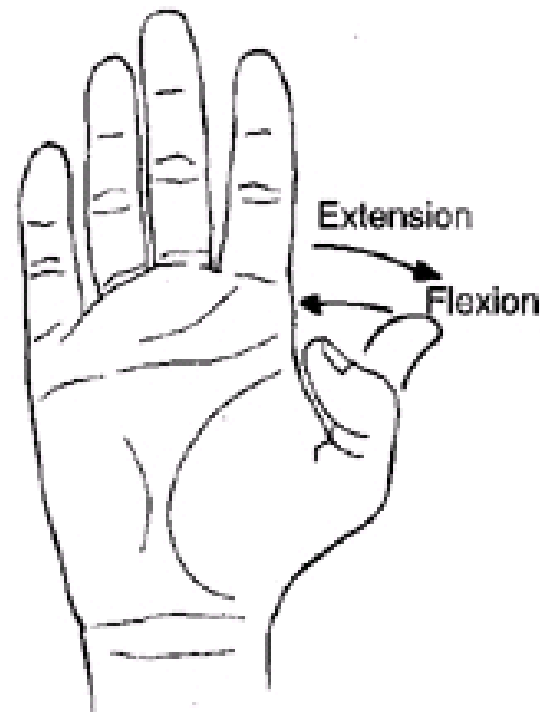
Hand Motion

- **Standardized**
 - Digits
- **Center of hand**
 - Long finger ray



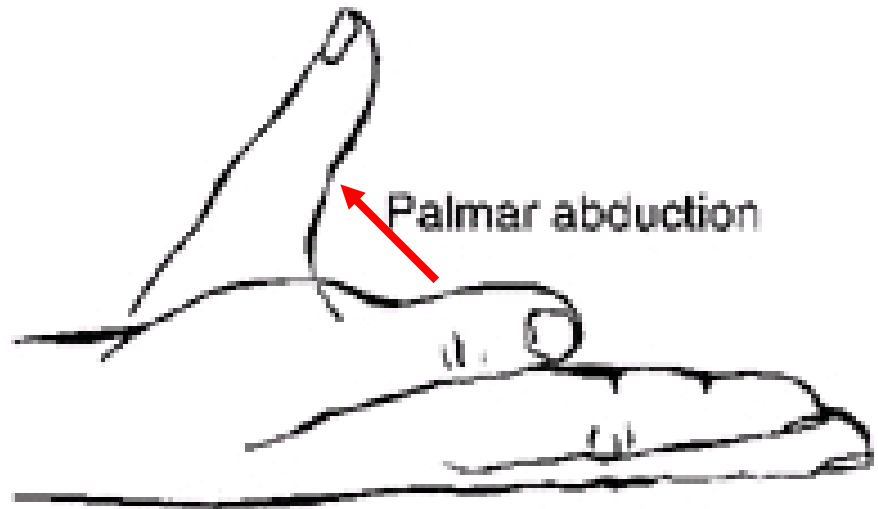
Thumb Motion

- Standardized
 - Flexion
 - Extension
(Planar abduction)



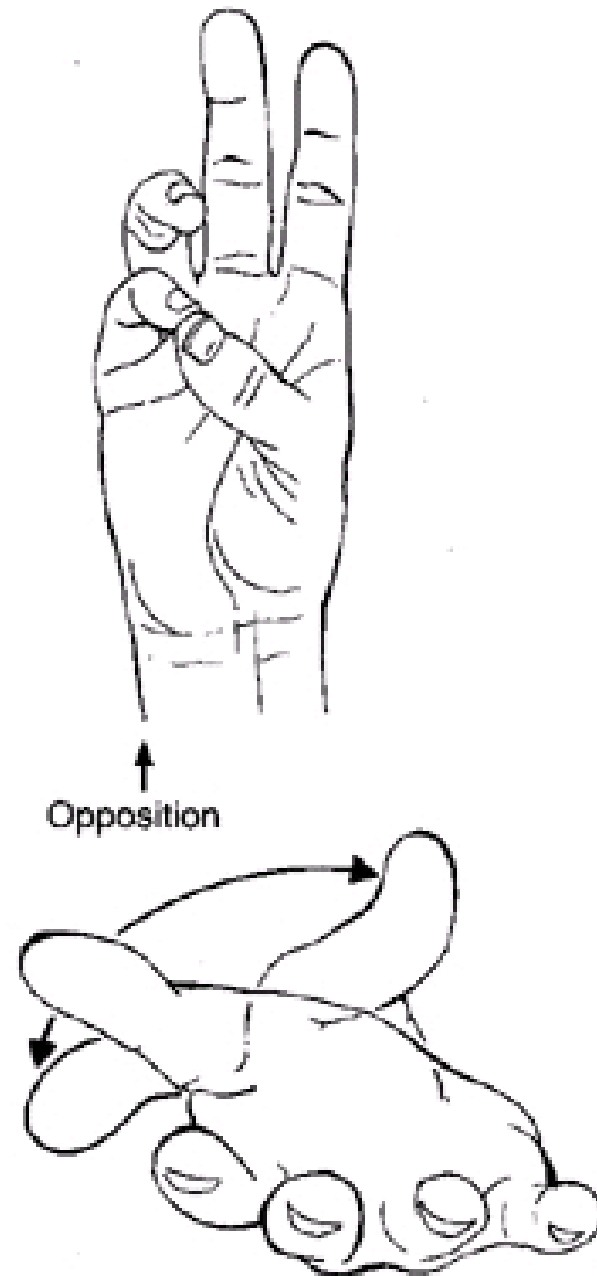
Thumb Motion

- Standardized
 - Abduction
(Palmar)



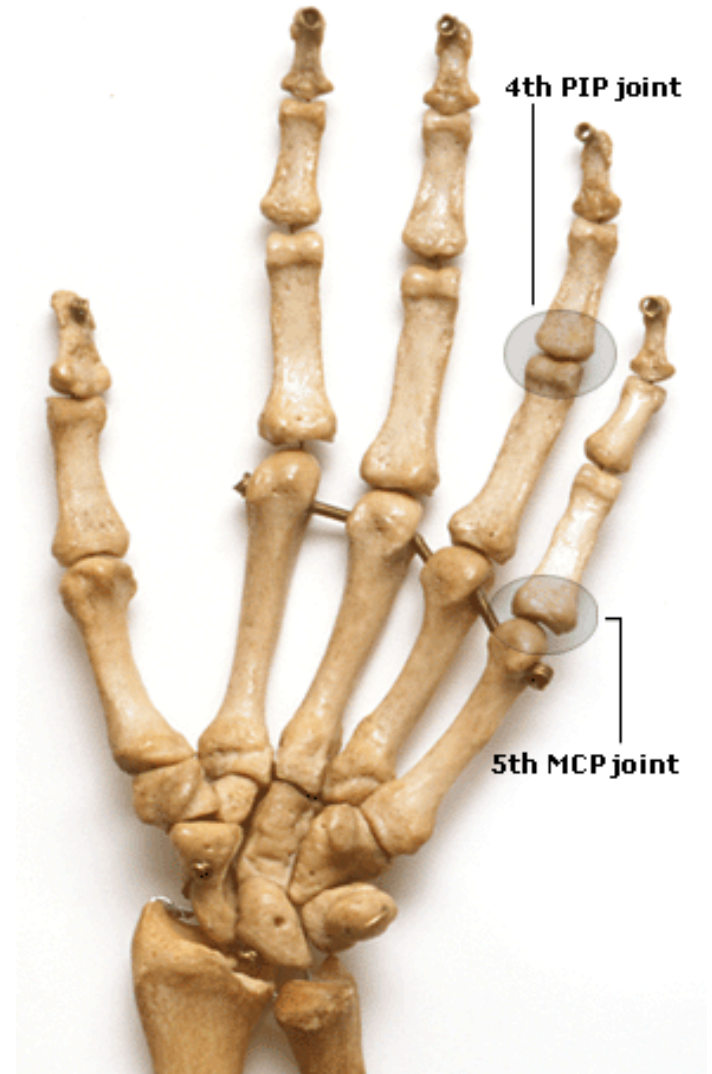Thumb Motion

- Standardized
 - Opposition
 - Abduction
 - Flexion
(Adduction)
 - Pronation



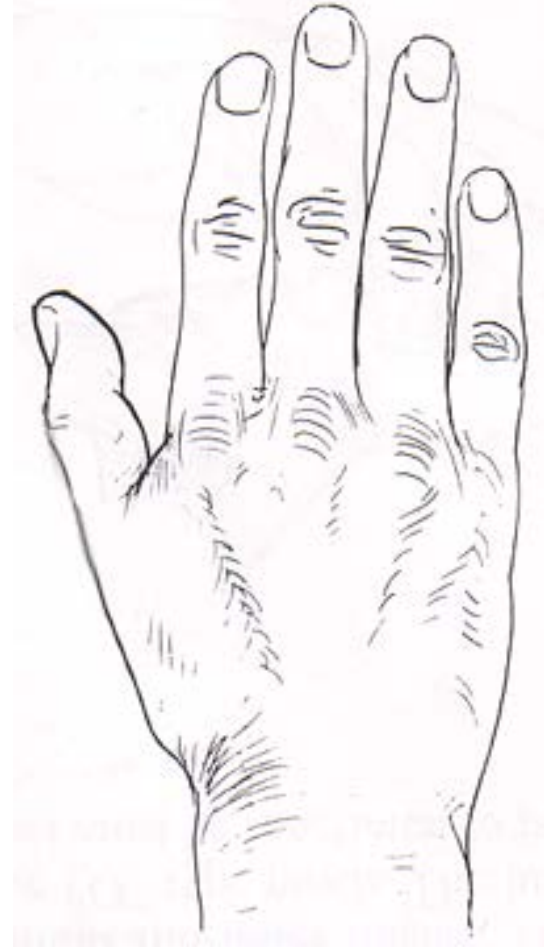Surface Anatomy of Hand

- Bones
 - Metacarpal
 - Phalanges
- Joints
 - DIP, PIP, IP, MCP

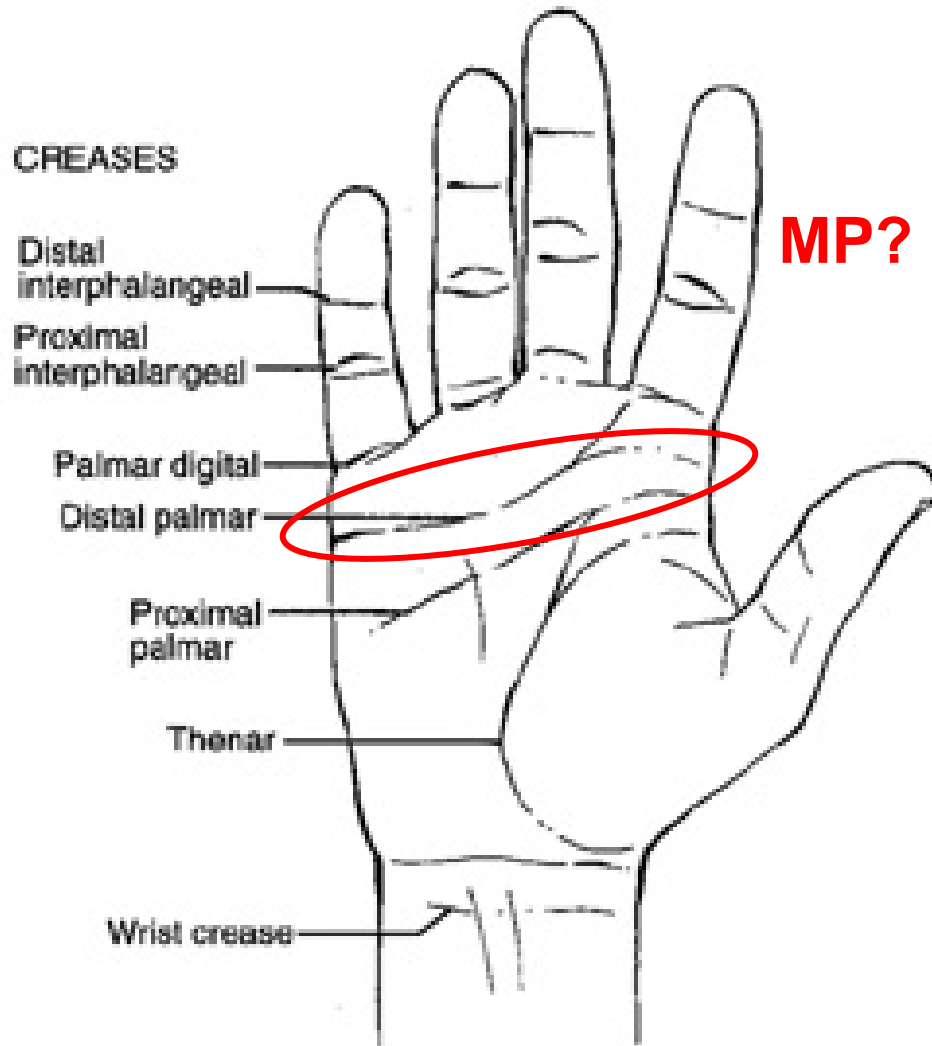


Dorsal Surface Anatomy

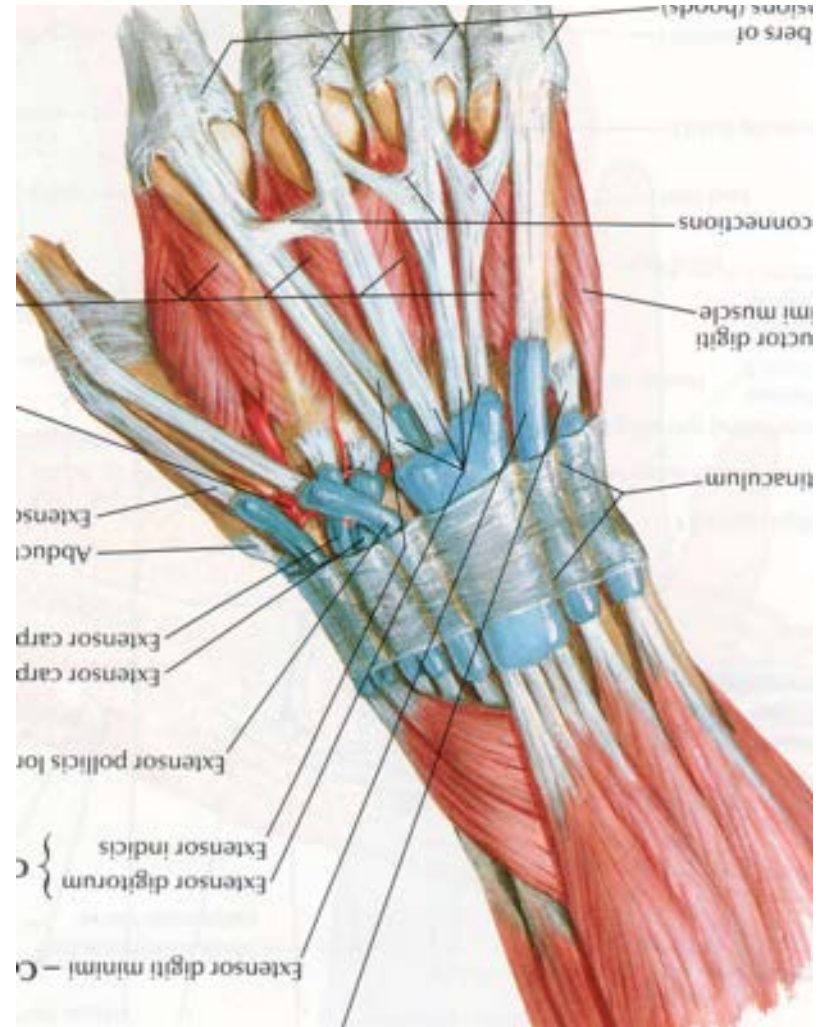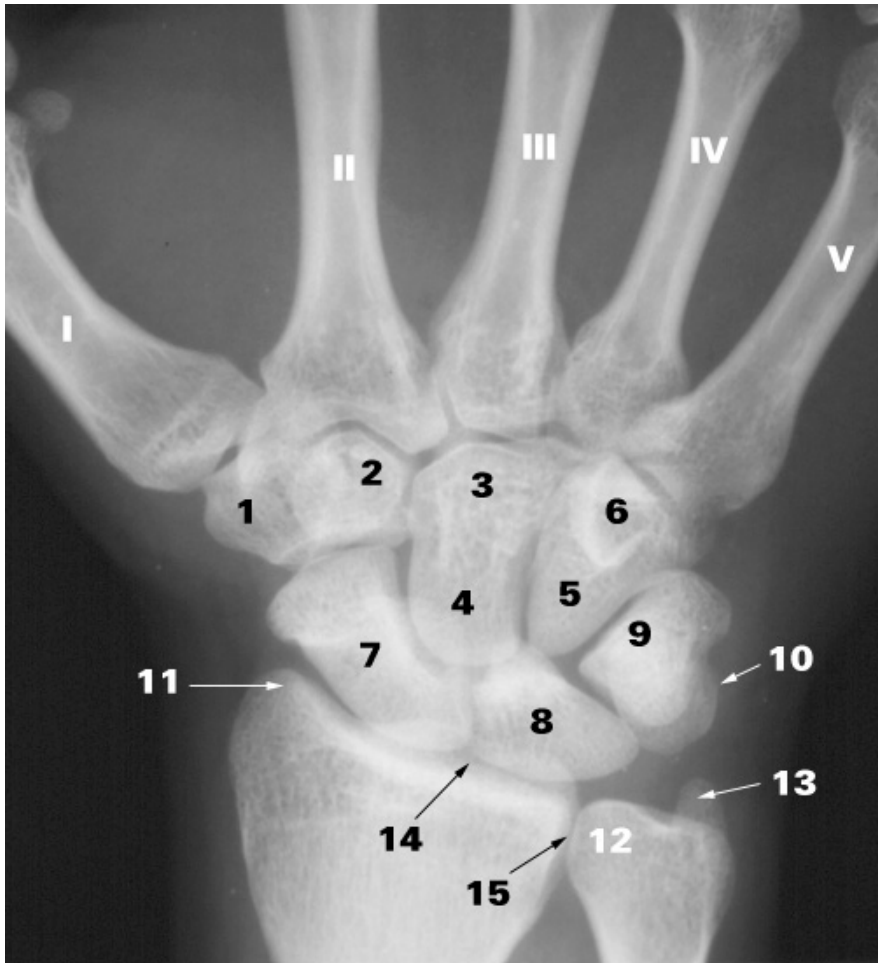
- Bones
 - Metacarpal
 - Phalanges
- Joints
 - DIP, PIP, IP, MP



Palmar Surface Anatomy



Wrist

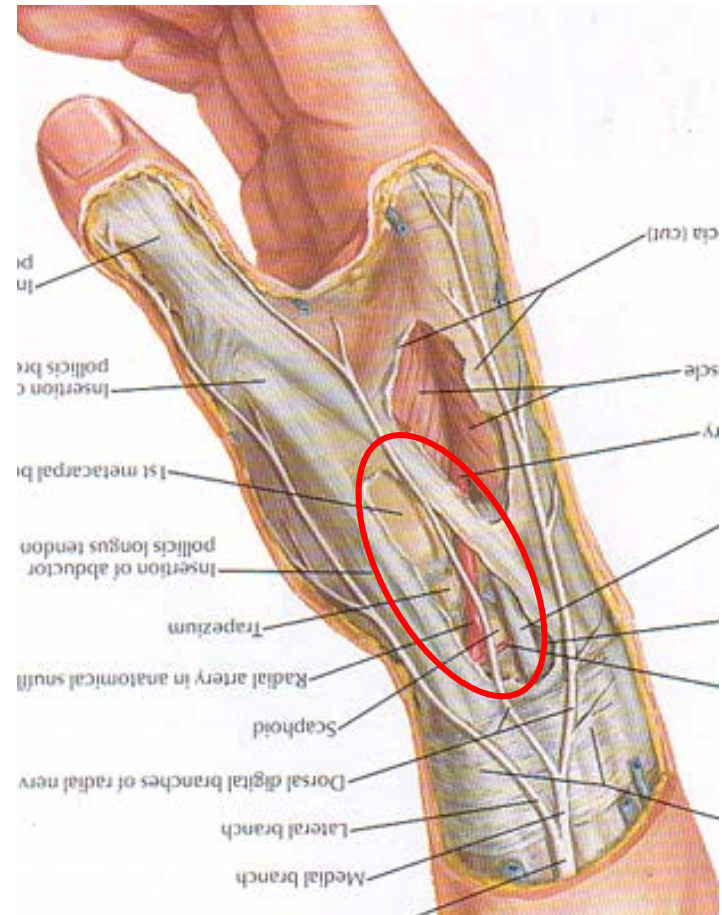


Anatomical Structures of the Wrist

- # bones: 15
- # joints: 17
- # tendons: 24 (25)

Surface Anatomy of Wrist

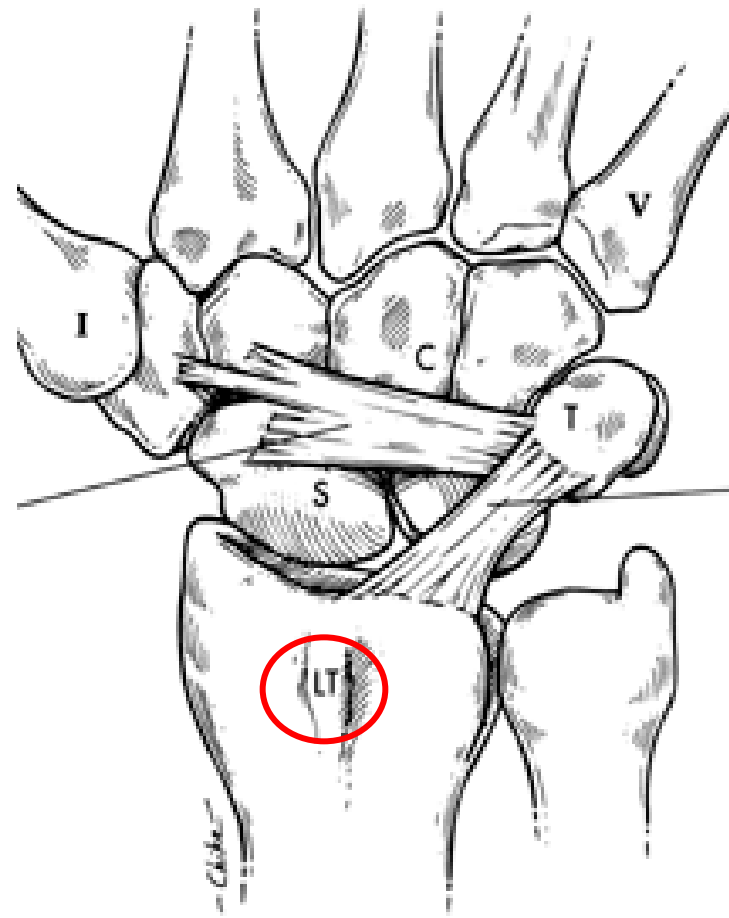
- First landmark:
 - Snuff box
 - CMC thumb
 - Thumb Extensors
 - Scaphoid



Surface Anatomy of Wrist

Dorsum of the Wrist

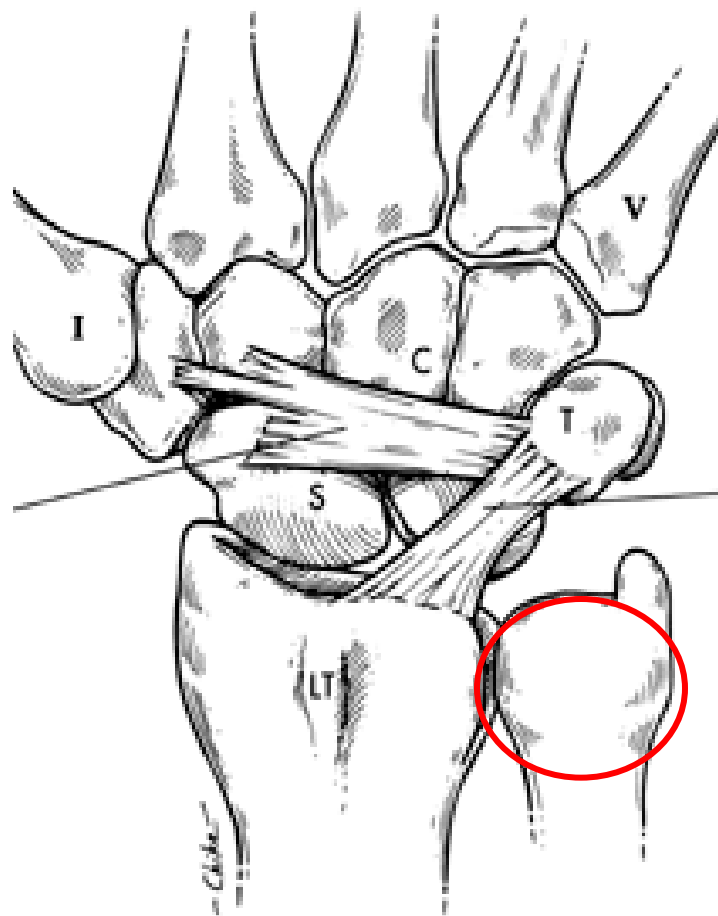
- Second Landmark
 - Lister's tubercle
 - Distal Radius
 - Scapho-Lunate Ligament



Surface Anatomy of Wrist

- Third Landmark
 - Distal Ulna
 - Extensor Carpi Ulnaris (ECU) Tendonitis
 - Triangular Fibro-Cartilage Complex (TFCC) ligament

Dorsum of the Wrist



Surface Anatomy Summary

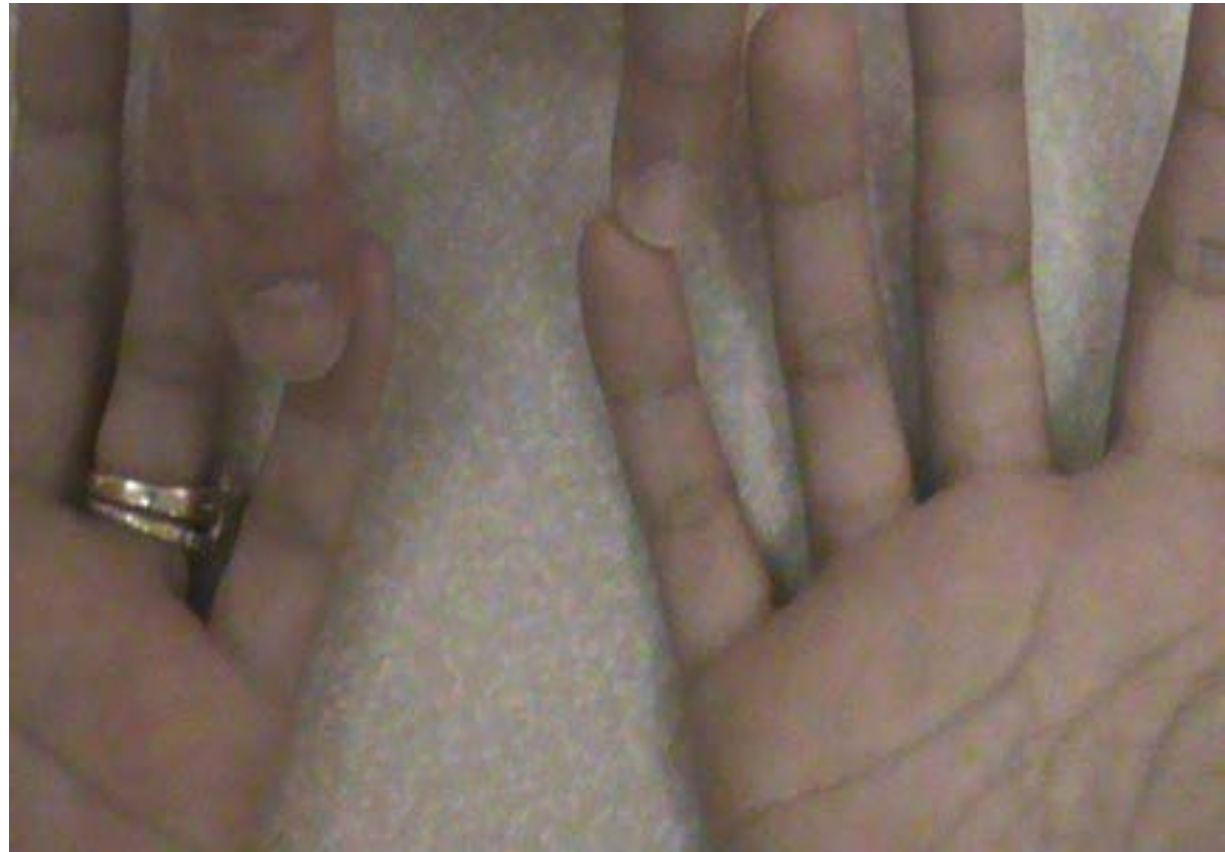- Volar MP joints
- PIP and DIP Joints
- Metacarpals
- Phalanges
- **Snuffbox**
- **Lister's Tubercle**
- **Distal Ulna**

P.E. & Diagnoses of Hand & Wrist Pain

- 47 y.o. woman c/o 6 months h/o of numbness and tingling in right hand
 - Wakes her up at night

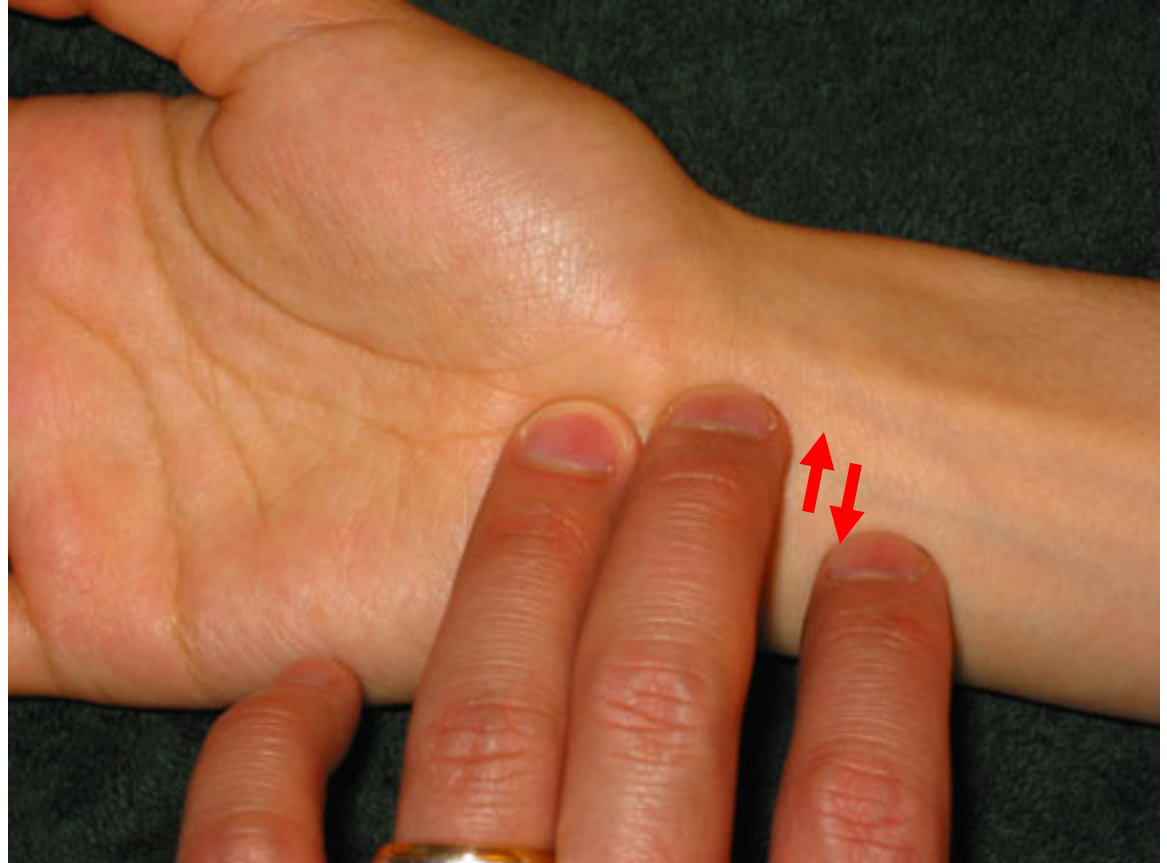Finger Sensation to Light Touch

- Normal?
- Symmetric?



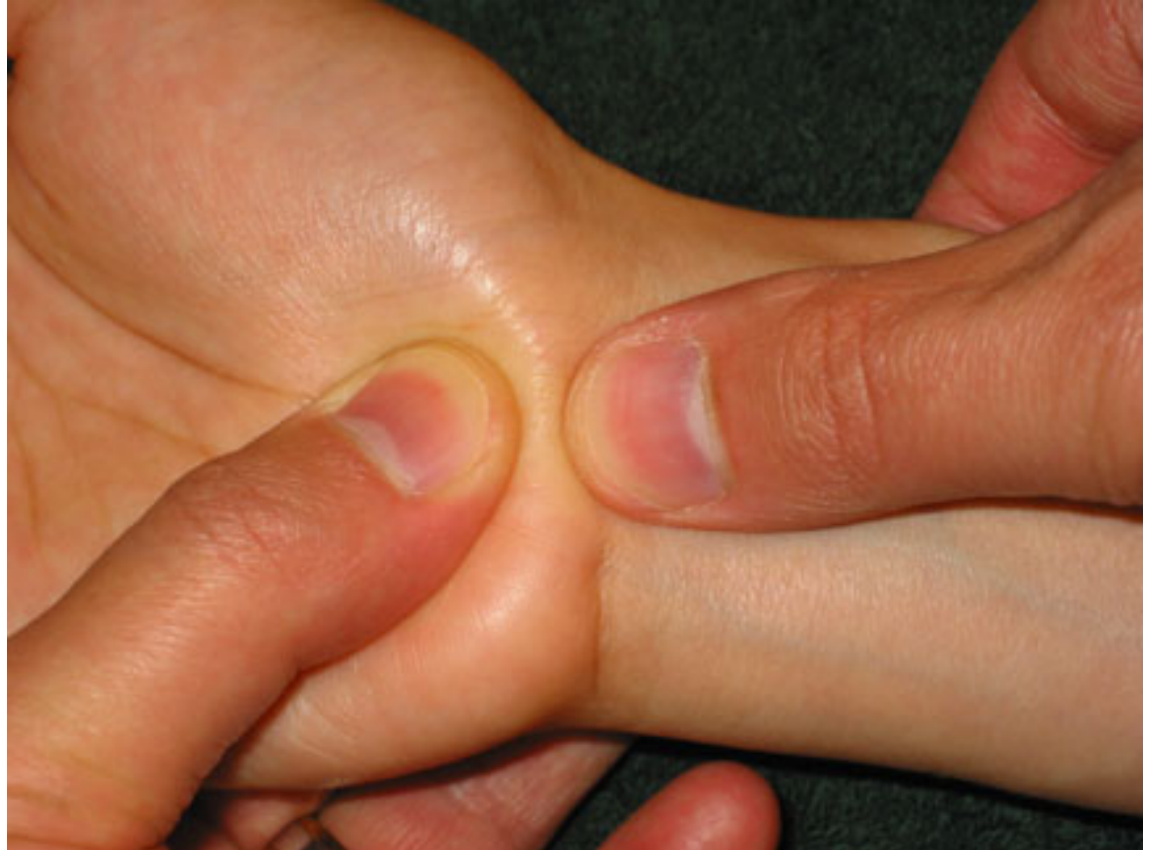Carpal Tunnel Syndrome

- Tinel's



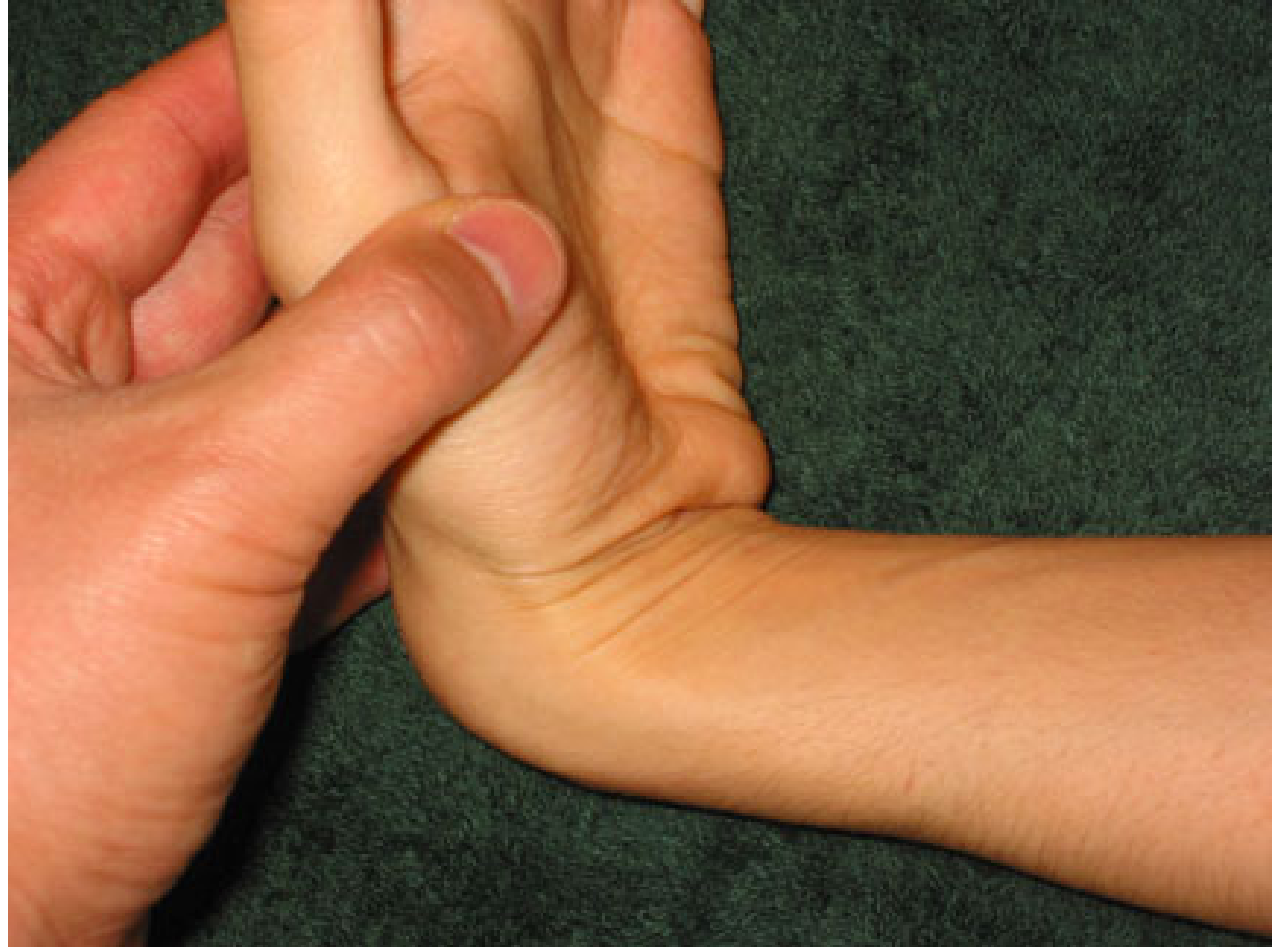Carpal Tunnel Syndrome

- Median Nerve Compression (Durkin)

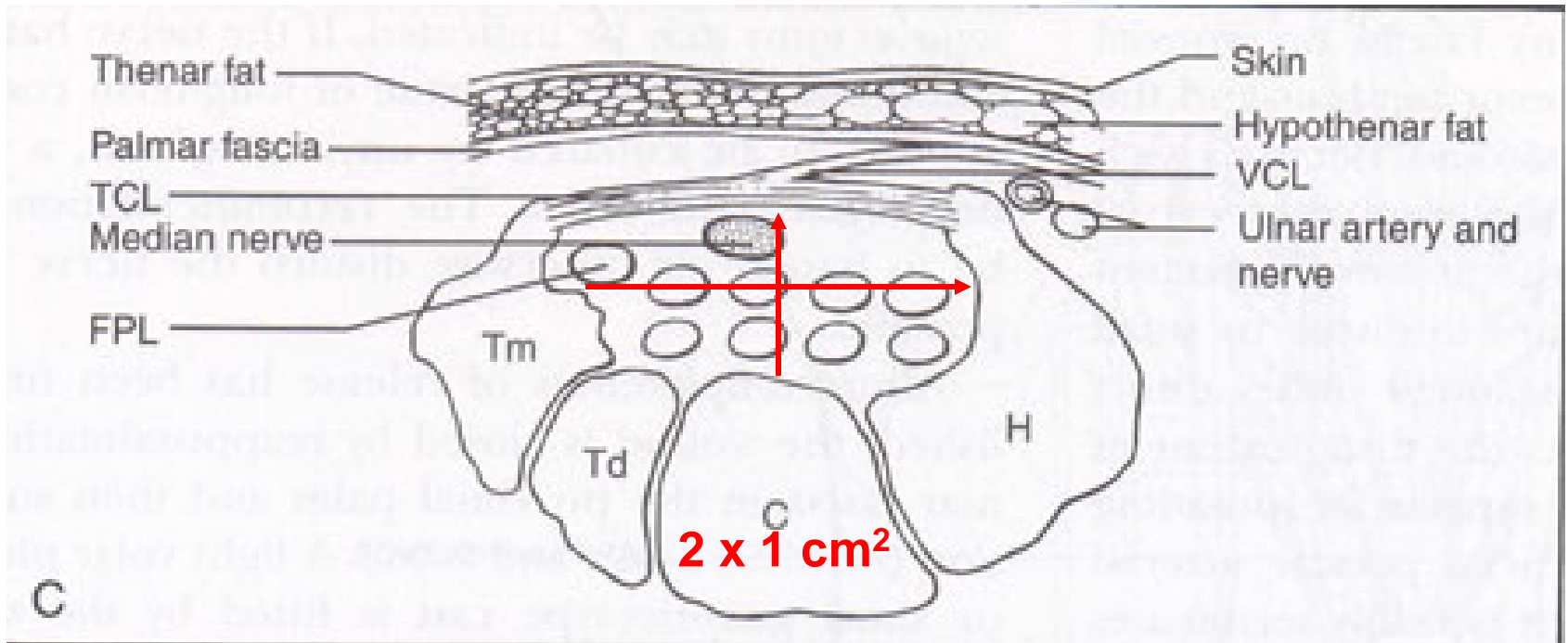


Carpal Tunnel Syndrome

- Phalen's



Carpal Tunnel Syndrome



CTS Treatments

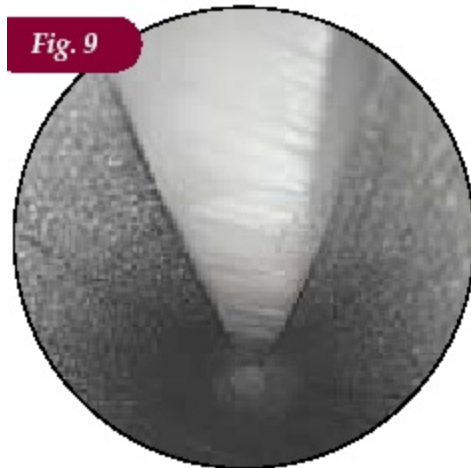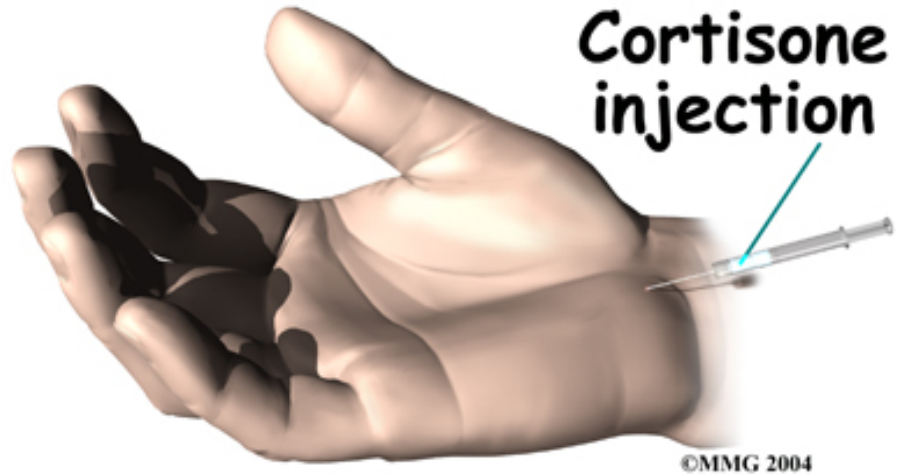
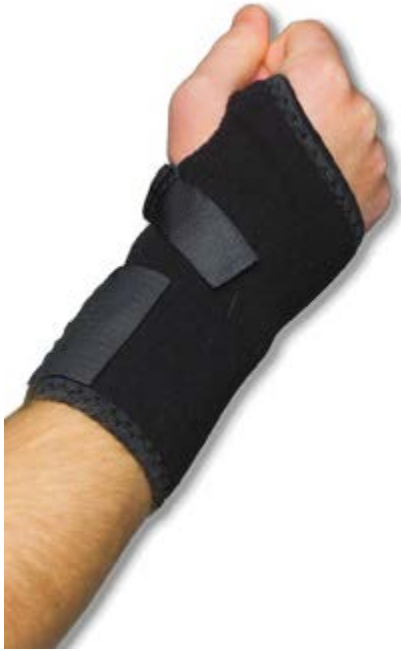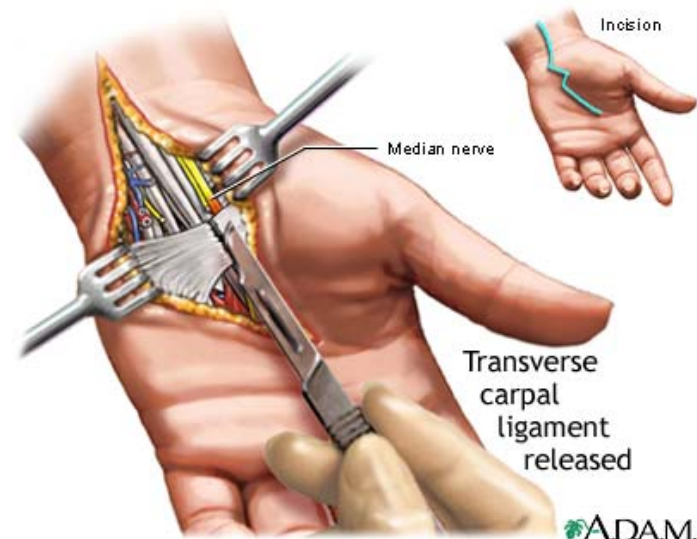


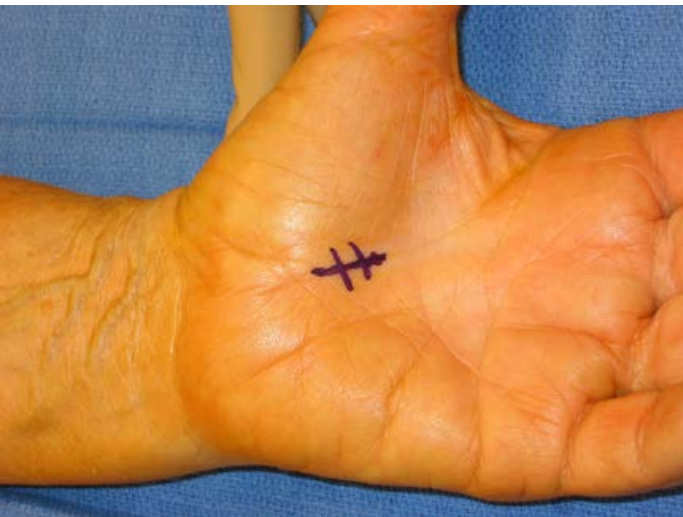Fig. 9



Clinical messages

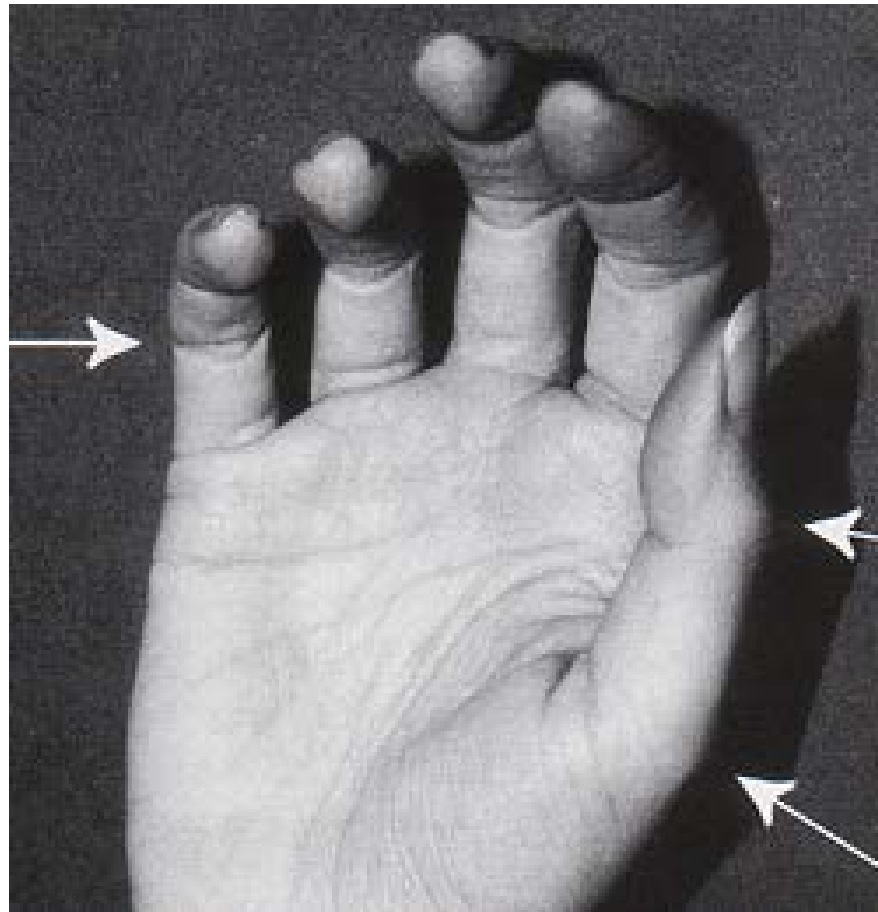
- Clinician
 - Ask about night pain
 - May lead to irreversible median nerve damage
 - Refer to hand surgeon if splint not helpful
- Patient
 - Start with wrist splints at night
 - F/u if symptoms no better

- 53 y.o. male with diabetes c/o clicking in right ring finger joint
 - Worse in the mornings
 - Sometimes the finger “sticks”

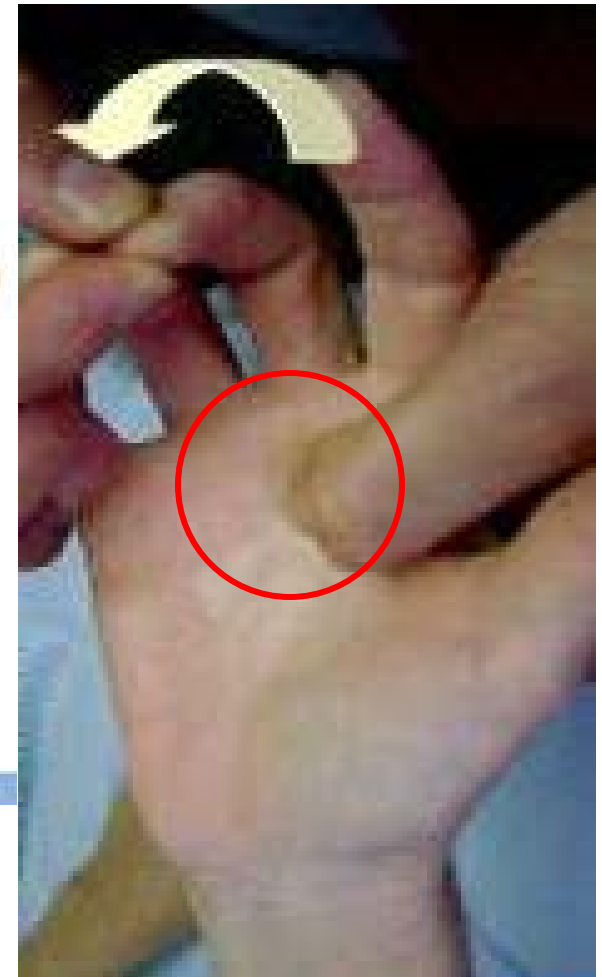
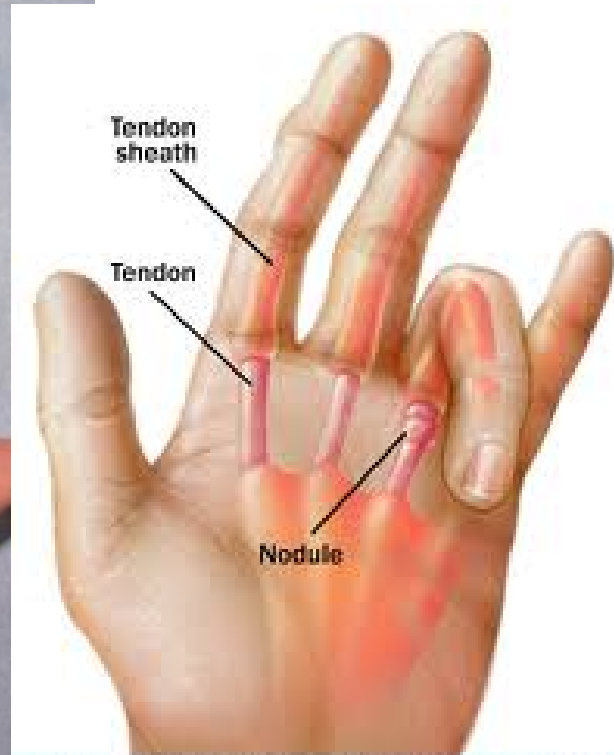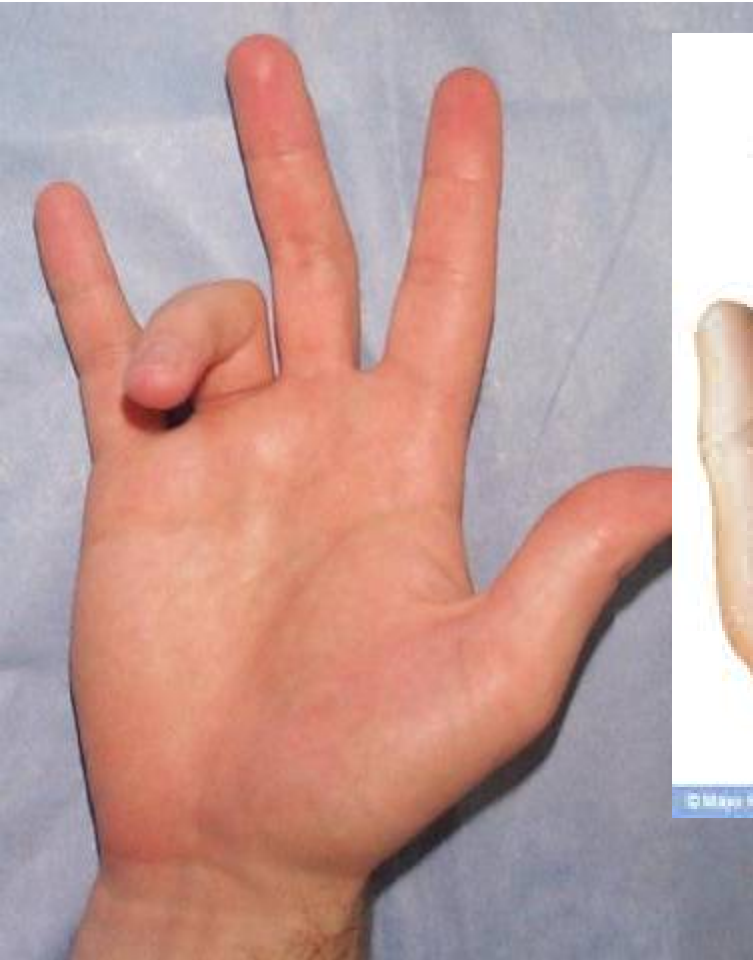
Trigger Finger

Flexor Tendon

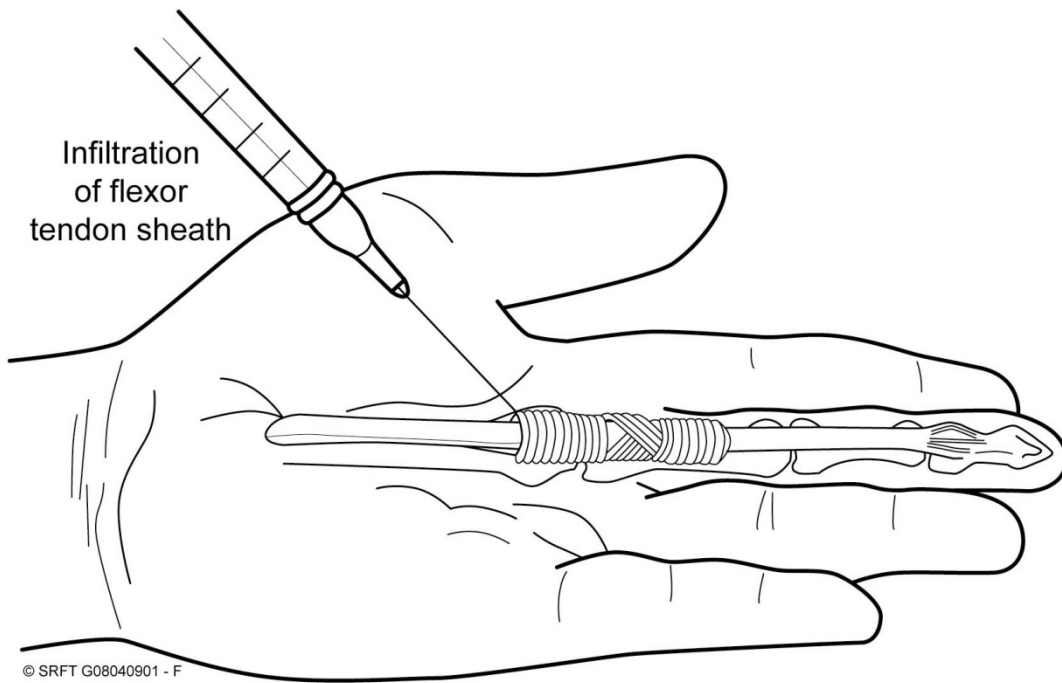
- Normal Finger Cascade



Flexor Tenosynovitis (Trigger Finger)



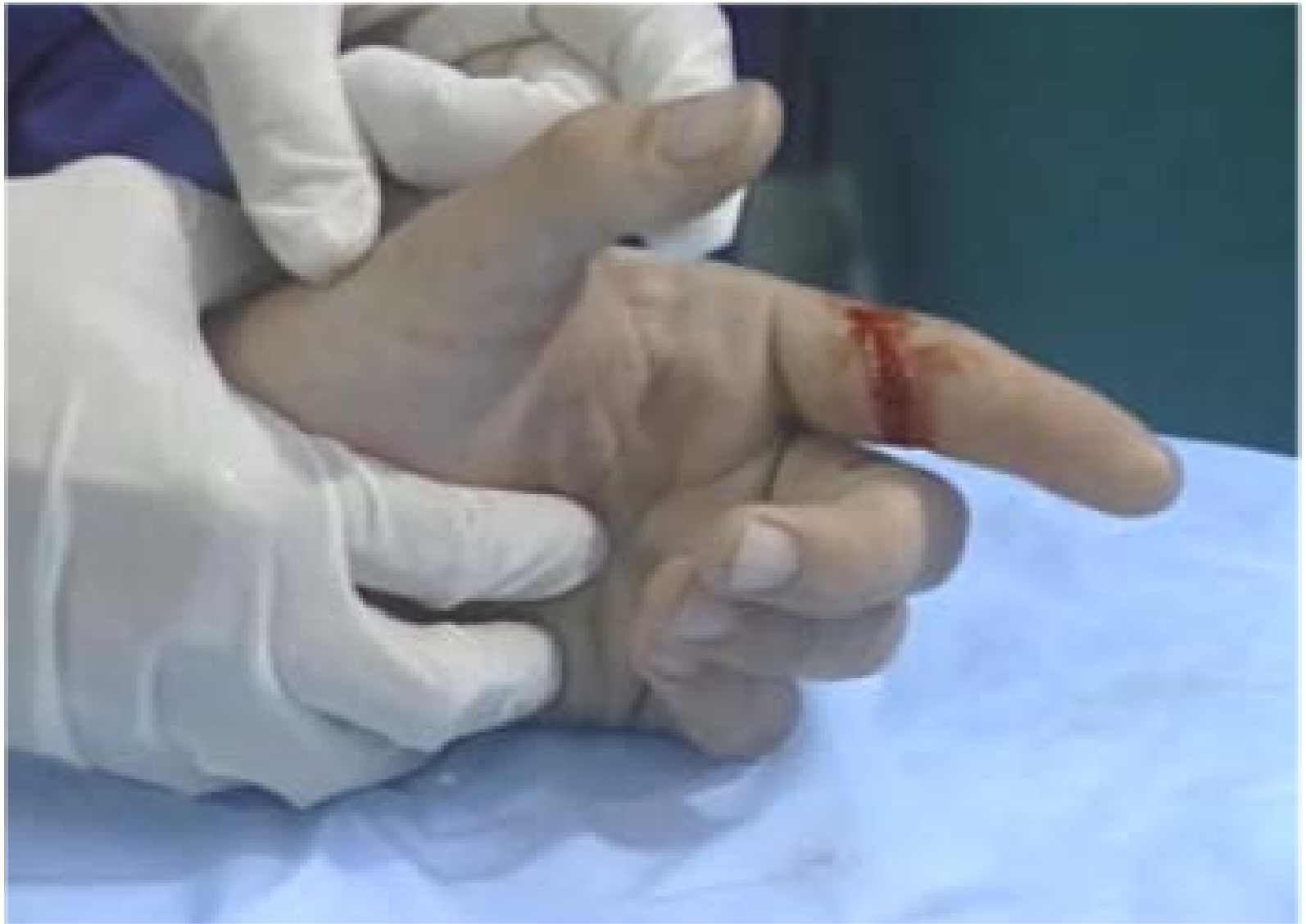Treatment



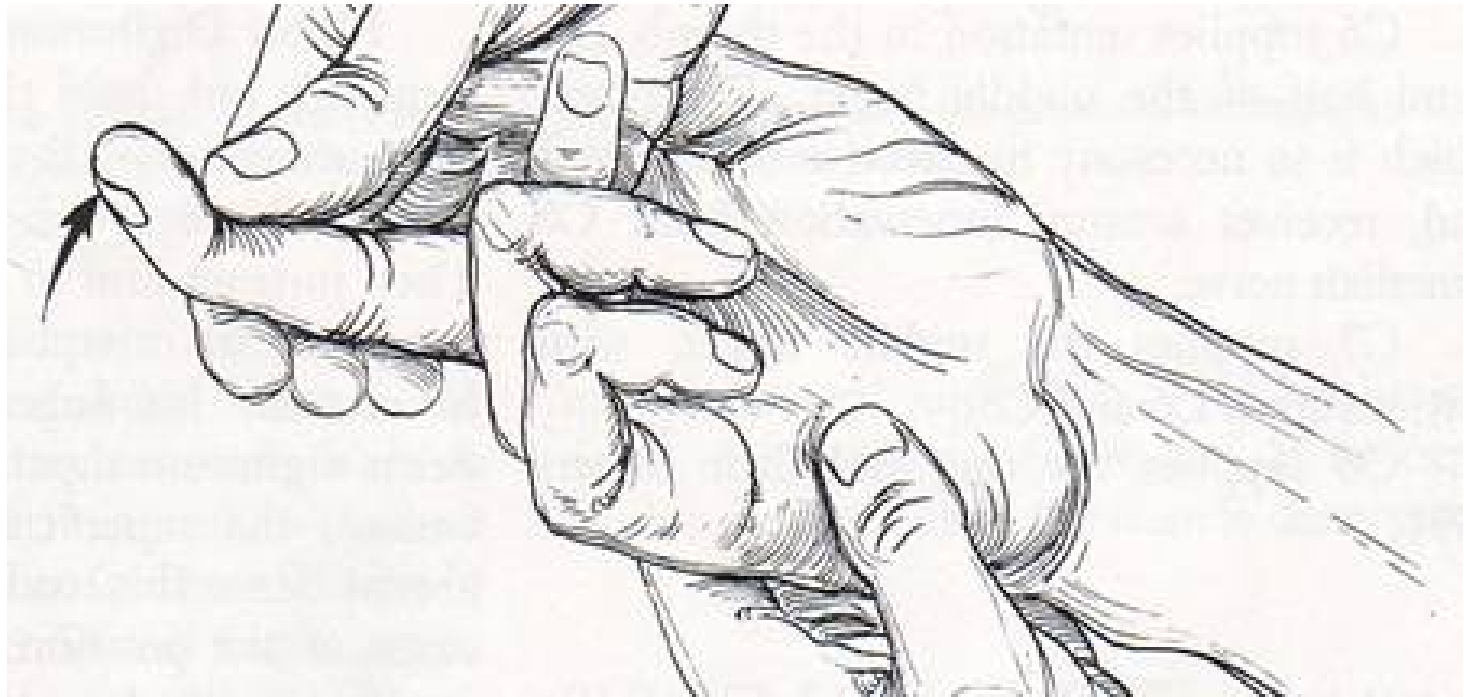Clinical messages

- Clinician
 - Examine the volar MP joint of the finger
 - Increased risk in diabetics and rheumatoids
- Patient
 - Therapy is unreliable
 - Steroid injection has 70% success rate

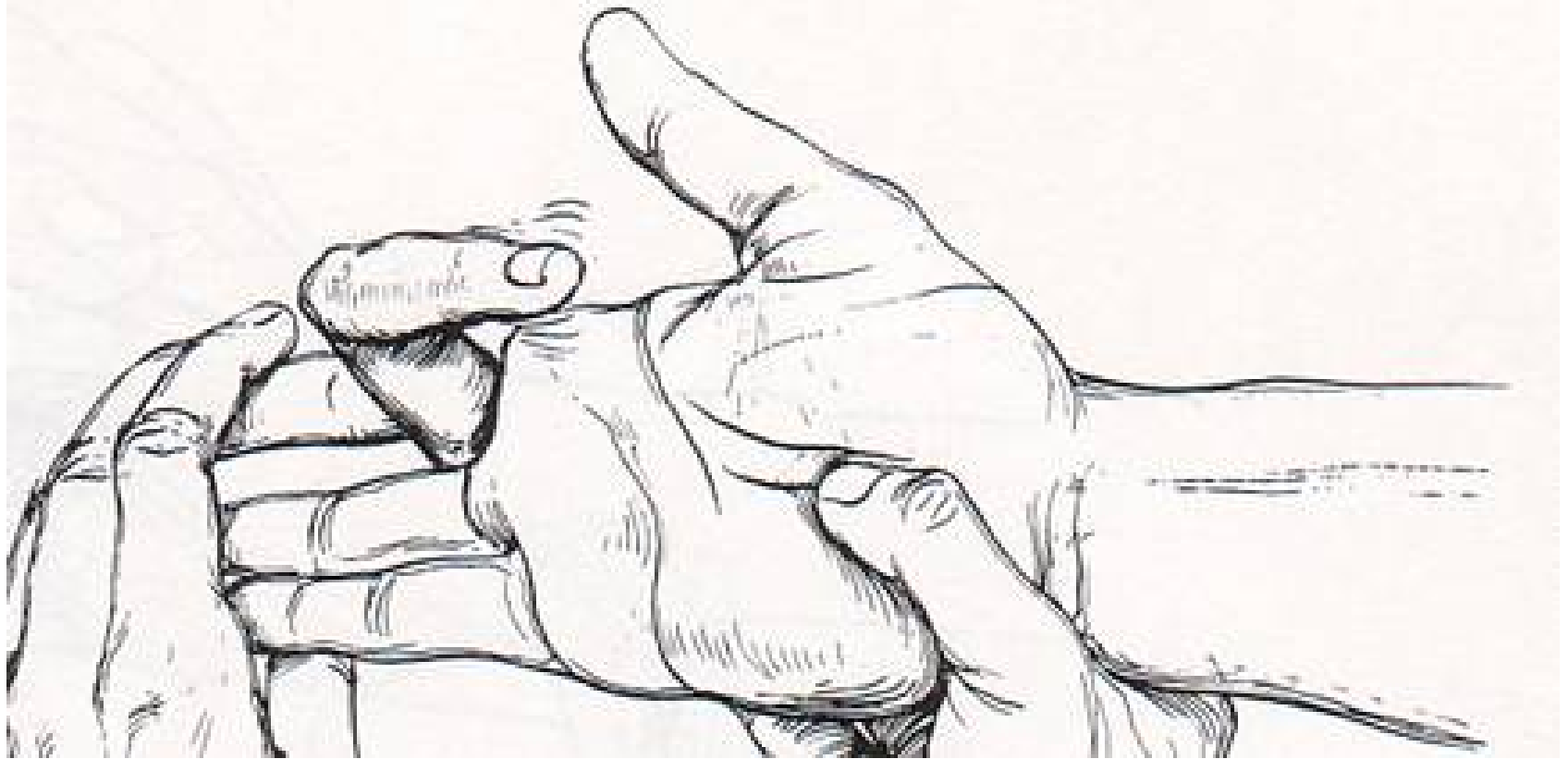
- 27 y.o. male RHD (right-hand dominant) male accidentally cut his left index finger while opening up frozen hamburger patties



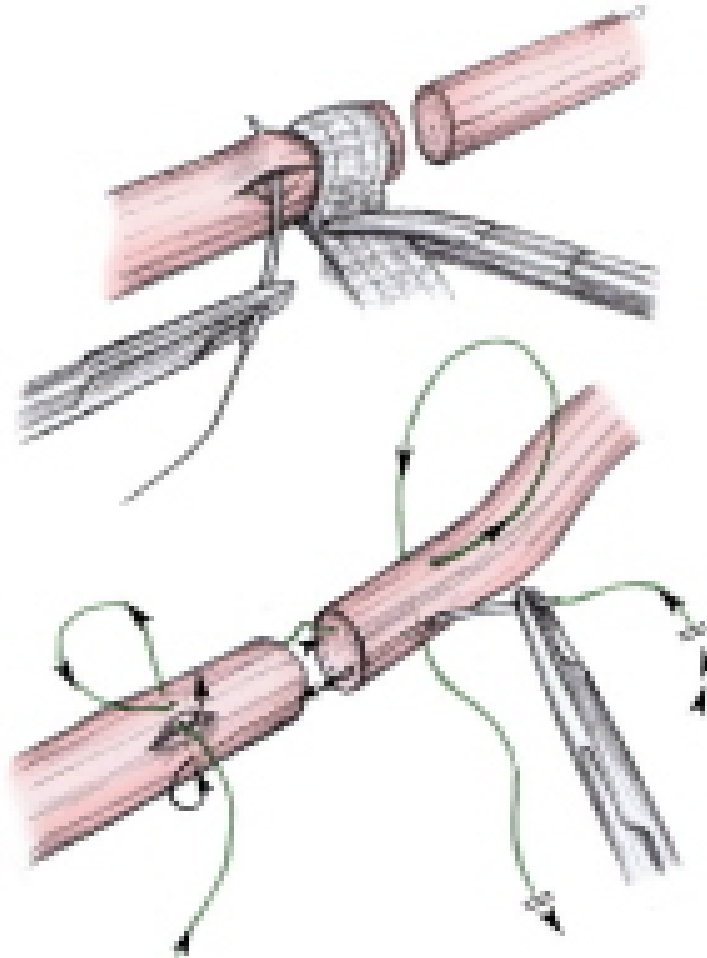
Flexor Digitorum Profundus



Flexor Digitorum Superficialis



Treatment



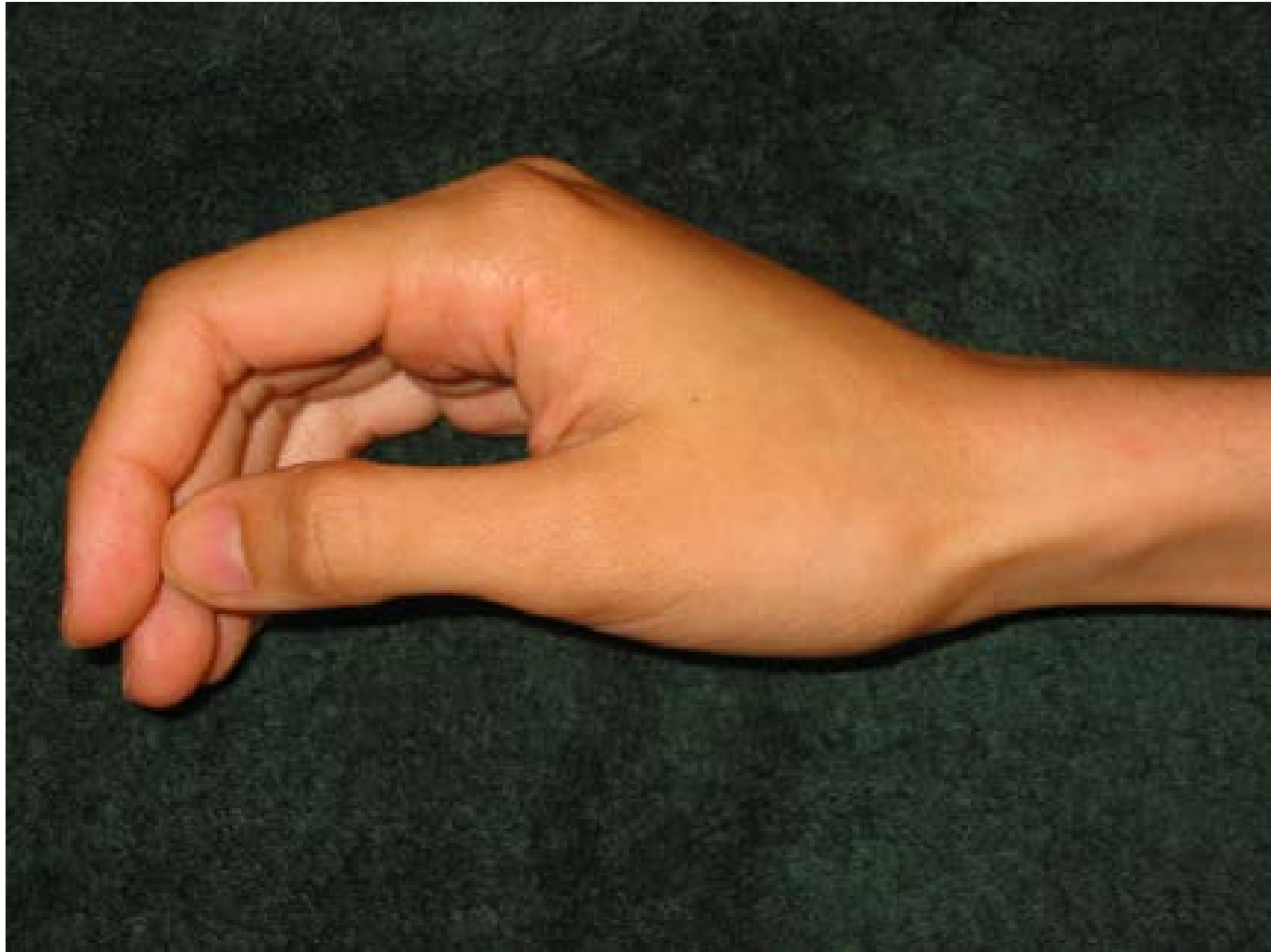
Clinical messages

- Clinician
 - Urgent hand surgery referral
 - Check digital sensation
- Patient
 - May need surgery

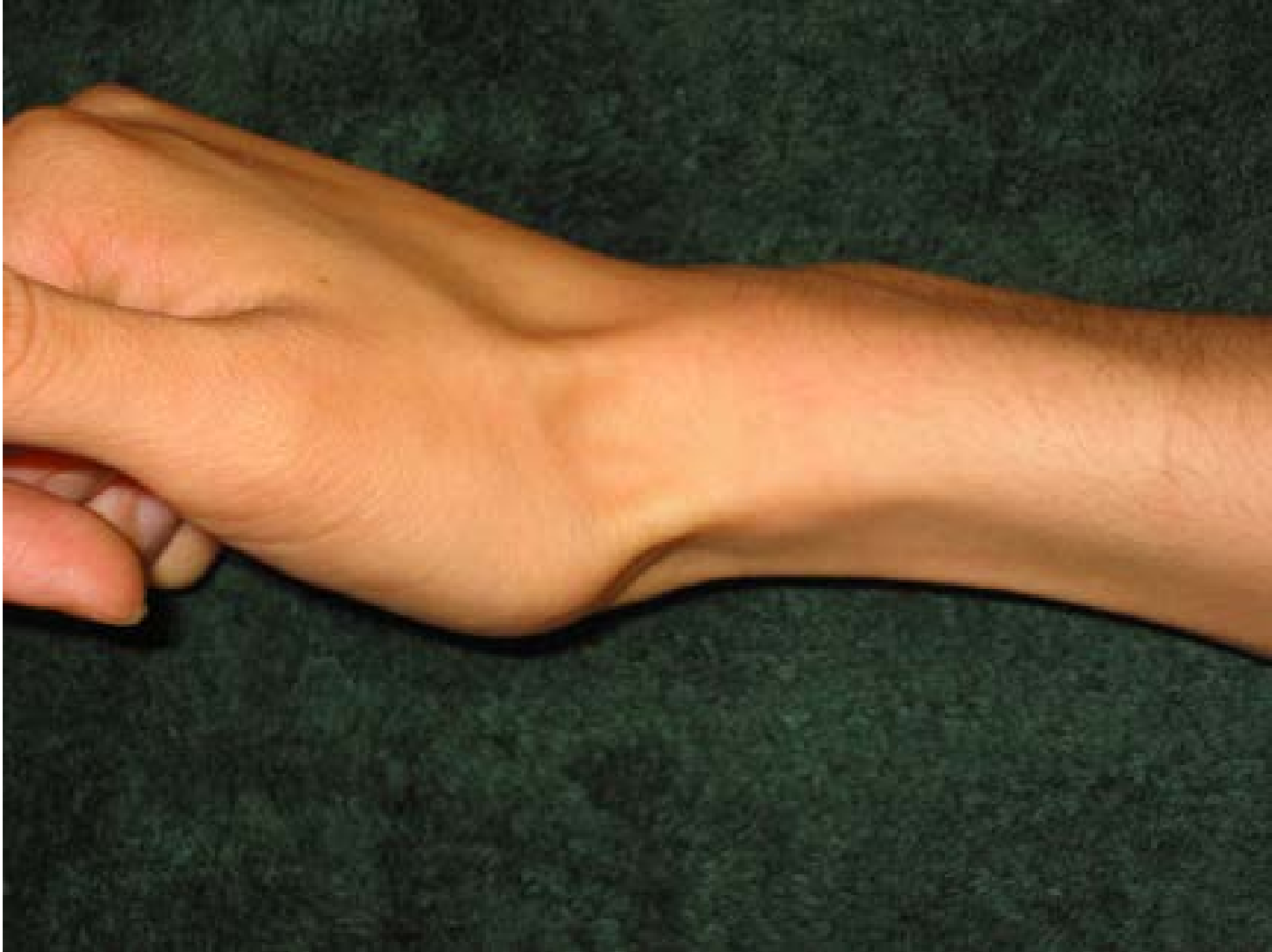- 24 y.o. male fell on outstretched hand (FOOSH) while skateboarding on sidewalk, now has wrist pain

Radial Wrist Pain

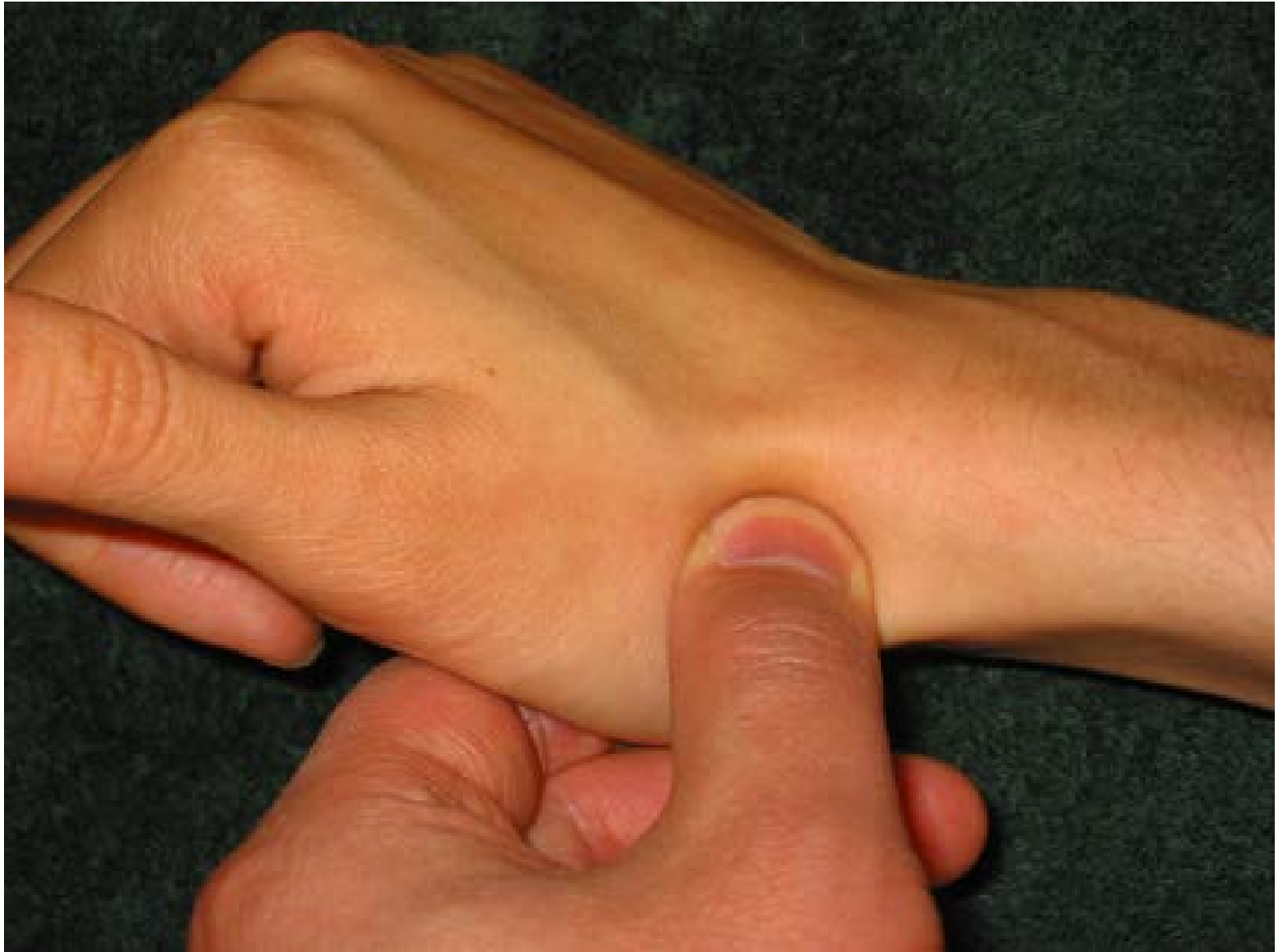Radial Sided Wrist Pain



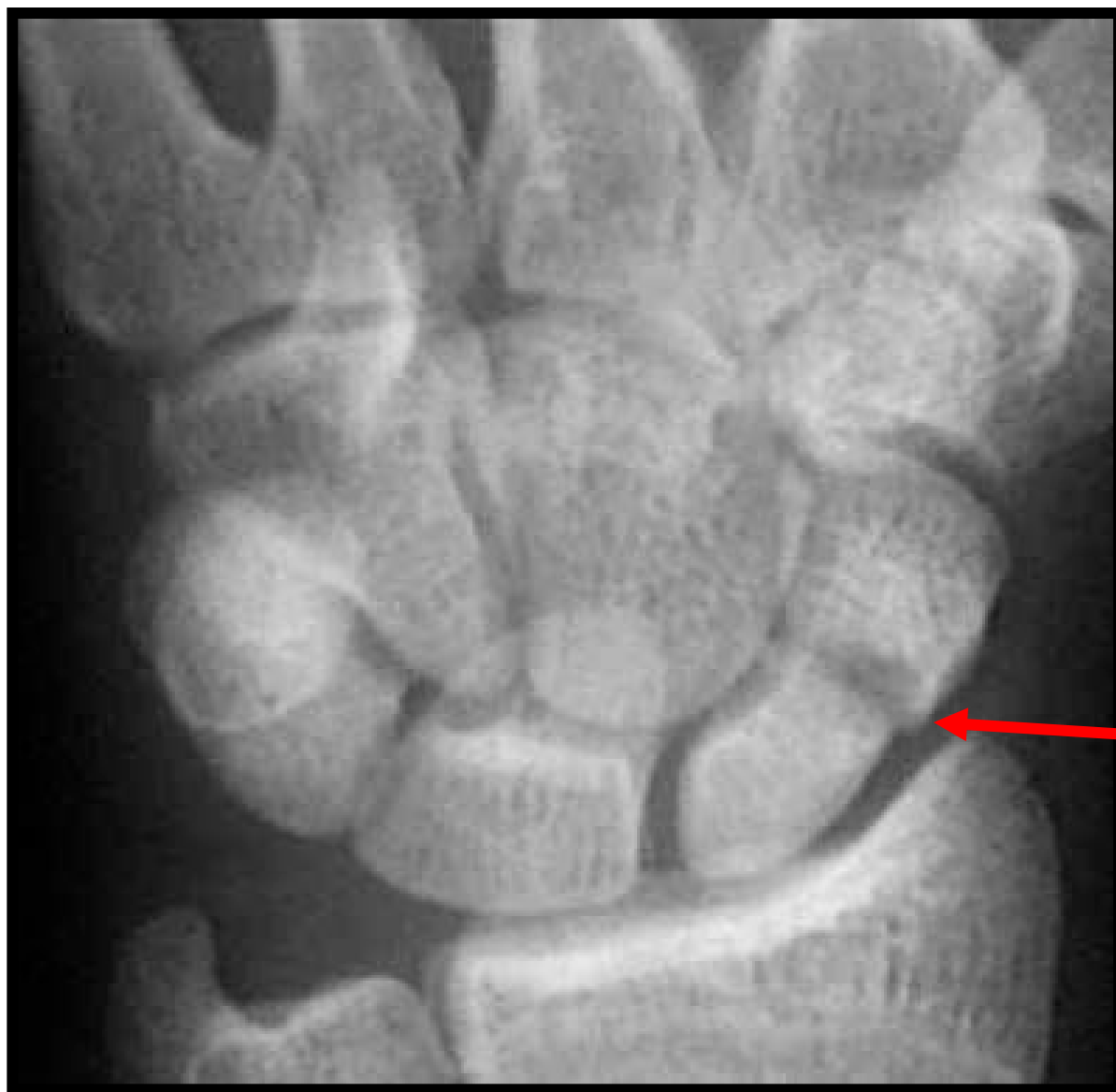
Radial Sided Wrist Pain



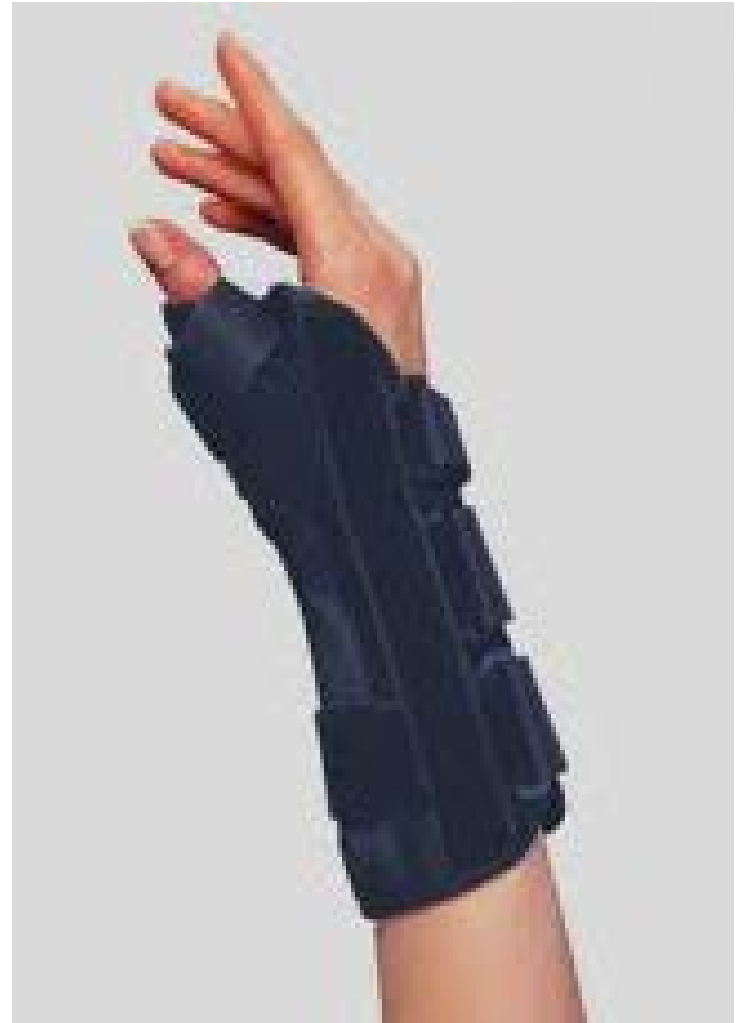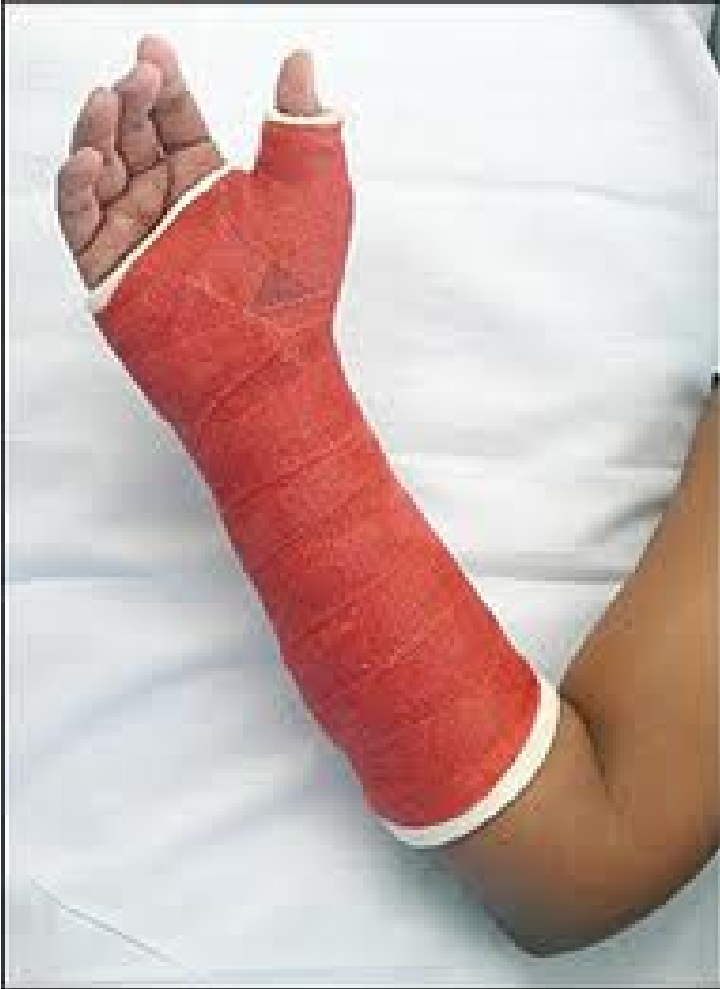Snuffbox Palpation



Scaphoid Fracture



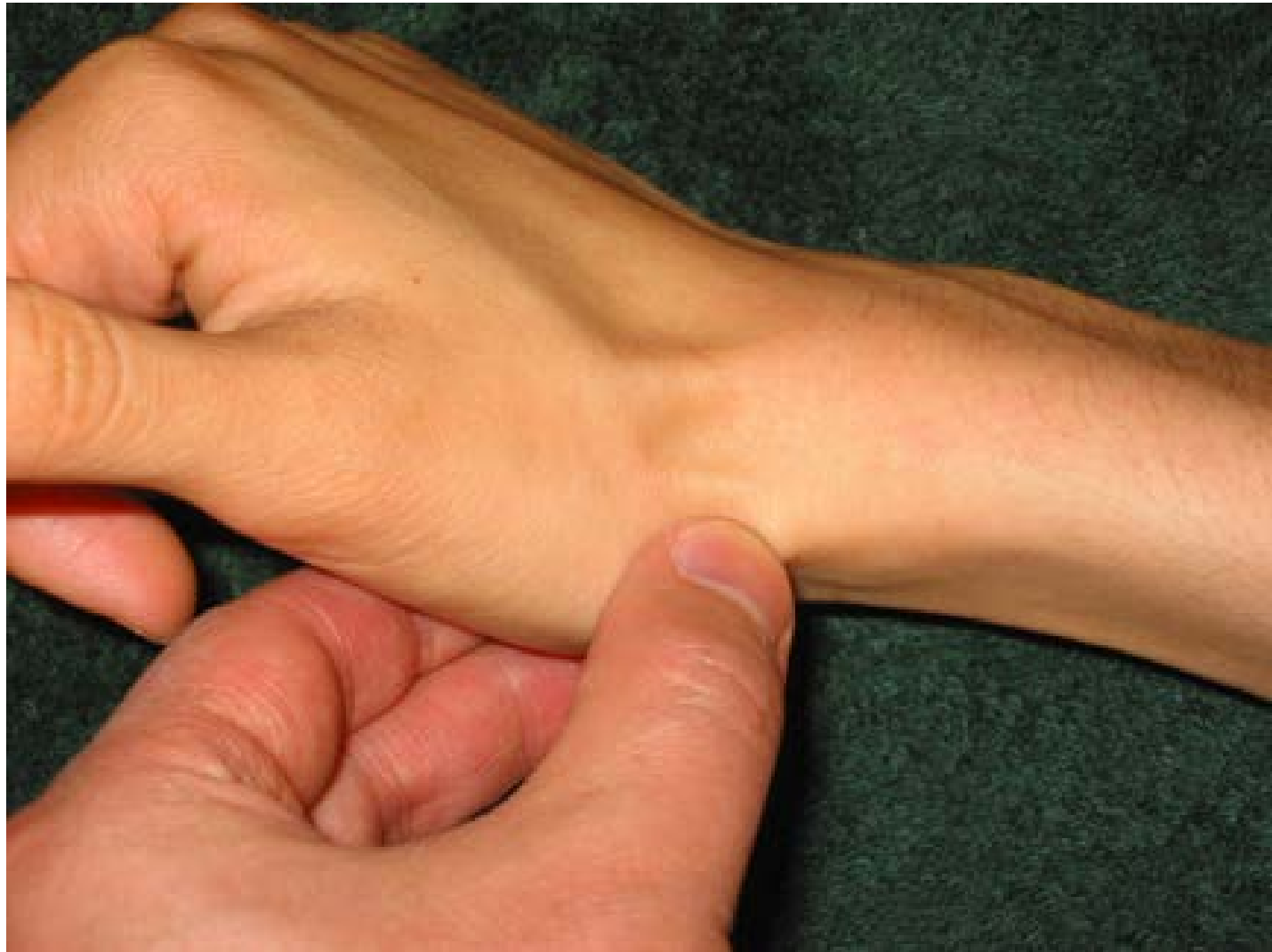Treatment



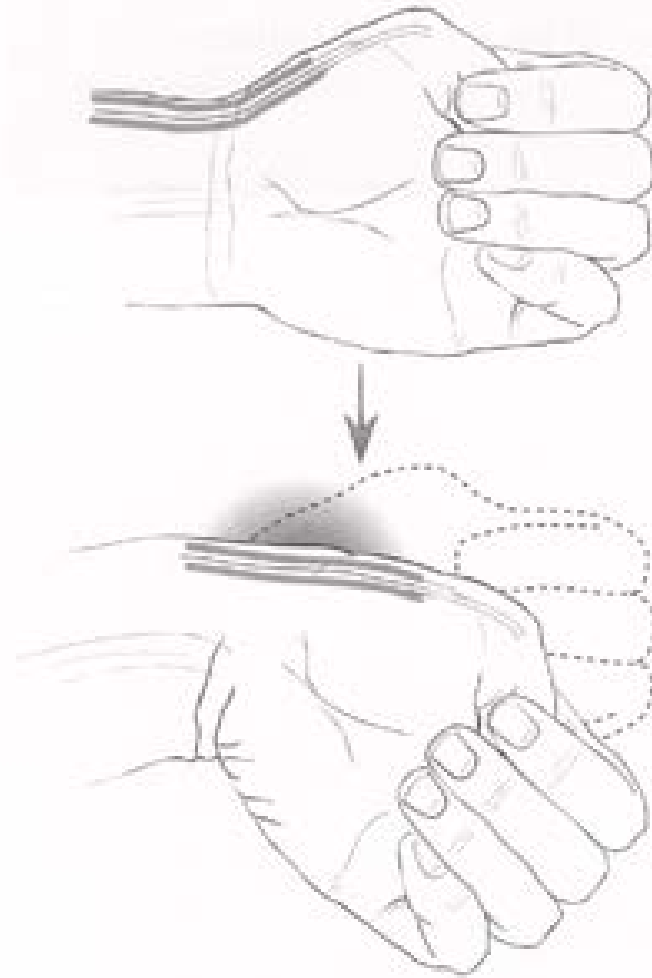
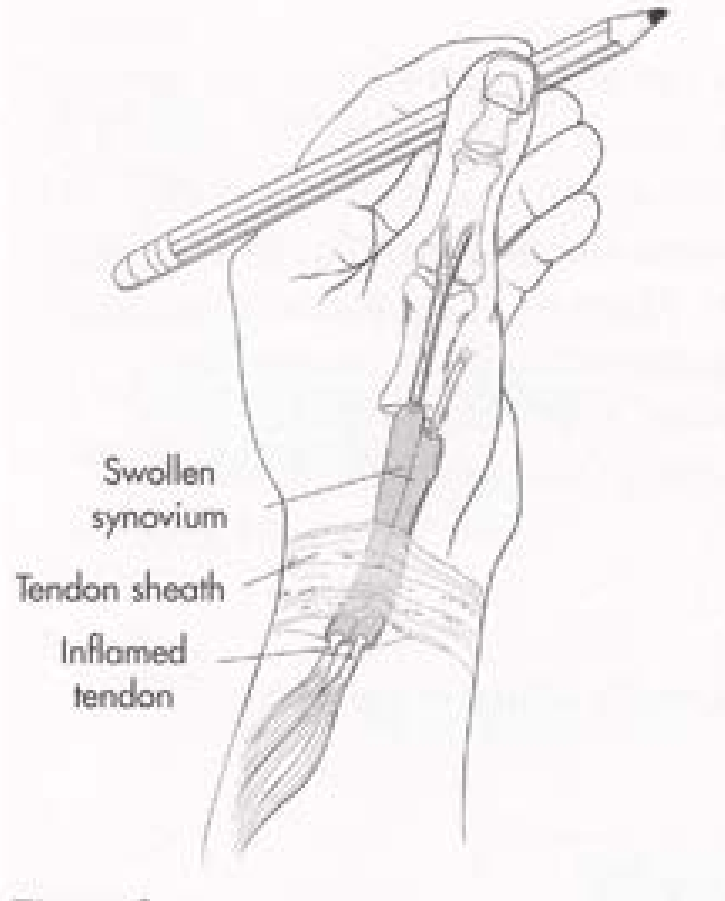
Clinical messages

- Clinician
 - Thumb spica splint/ cast if h/o of FOOSH and snuffbox tenderness
 - Refer to orthopaedic surgeon
- Patient
 - Need to follow up for persistent wrist pain after falls

- 31 y.o. woman who has a 2 month old baby at home c/o right thumb/ wrist pain for the last month
 - Worse with picking up baby

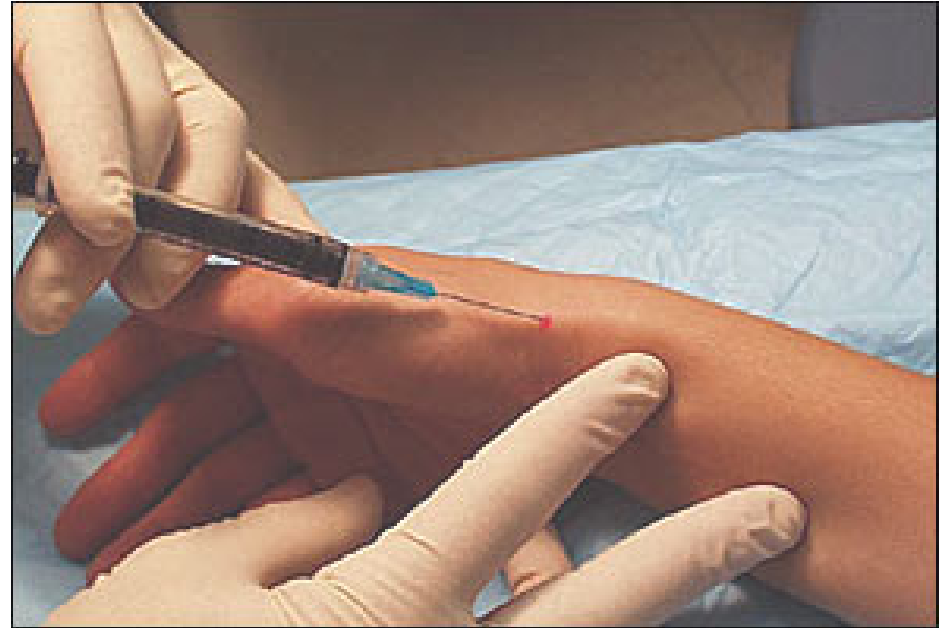
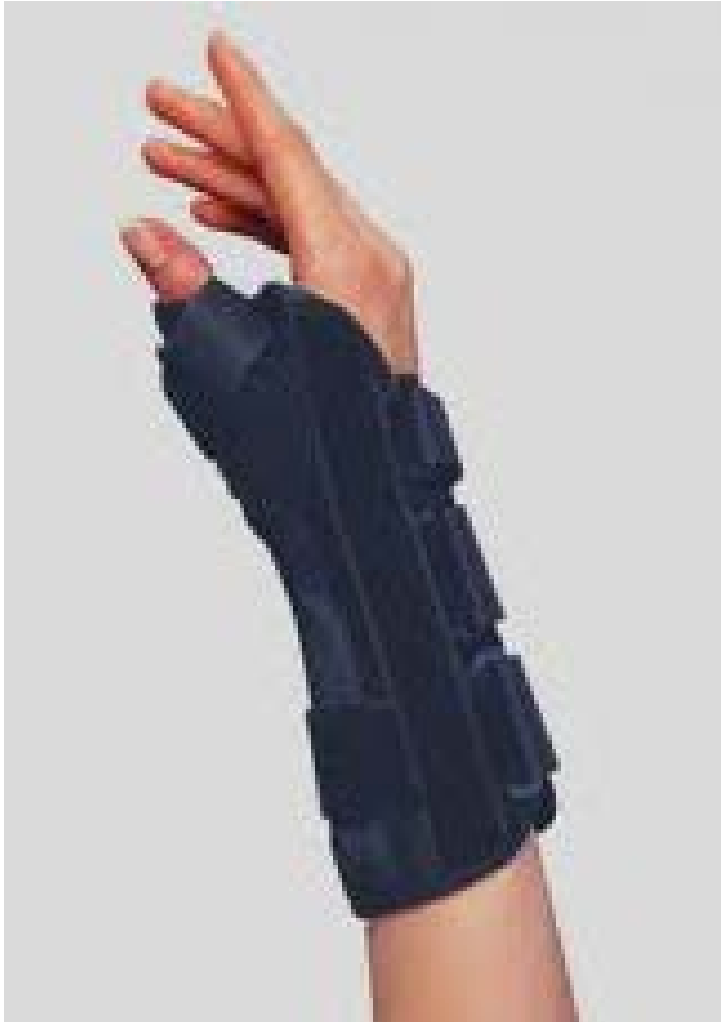
De Quervain's Tenosynovitis



Finkelstein's Exam

Treatment

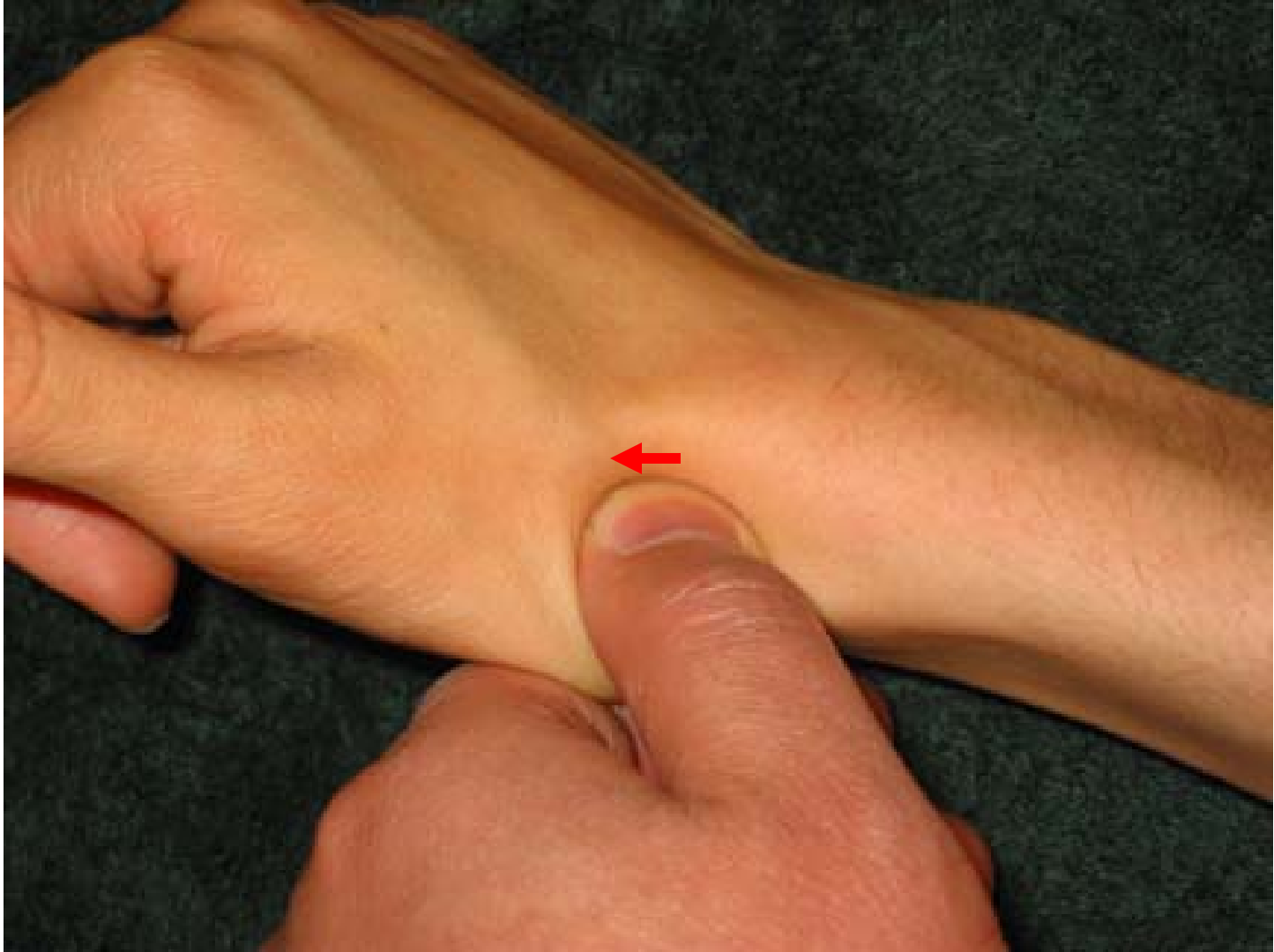

Clinical messages

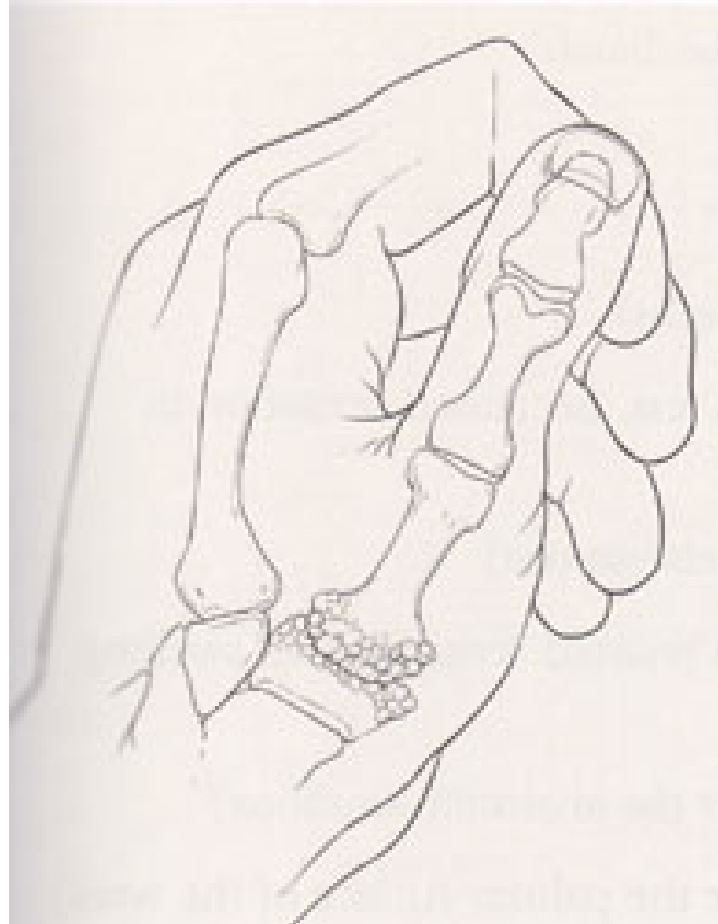- Clinician
 - Thumb spica splint and NSAIDs
 - Steroid injection is 70% effective
- Patient
 - Try not to extend the thumb, especially young mothers

- 67 y.o. woman c/o 1 year h/o of pain in her right wrist area
 - Worse with turning on ignition
 - Worse with twisting open bottle caps

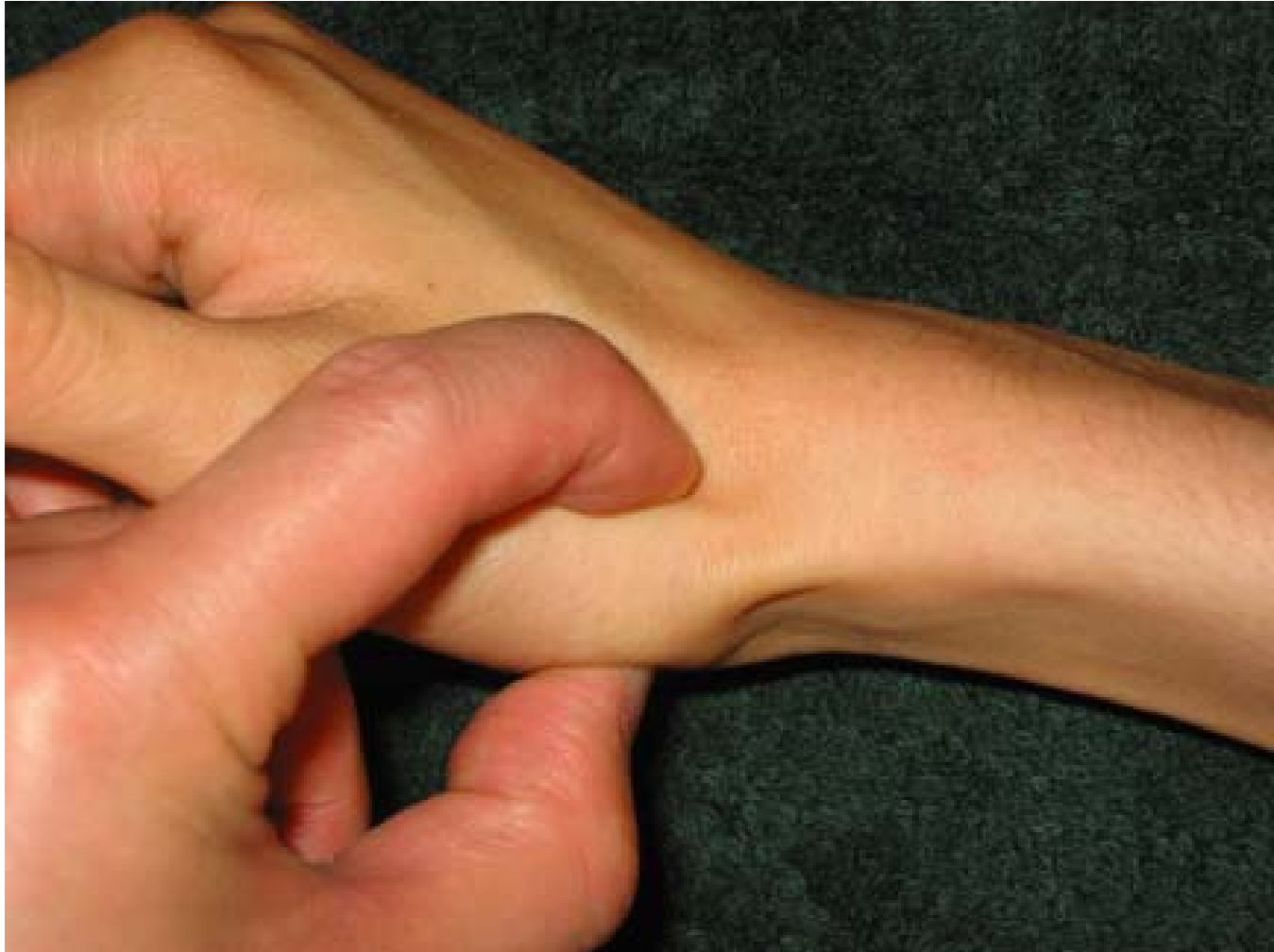Bony Prominence Distal to Snuffbox



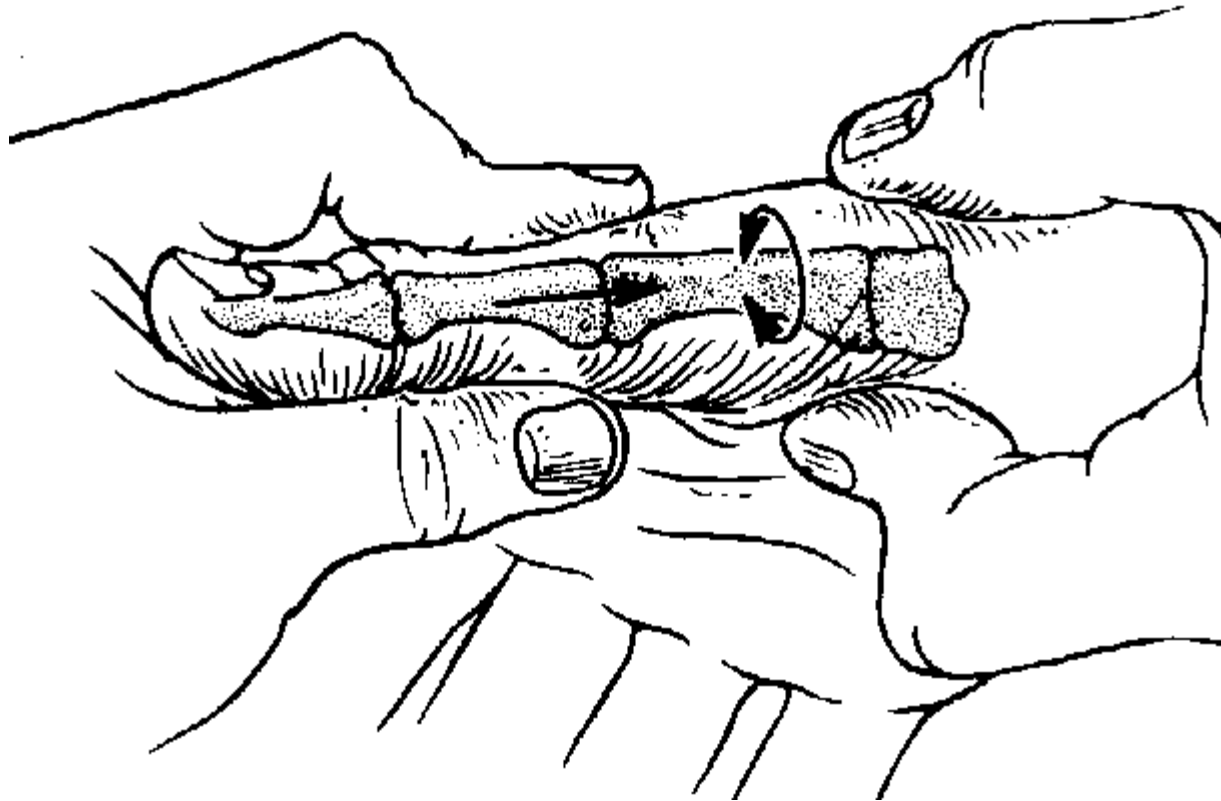
CMC arthritis of the Thumb

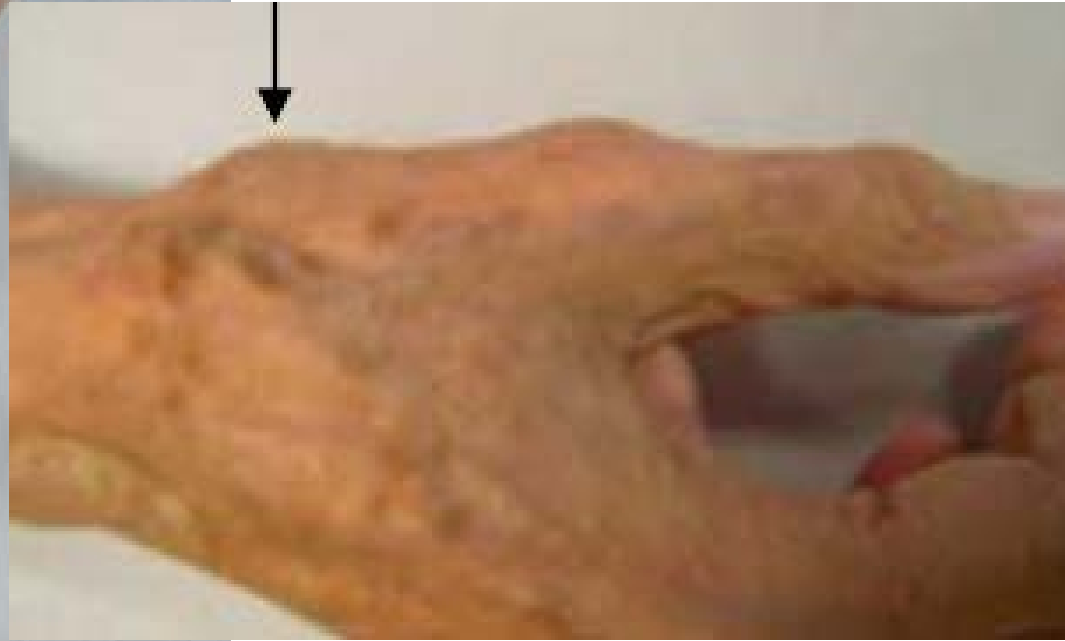
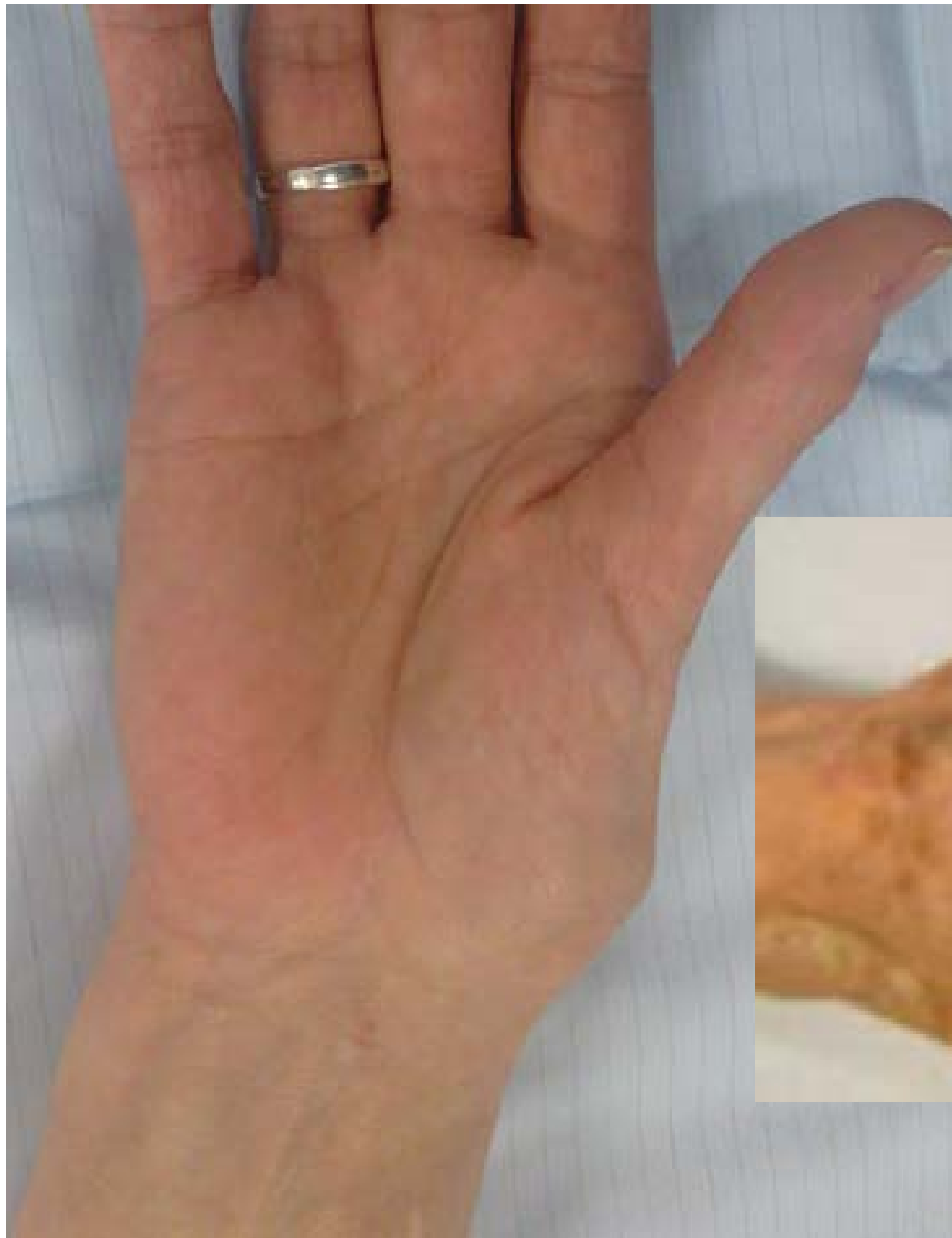

CMC arthritis of the Thumb

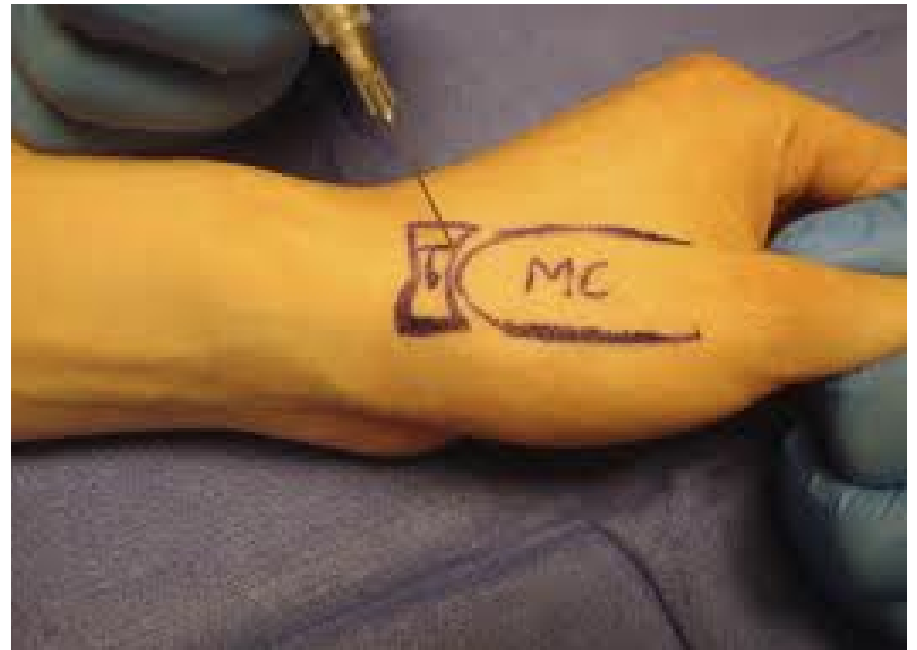
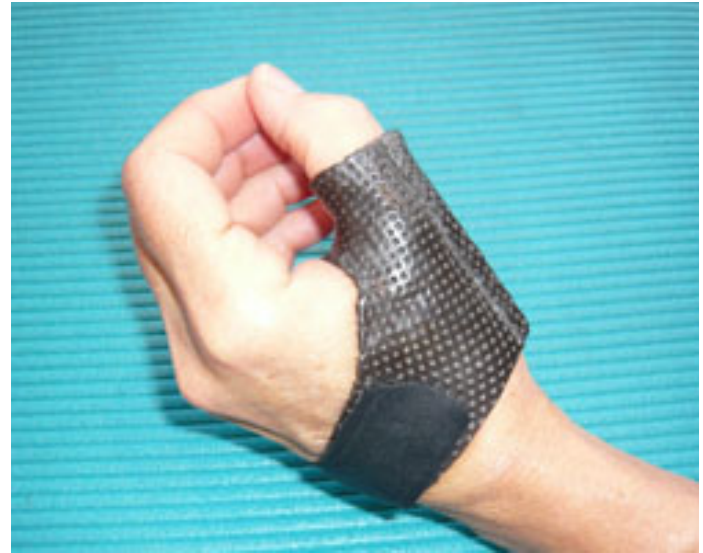
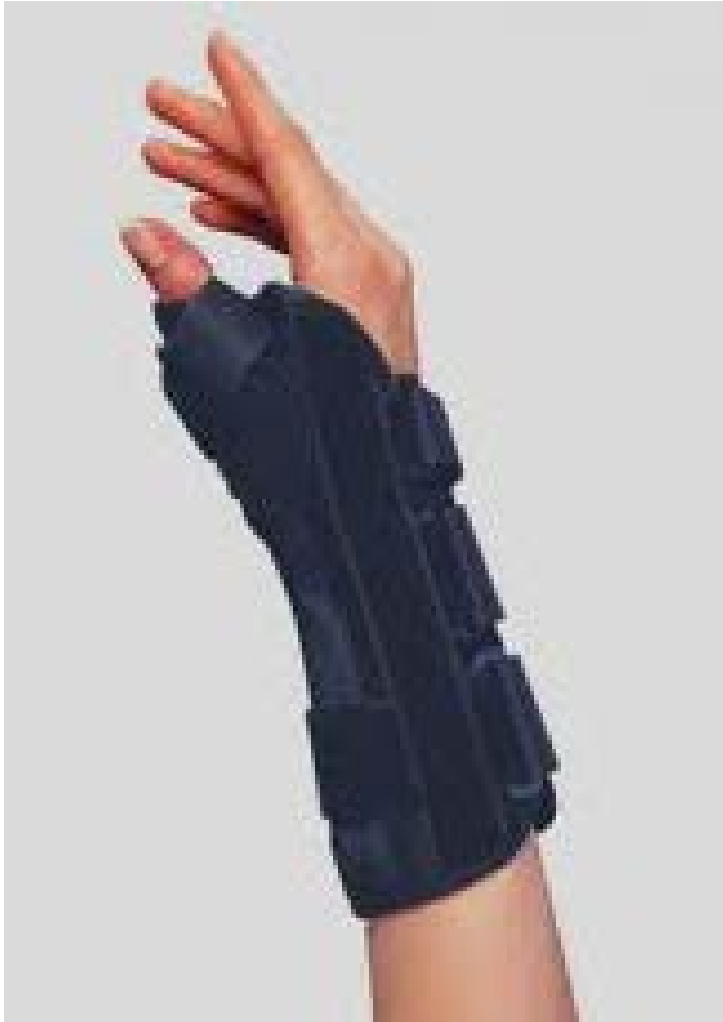CMC arthritis of the Thumb (Grind Test)





Treatment



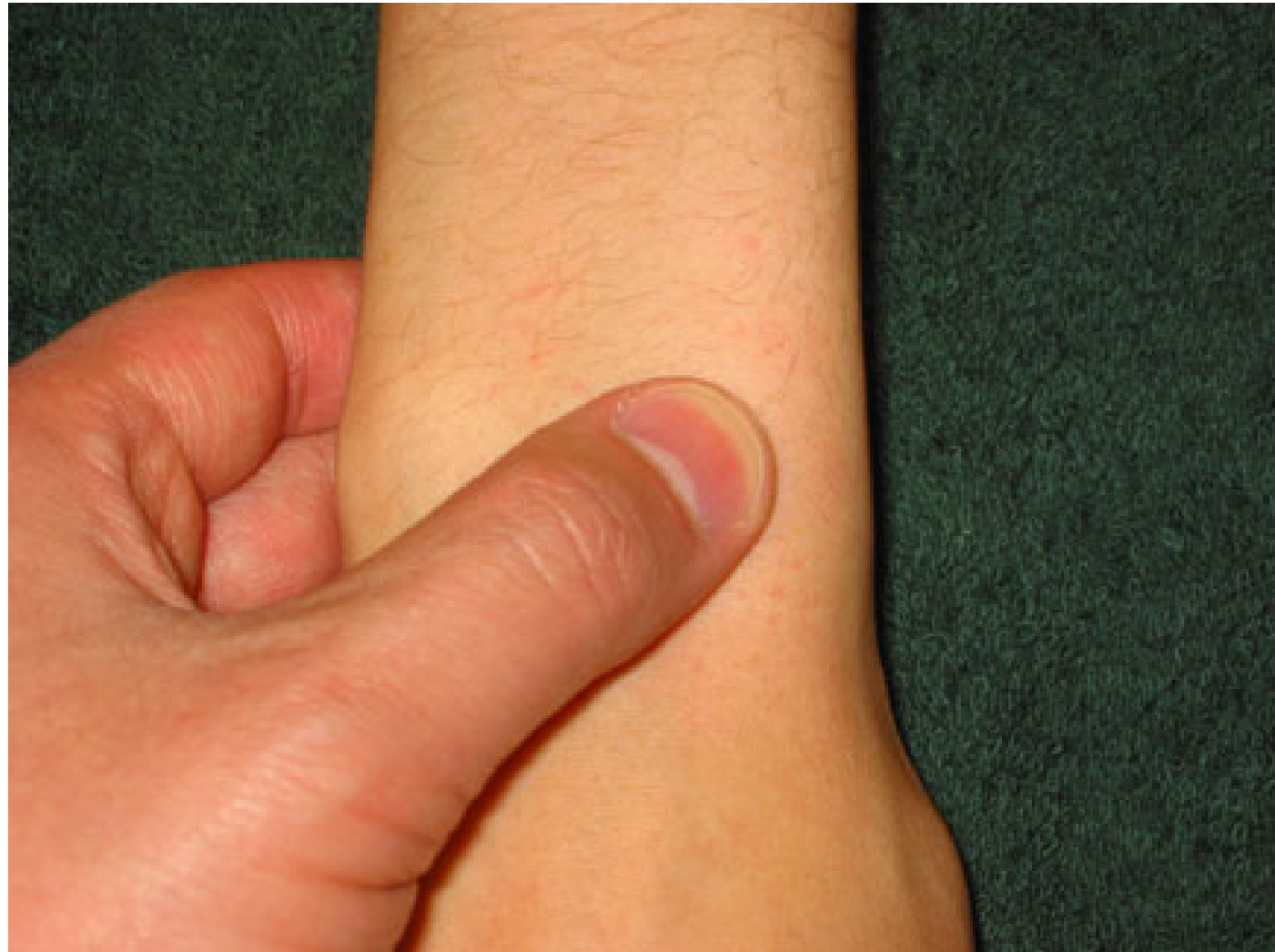Clinical messages

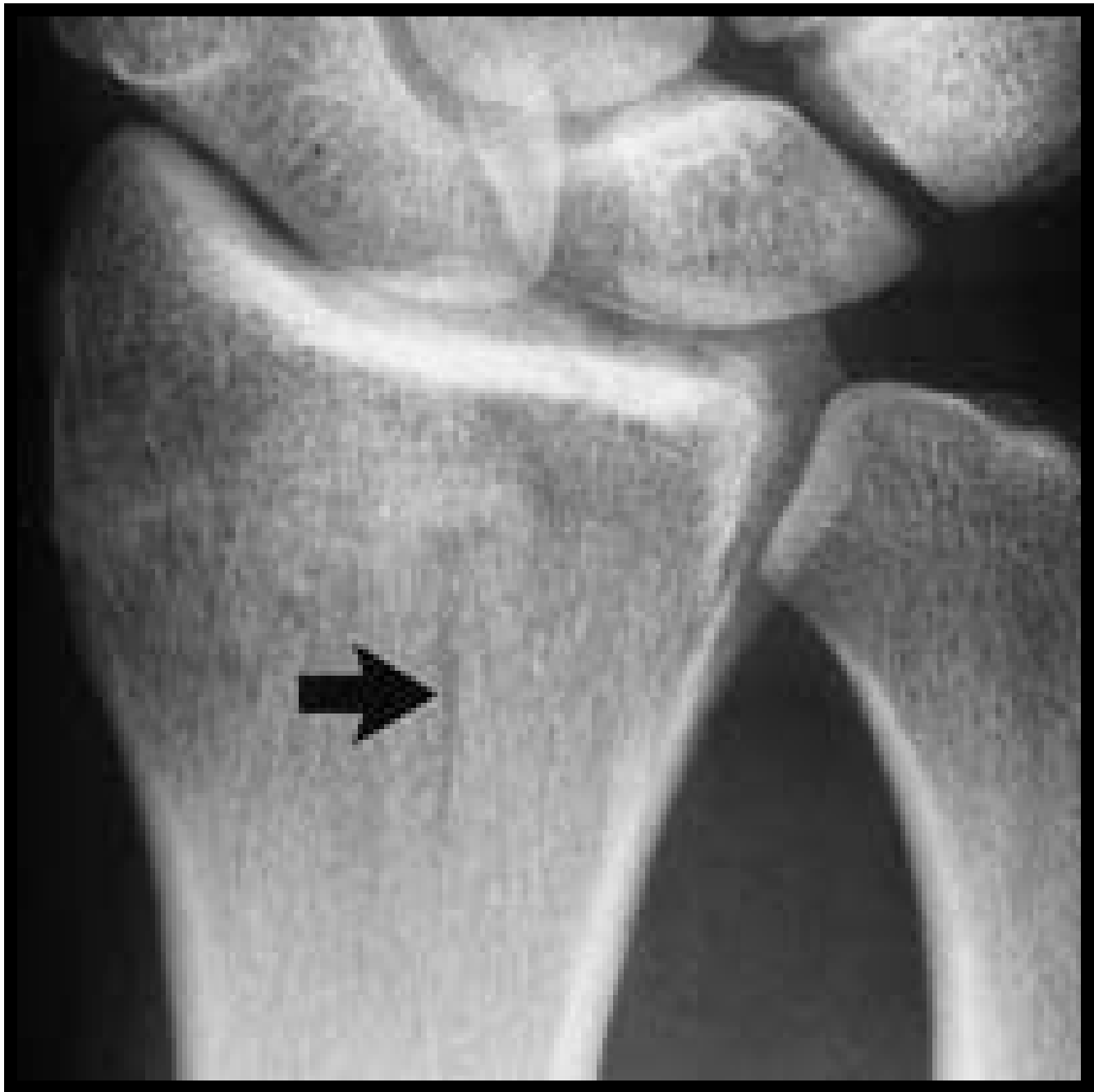- Clinician
 - Thumb spica splint
 - Steroid injections ONLY
40% effective
- Patient
 - Activity modification, ie,
opening bottle caps

- 24 y.o. male fell on outstretched hand (FOOSH) while skateboarding on sidewalk, now has wrist pain

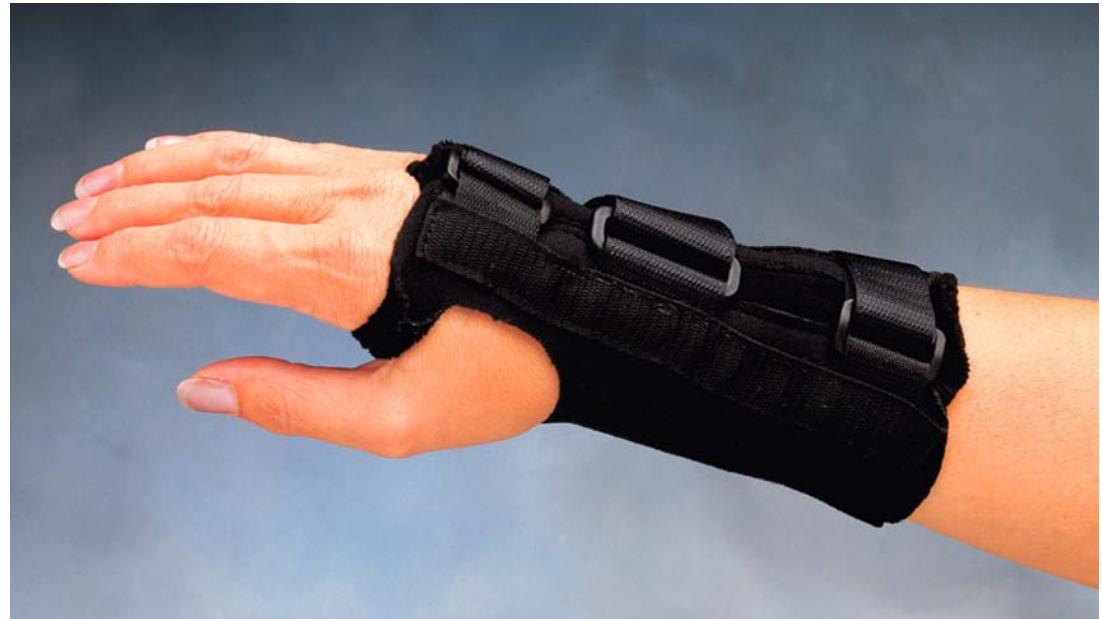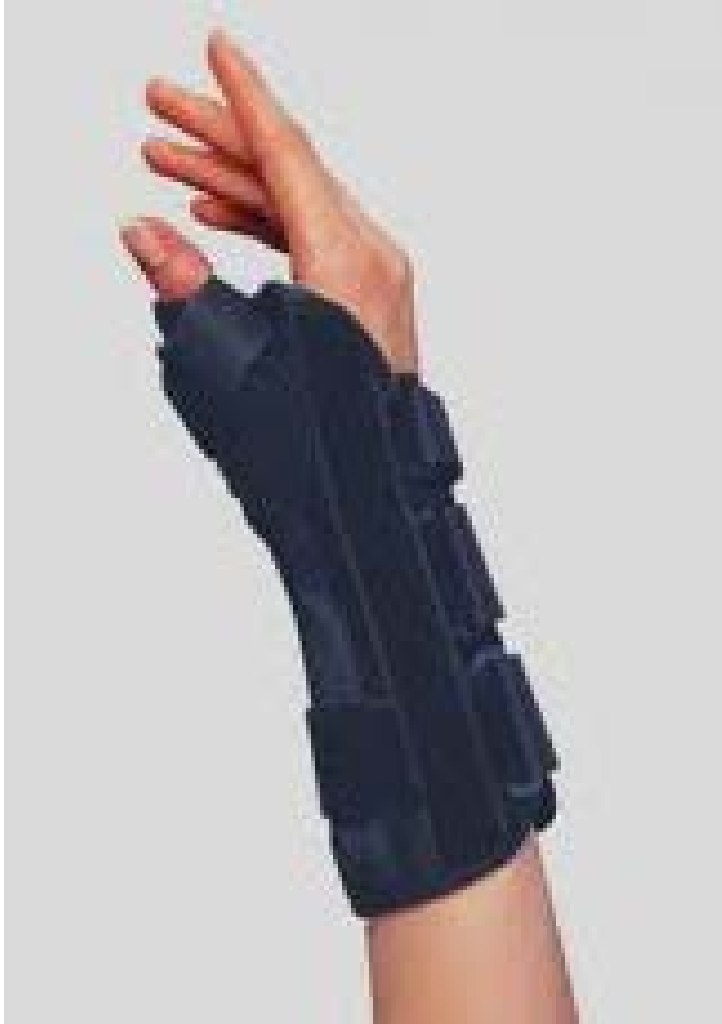Lister's Tubercle

- Distal Radius Fracture



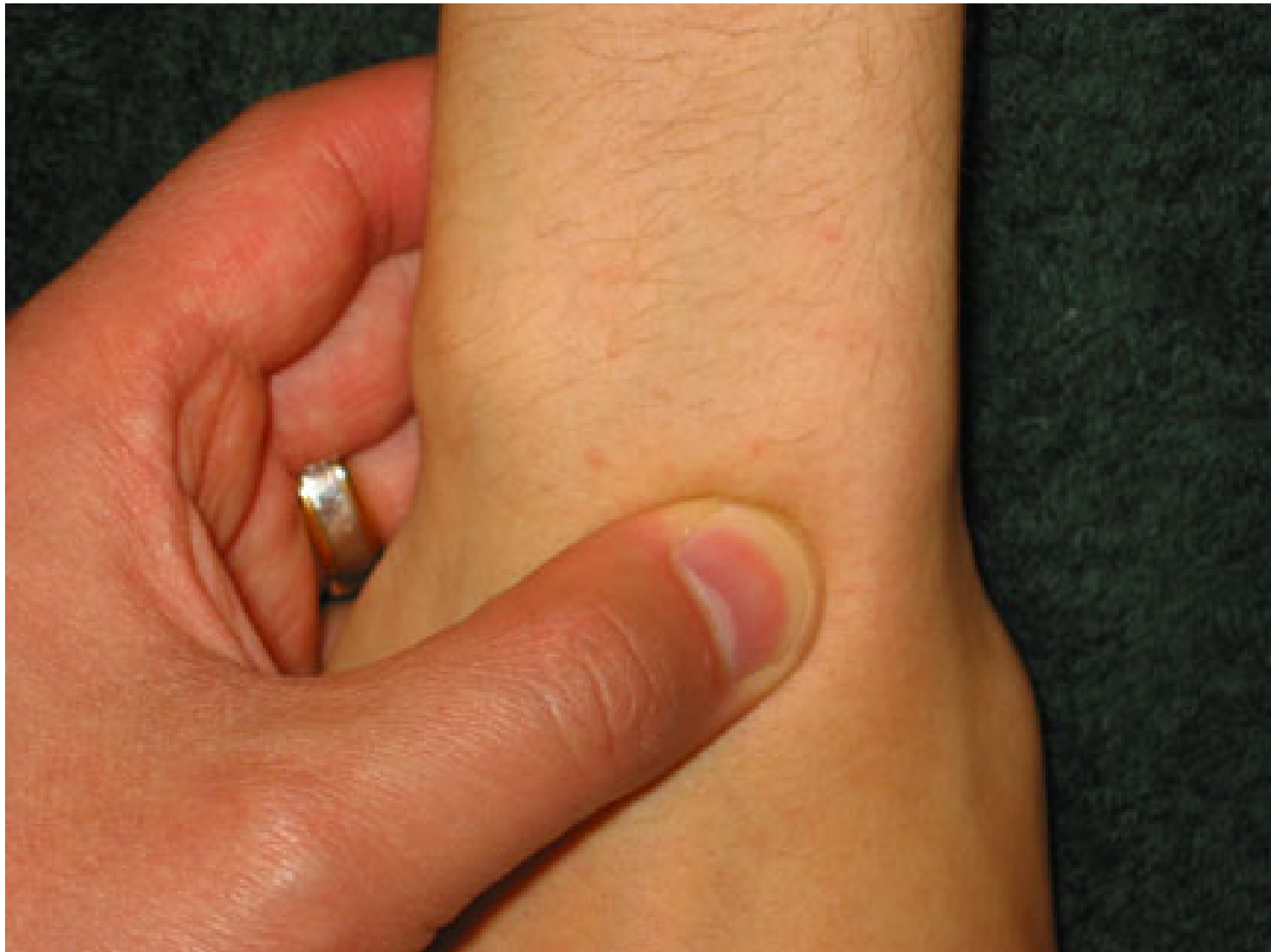

Treatment

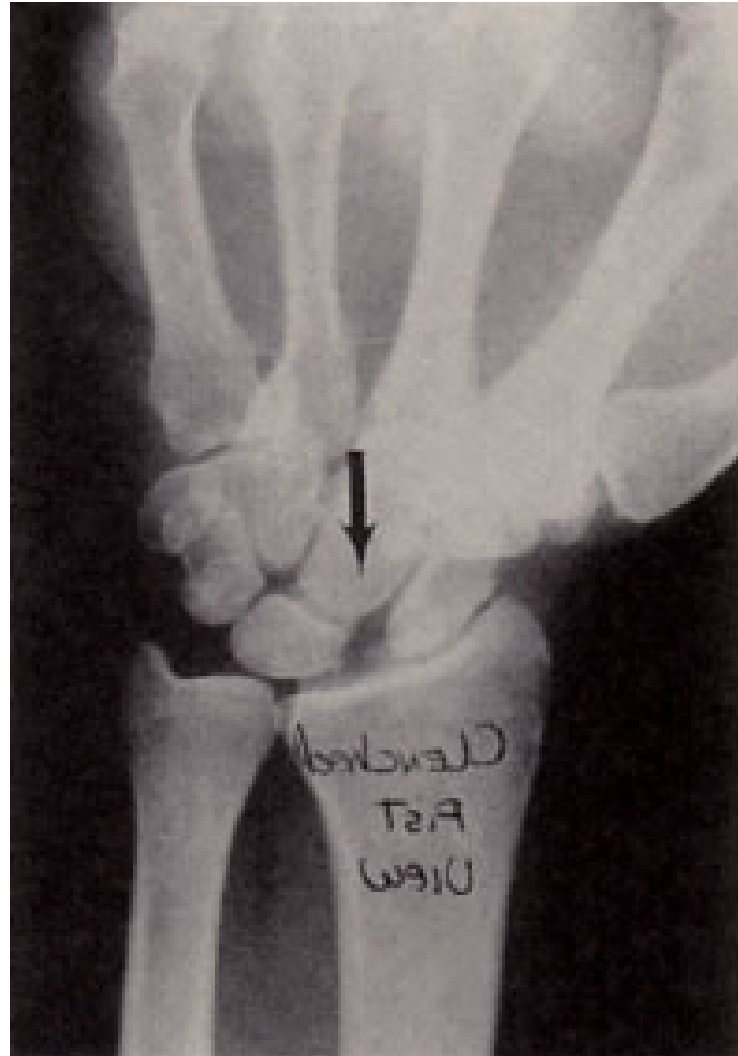

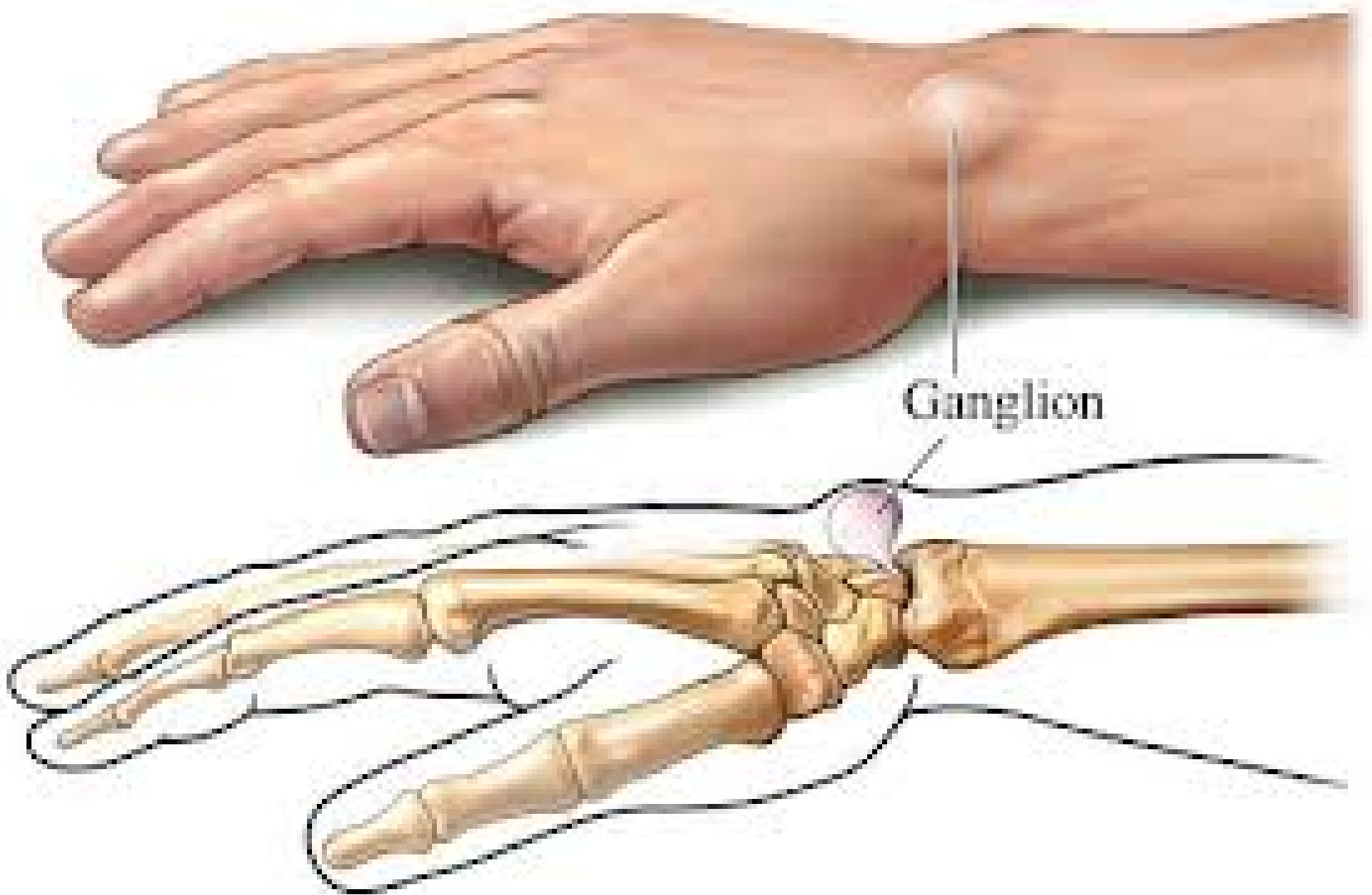
Clinical messages

- Clinician
 - When in doubt, immobilize
 - 30% fractures do not show up on initial xrays
- Patient
 - Be careful when ground is slippery or uneven



Scapholunate Ligament Tear


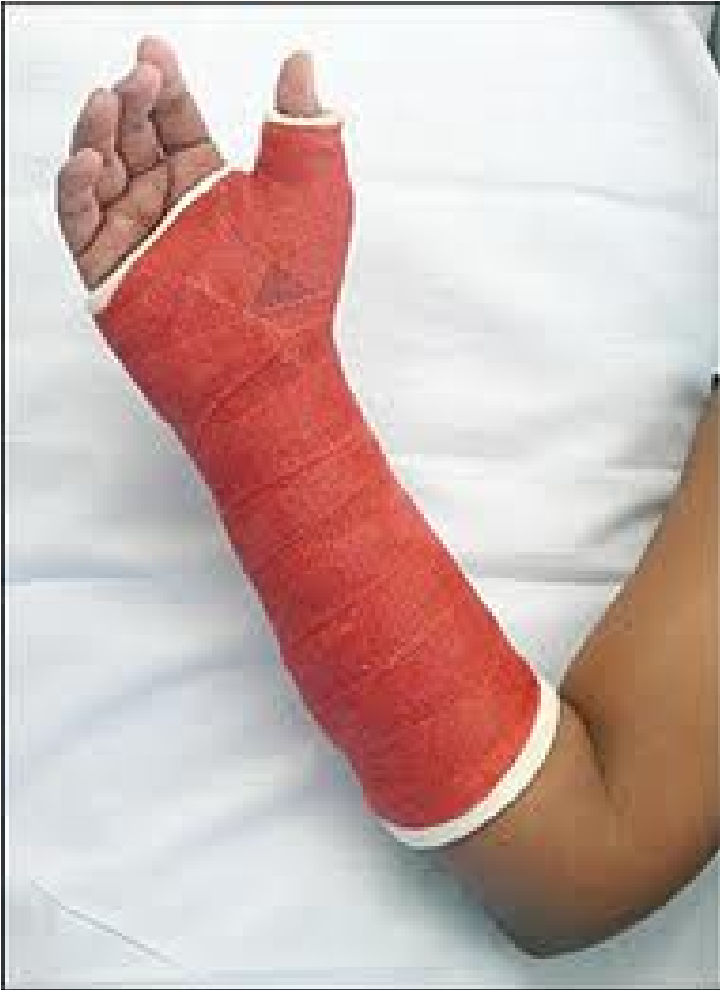


Ganglion

Ganglion

Treatment

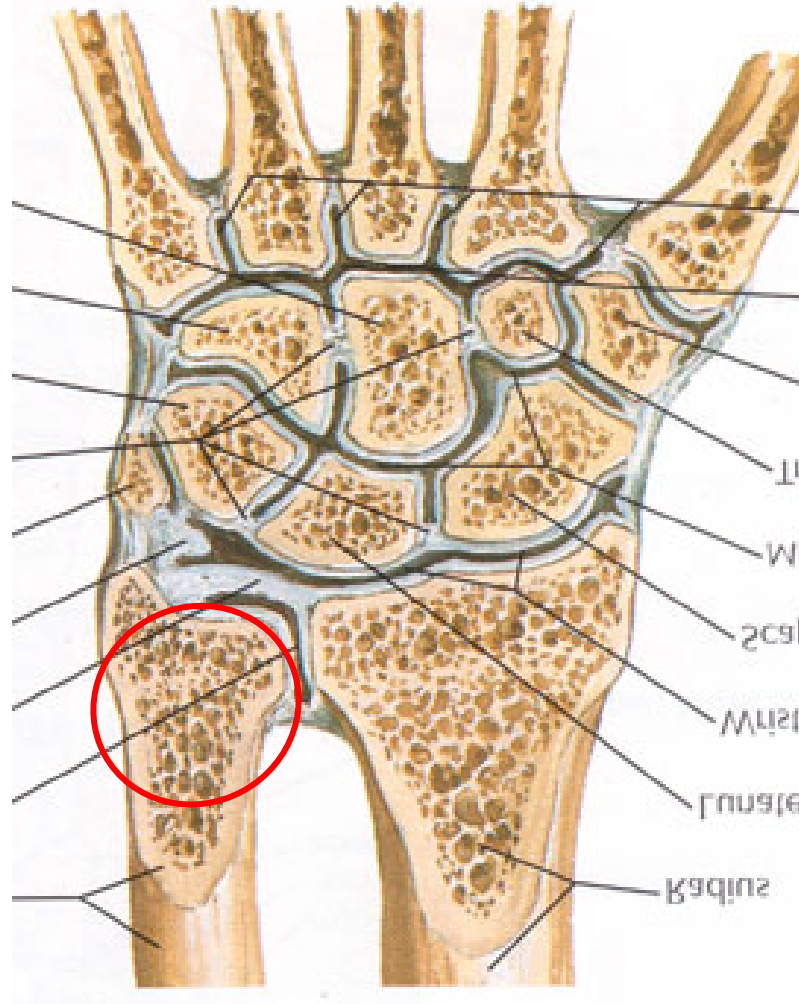


Clinical messages

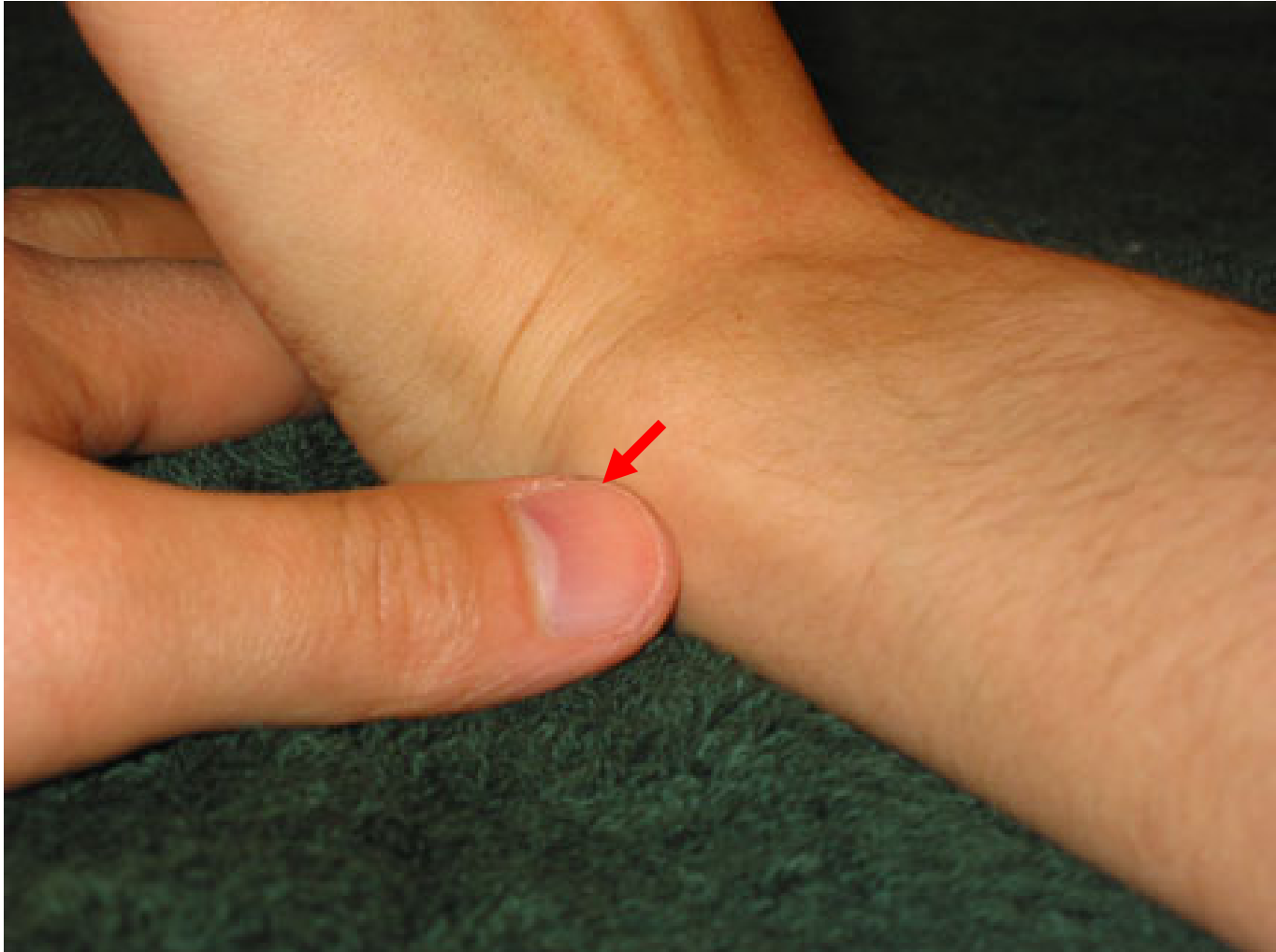
- Clinician
 - Thumb spica splint/ cast if h/o of FOOSH and SL ligament tenderness
 - Refer to orthopaedic surgeon
- Patient
 - Need to follow up for persistent wrist pain after falls

Ulnar Sided Wrist Pain

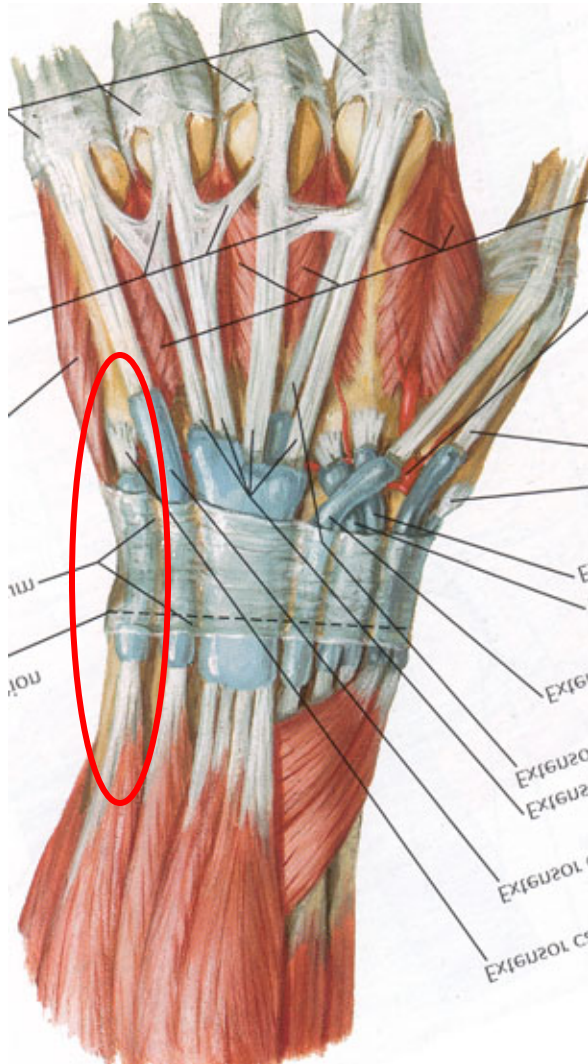
Ulnar Sided Wrist Pain (Distal Ulna Landmark)



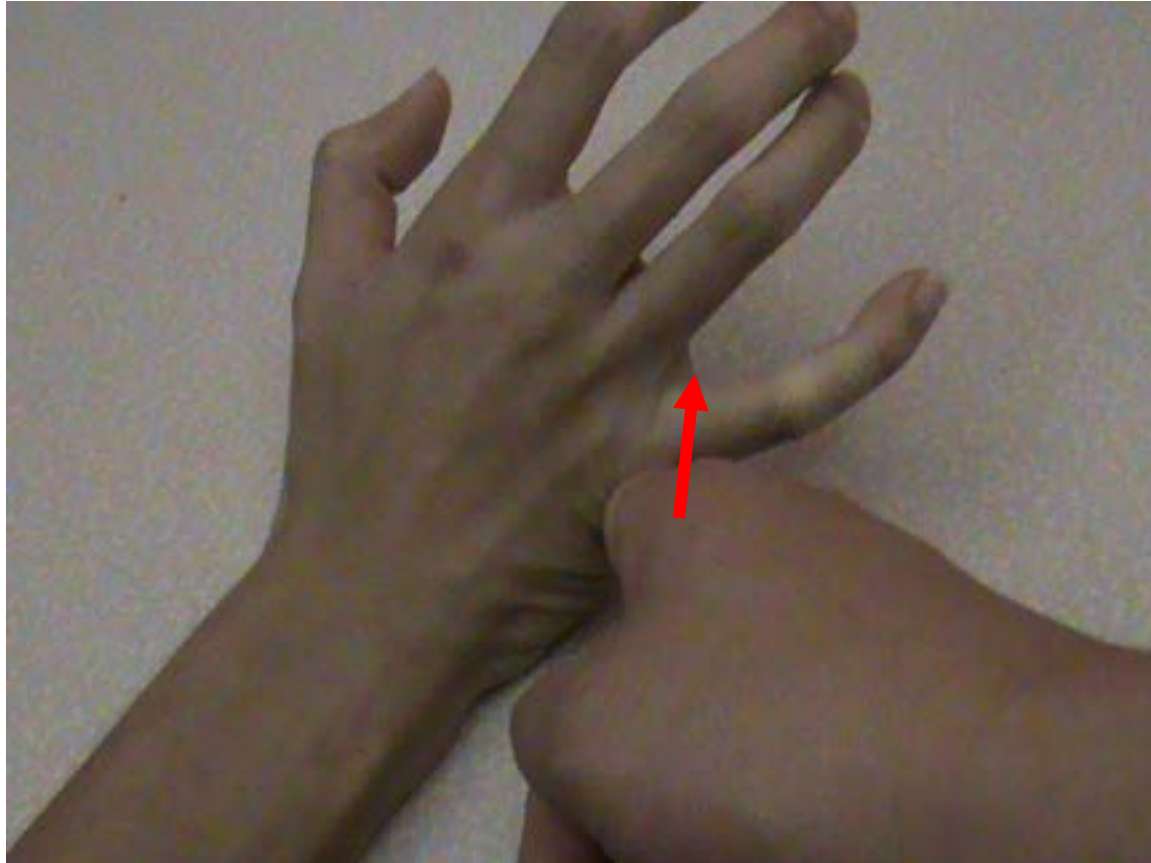
ECU Tendon Palpation



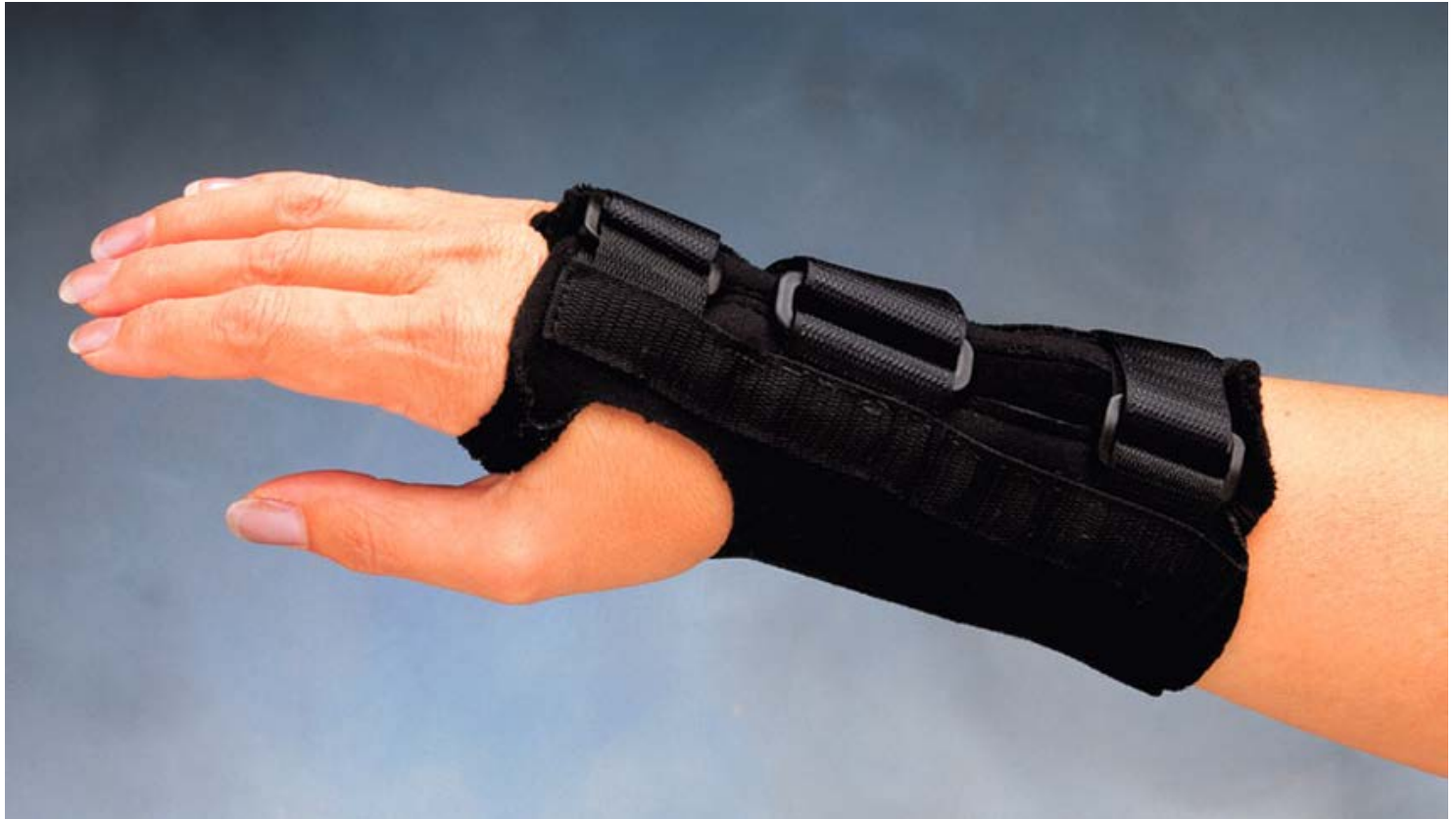ECU Tendonitis



ECU Tendon Resistance Test



Treatment

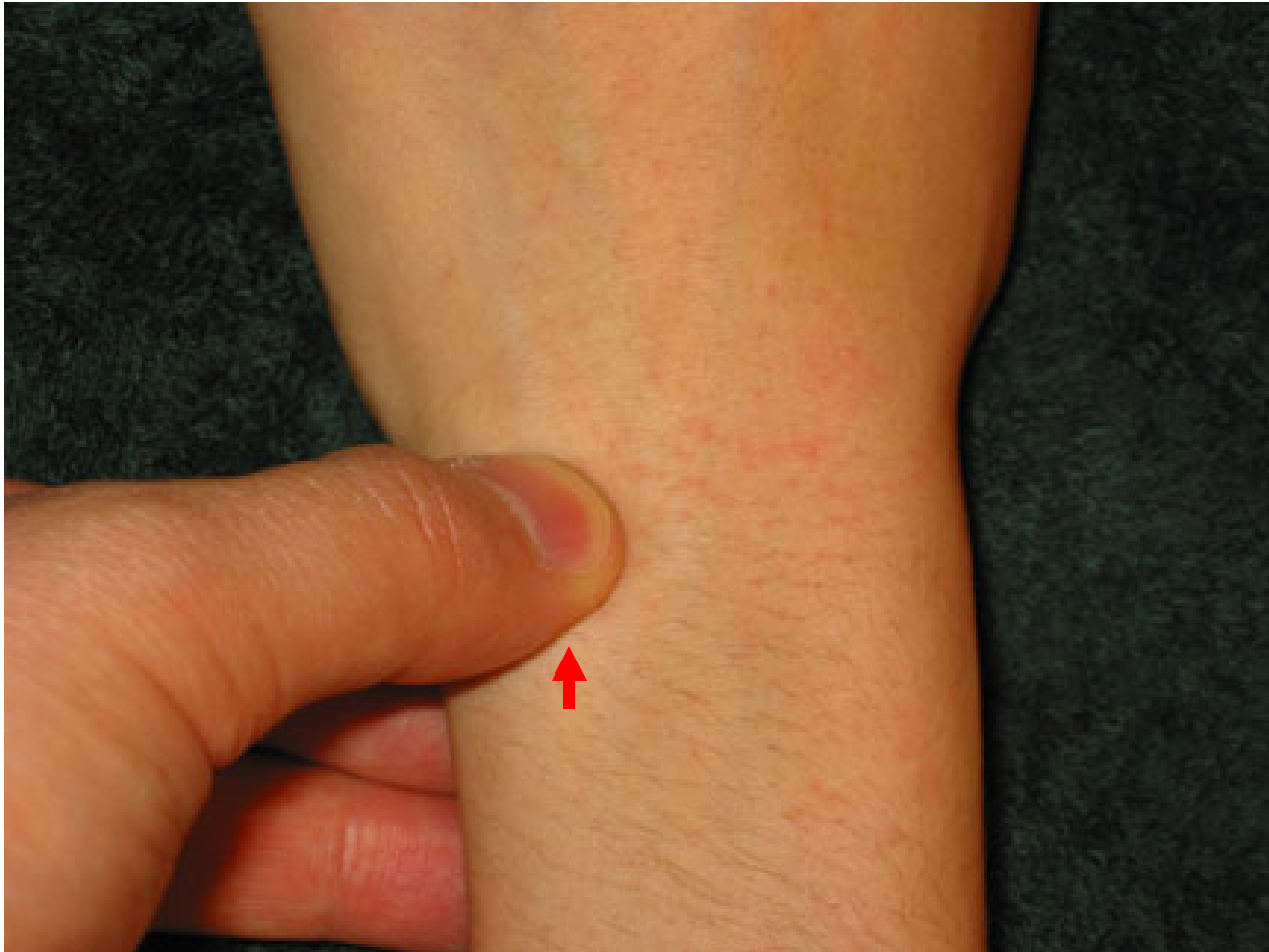

Clinical messages

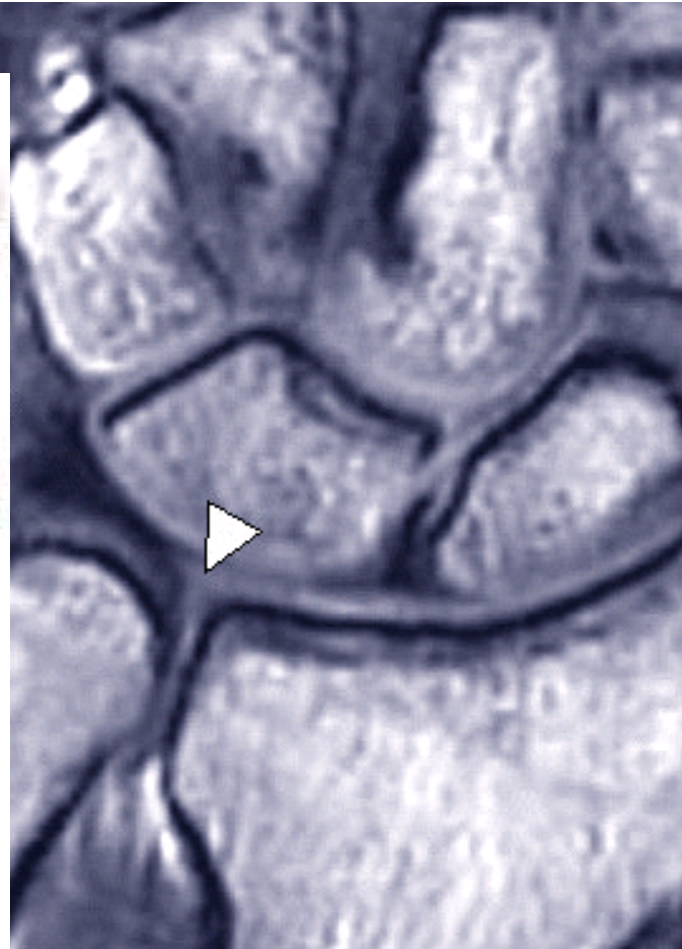
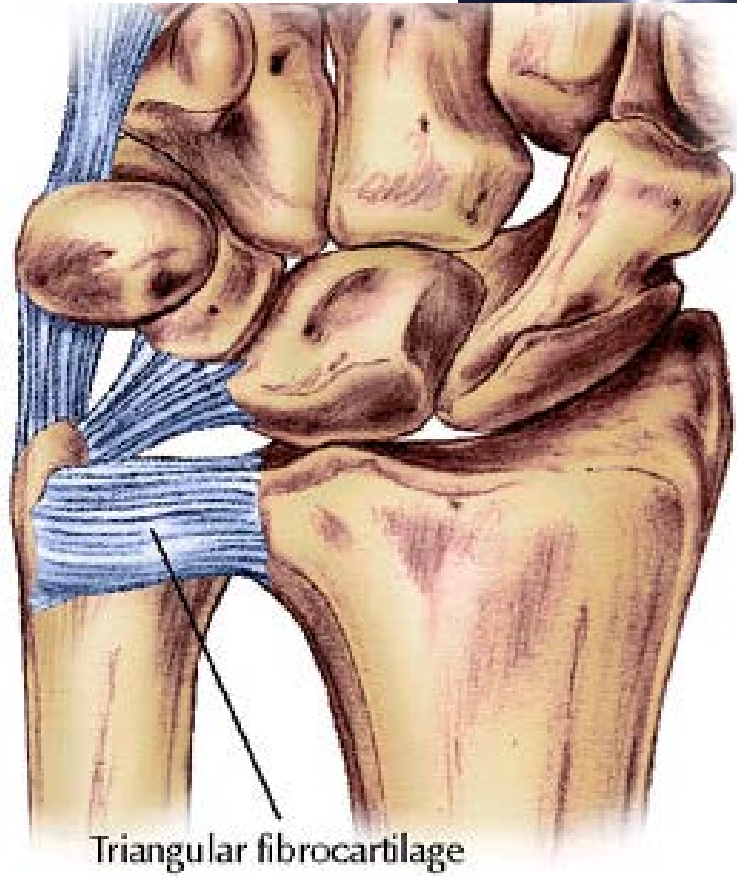
- Clinician
 - Wrist splint and NSAIDs
 - Steroid injection
effectiveness unknown
(risk of tendon ruptures)
- Patient
 - Avoid activities that
aggravate the tendonitis

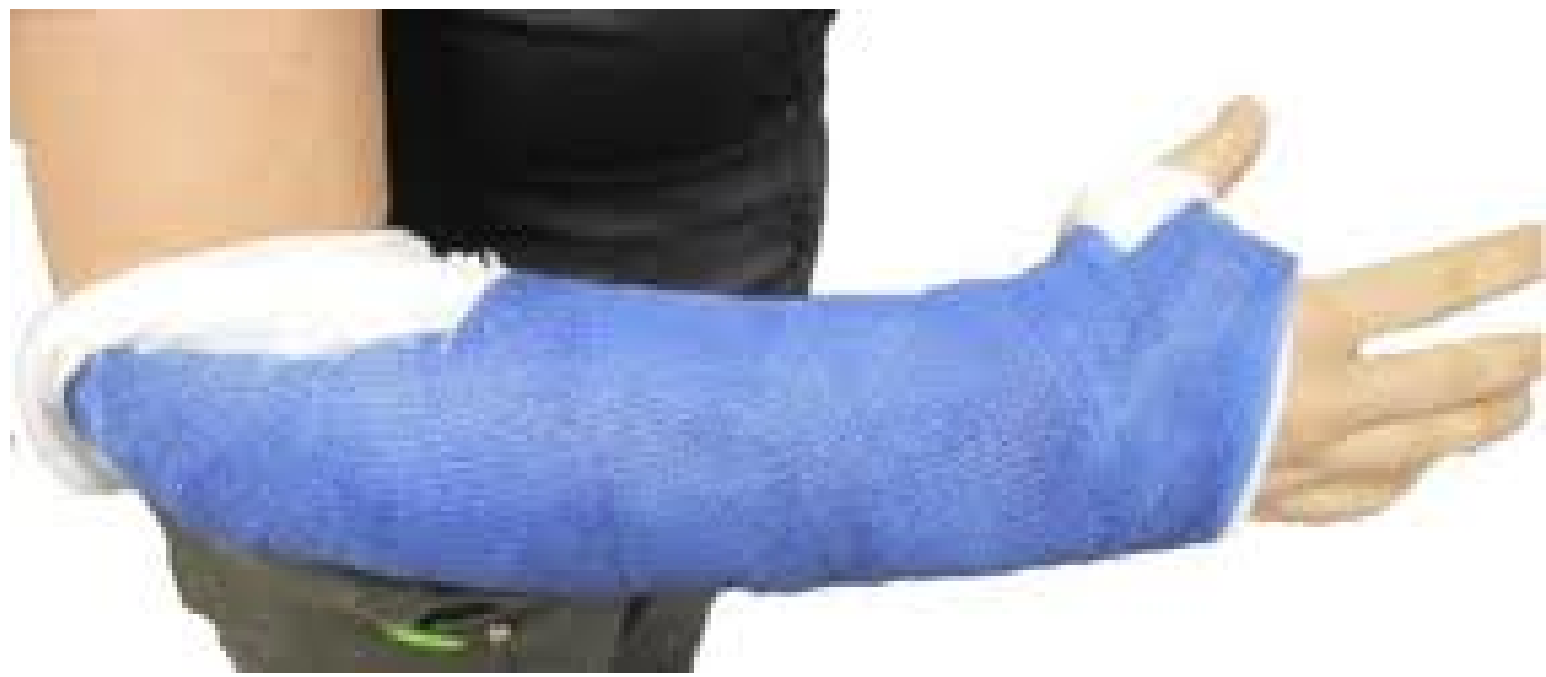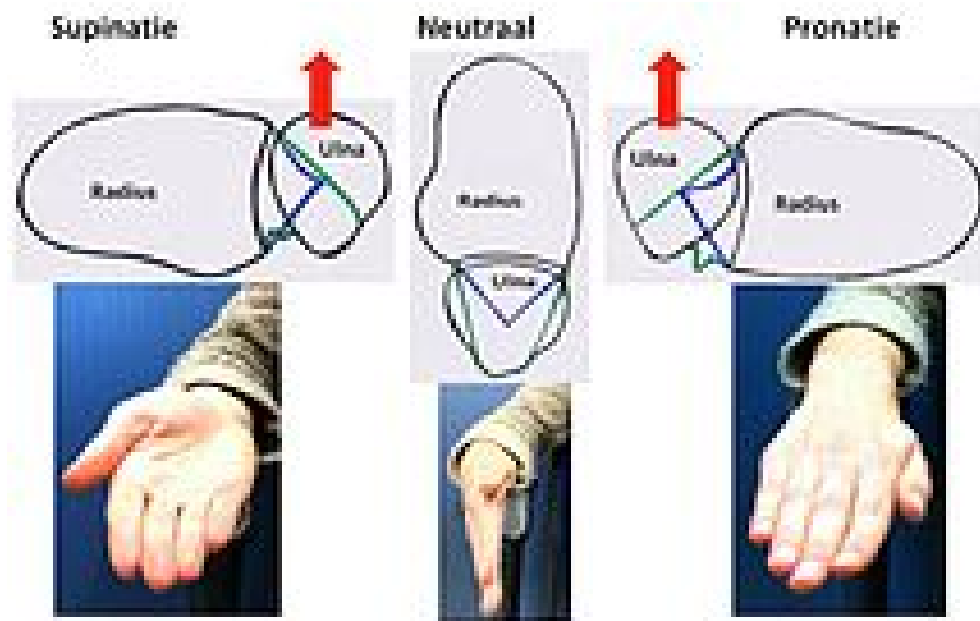
- 24 y.o. male fell on outstretched hand (FOOSH) while skateboarding on sidewalk, now has wrist pain

Triangular FibroCartilage Complex (TFCC) Injury



TFCC Schematic





P.E. & D.Dx. Summary

- **P.E. for**
 - MC/ Phalanx Fx
 - Trigger Finger
 - FDS/ FDP Injuries
 - Carpal Tunnel Syndrome
 - Scaphoid Injury
 - CMC arthritis of the Thumb
 - DeQuervain's Tendonitis
 - Scapho-Lunate Injury
 - TFCC Injury



Beth Israel Deaconess
Medical Center



Harvard
Medical School

Questions ?

Charles S. Day, MD, MBA
cday1@bidmc.harvard.edu